



PATIENT

Grayson Overly

SPECIES

Feline

BREED

DSH

SEX

Neutered Male

AGE

4 Years

WEIGHT

12.08 lbs

INTERPRETED BY

Eric Lindquist, DMV,
DABVP(CFM), Cert.
IVUSS

IMAGING PERFORMED BY

Dr. Renee Zeigler-Post

HOSPITAL NAME

For Cats Only
Veterinary Clinic

REFERRING VET

Dr. Renee Zeigler-Post

INVOICE

16346

DATE

05/18/26

PRESENTING CLINICAL SIGNS

Recheck after starting Felycin. Blood pressures- #3 RH- 155/89, 158/70, 160/85, 154/90

RX- Felycin, allergy immunotherapy vaccine, Cerenia, Mometavet, Clopidogrel

ULTRASONOGRAPHIC EXAMINATION OF THE HEART

FELINE CARDIAC PARAMETERS	BODY WEIGHT (lbs)	HR (BPM)	IVSd (cm)	LVIDd (cm)	LVWd (cm)	FS (%)	EF (%)
NORMAL PARAMETER	-----	150-240	0.3-0.6	1.0-2.1	0.25-0.6	35-67	80-100
PATIENT	12.08	~140	0.65	1.65	0.65	31	63
FELINE CARDIAC PARAMETERS	LA/AO (M-mode)	LA/AO HEART BASE (Sisson)	LAD LA MAX 4 Chamber		LVOT VEL. (m/s)	RVOT VEL. (m/s)	IVRT (m/)
NORMAL PARAMETER	<1.5	1.6	0.7-1.7		<1.6	<1.3	40-60
PATIENT	1.2	1.3	1.62		--	--	NM
Adapted from June Boon, Veterinary Echocardiography, 1998 Sisson D et al. JVIM 1991; 5: 232, Jacobs et al. Am J Vet Res 1985; 46:1705							

Cardiac Presentation

The cardiac presentation presented with normal left atrial, left ventricular, right atrial, right ventricular, sizes. Mild left ventricular hypertrophy was noted in this patient. Heart rate was variable. No evidence of volume overload was noted.

ULTRASONOGRAPHIC FINDINGS

- Minor left ventricular hypertrophy- stable.
- HCM phenotype- not clinically an issue at this time.

INTERPRETATION OF THE FINDINGS & FURTHER RECOMMENDATIONS

No specific treatment is recommended at this time. Recheck echo in 6 to 12 months, earlier if any clinical signs initiate.



PATIENT

Grayson Overly

SPECIES

Feline

BREED

DSH

SEX

Neutered Male

AGE

4 Years

WEIGHT

12.08 lbs

INTERPRETED BY

Eric Lindquist, DMV,
DABVP(CFM), Cert.
IVUSS

**IMAGING
PERFORMED BY**

Dr. Renee Zeigler-Post

HOSPITAL NAME

For Cats Only
Veterinary Clinic

REFERRING VET

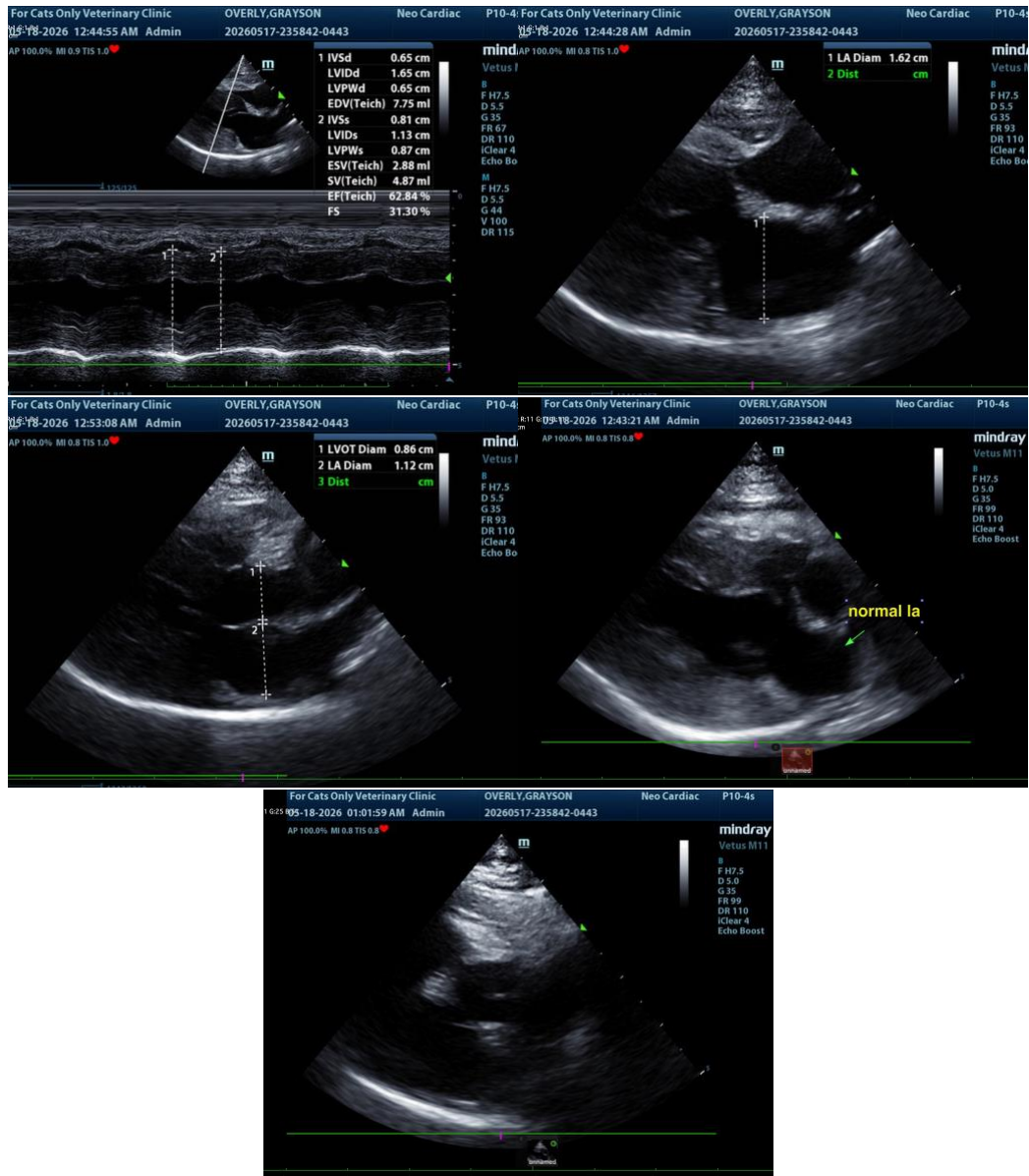
Dr. Renee Zeigler-Post

INVOICE

16346

DATE

05/18/26



The information and recommendations provided are based on the images presented by the referring veterinarian/sonographer. No evaluation can be communicated regarding pathology that was not visible in the image/video clips provided.

Thank you for this referral. If the clinical or image interpretation does not parallel your findings or if I can be of any further assistance, please contact me.

Eric Lindquist, DMV, DABVP(CFM), Cert. IVUSS,

CEO, Owner, Founder -- SonoPath.com

info@SonoPath.com



PATIENT

Grayson Overly

SPECIES

Feline

BREED

DSH

SEX

Neutered Male

AGE

4 Years

WEIGHT

12.08 lbs

INTERPRETED BY

Eric Lindquist, DMV,
DABVP(CFM), Cert.
IVUSS

IMAGING PERFORMED BY

Dr. Renee Zeigler-Post

HOSPITAL NAME

For Cats Only
Veterinary Clinic

REFERRING VET

Dr. Renee Zeigler-Post

INVOICE

16346

DATE

05/18/26