



PATIENT	PRESENTING CLINICAL SIGNS
Ziggy Reade	FB vs severe enteritis, dilated intestines
SPECIES	ULTRASONOGRAPHIC EXAMINATION OF THE ABDOMEN
Feline	Urinary System
BREED	The urinary bladder , trigone, and pelvic urethra presented normal thicknesses and normal tone. The ureters were not visible which is normal. No uroliths or sediment were visualized and anechoic urine was present. No evidence of inflammatory or neoplastic changes was noted. Ureteral papillae were normal.
Domestic Shorthair	
SEX	The kidneys were mildly enlarged and the architecture was maintained. The corticomedullary definition was adequate. The right kidney measured 5.05 cm. The left kidney measured 5.5 cm.
Male	
AGE	Adrenal Glands
4 years	Both adrenal glands were visualized and recognized as having normal shape, size, position and echogenicity for this breed. The phrenic vasculature, glandular echogenicity and detail were unremarkable. Capsule, cortex, and medullary definition were normal for this age patient.
WEIGHT	Spleen
16 lbs	The spleen presented a smooth homogeneous parenchyma hyperechoic to liver and renal cortical parenchyma. The capsule was smooth without noticeable expansion or deviation from within the spleen or adjacent pathology. The splenic vasculature demonstrated normal volume without signs of congestion or thrombosis. No sonographic evidence of acute or chronic inflammatory, neoplastic, or infarctual changes was noted.
INTERPRETED BY	Liver
Eric Lindquist, DMV DABVP, Cert. IVUSS	The liver was swollen and mildly irregular. The gallbladder and common bile duct were unremarkable.
IMAGING PERFORMED BY	Gastrointestinal
Jenn	The gastrointestinal tract revealed variable intestinal thickening with loss of mural detail and hypertrophied muscularis. A cluster of mesenteric lymph nodes were enlarged, irregular and hypoechoic with pericapsular inflammation and regional inflammation. The grouping of lymph nodes measured 3.0-3.5 cm. Reactive mesentery was noted associated with portions of the intestinal tract.
HOSPITAL NAME	Pancreas
Rockaway AH	The base and limbs of the pancreas were observed to be largely isoechoic to surrounding omental fat. Pancreatic duct and capsular contour were acceptably normal and parenchyma respected normal curvilinear patterns. No overt evidence of active inflammatory or neoplastic disease was noted.
REFERRING VET	
Dr. Maniar	
INVOICE	
30494	
DATE	
5/18/22	



PATIENT

Ziggy Reade

ULTRASONOGRAPHIC FINDINGS

Mesenteric lymph node mass.

Early infiltrative intestinal pattern.

SPECIES

Feline

Possible hepatic involvement.

BREED

Domestic Shorthair

INTERPRETATION OF THE FINDINGS & FURTHER RECOMMENDATIONS

FNA of the lymph nodes and liver is indicated for further definition. Lymphoma or similar neoplasia is likely. Dry form FIP is a minor potential.

SEX

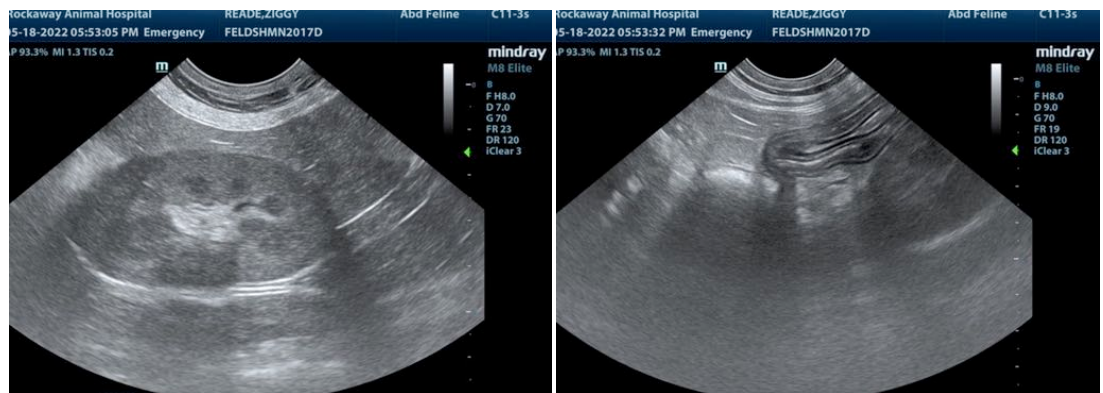
Male

AGE

4 years

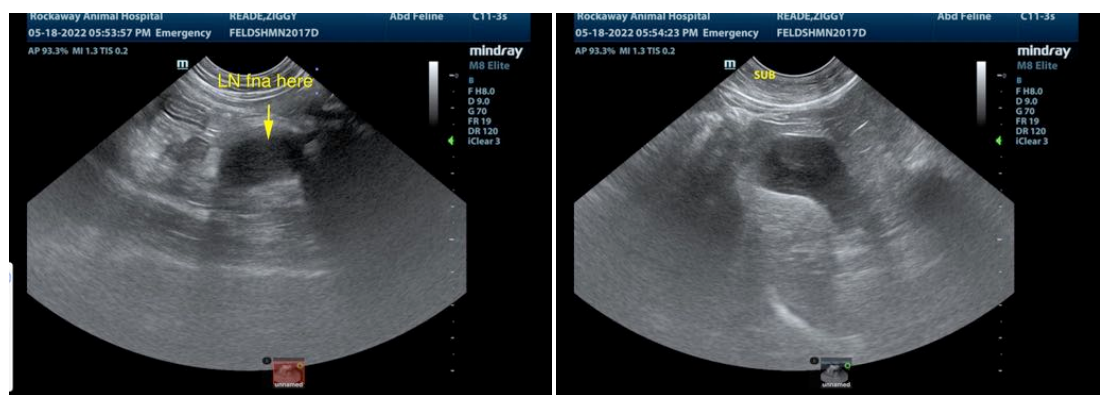
WEIGHT

16 lbs



INTERPRETED BY

Eric Lindquist, DMV
DABVP, Cert. IVUSS



IMAGING PERFORMED BY

Jenn

HOSPITAL NAME

Rockaway AH

REFERRING VET

Dr. Maniar

INVOICE

30494

DATE

5/18/22



PATIENT

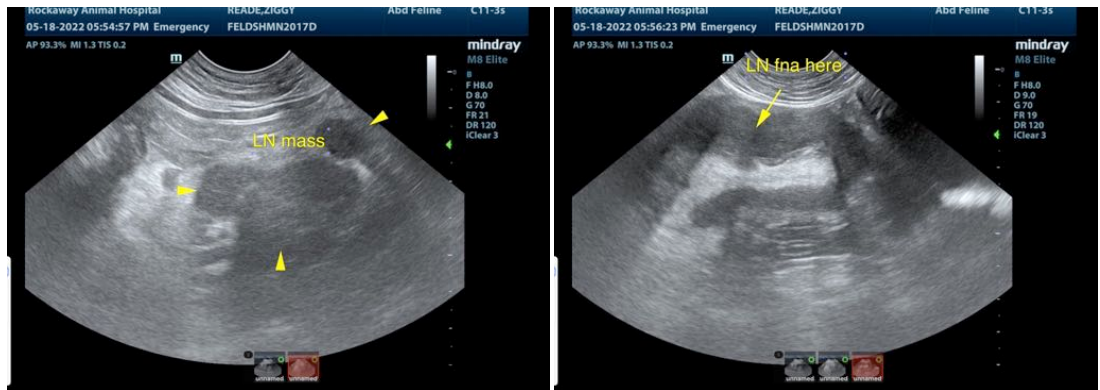
Ziggy Reade

SPECIES

Feline

BREED

Domestic Shorthair



SEX

Male

The information and recommendations provided are based on the images presented by the referring veterinarian/sonographer. No evaluation can be communicated regarding pathology that was not visible in the image/video clips provided.

AGE

4 years

Thank you for this referral. If the clinical or image interpretation does not parallel your findings or if I can be of any further assistance please contact me.

WEIGHT

16 lbs

Eric Lindquist, DMV, DABVP, Cert. IVUSS, CEO of SonoPath.com
info@SonoPath.com

INTERPRETED BY

Eric Lindquist, DMV
DABVP, Cert. IVUSS

IMAGING PERFORMED BY

Jenn

HOSPITAL NAME

Rockaway AH

REFERRING VET

Dr. Maniar

INVOICE

30494

DATE

5/18/22