

**PATIENT**

Wiggles Sorrels

**SPECIES**

Canine

**BREED**

Yorkshire Terrier

**SEX**

Male

**AGE**

6 Years

**WEIGHT**

10.4 Pounds

**INTERPRETED BY**

Eric Lindquist, DMV

DABVP, Cert. IVUSS

**IMAGING PERFORMED BY**

Harold Mike Beard

**HOSPITAL NAME**

West Prince AH

**REFERRING VET**

Dr. Hamm

**INVOICE**

37718

**DATE**

5/18/22

**PRESENTING CLINICAL SIGNS**

Bloody diarrhea, not eating today.

Abnormal PE/Chem/CBC/UA Results: Cranial abd pain. Positive murphy sign. Chemistry Lipase 6970. CBC neutrophilic leukocytosis.

**ULTRASONOGRAPHIC EXAMINATION OF THE ABDOMEN**

**Urinary System**

The **urinary bladder**, trigone, and pelvic urethra presented normal thicknesses and normal tone. The ureters were not visible which is normal. No uroliths or sediment were visualized and anechoic urine was present. No evidence of inflammatory or neoplastic changes were noted. Ureteral papillae were normal.

The **kidneys** revealed normal size and structure, corticomedullary definition and ratio for this age. The cortices presented largely uniform texture with normal echogenic relationship to liver and spleen. Medullary structure differed distinctly from the cortex and no evidence of pelvic dilation was present. The capsules were acceptably uniform without significant irregularities. The left kidney measured 4.0 cm. The right kidney measured 4.0 cm.

**Adrenal Glands**

The **left adrenal gland** was visualized and recognized as having normal shape, size, position and echogenicity for this breed. The phrenic vasculature, glandular echogenicity and detail were unremarkable. Capsule, cortex, and medullary definition were normal for this age patient. The left adrenal gland measured 0.50 cm.

The region of the **right adrenal gland** was imaged, no evident pathology.

**Spleen**

The **spleen** presented a smooth homogeneous parenchyma hyperechoic to liver and renal cortical parenchyma. The capsule was smooth without noticeable expansion or deviation from within the spleen or adjacent pathology. The splenic vasculature demonstrated normal volume without signs of congestion or thrombosis. No sonographic evidence of acute or chronic inflammatory, neoplastic, or infarctual changes were noted.

**Liver**

The **liver** images submitted revealed subjectively normal liver size, contour, and structure. Parenchymal echogenicity was naturally coarse and hypoechoic to the spleen. Vascular and biliary tracts were of normal volume with no evidence of congestion. The gallbladder presented acceptably thin walls with primarily anechoic content. The cystic and common bile ducts were normal. No pathological hepatic lymphadenopathy was evident. No overt structural evidence of inflammatory, infiltrative or regenerative pathology was evident.

**Gastrointestinal**

Examination of the **gastrointestinal tract** revealed an unremarkable stomach and small intestine regarding structure. There were minor areas of luminal fluid noted. There was no evidence of obstructive pattern. Curvilinear patterns were retained throughout the gastrointestinal tract. Areas of hyperperistalsis were noted. This is consistent with response to irritation. The colon was unremarkable.



**PATIENT**

**Pancreas**

Wiggles Sorrels

Minor heterogeneous changes noted in the pancreas.

**SPECIES**

Canine

**ULTRASONOGRAPHIC FINDINGS**

- Non-specific gastroenteritis presentation
- Minor heterogeneous pancreas

**BREED**

Yorkshire Terrier

**INTERPRETATION OF THE FINDINGS & FURTHER RECOMMENDATIONS**

No evidence of foreign body or neoplasia. Dietary indiscretion, food intolerance, structurally insignificant inflammatory bowel or occult parasitism and occult Addison's are all potentials. Cross reactivity with intestinal lipase may be playing a role in this case.

**SEX**

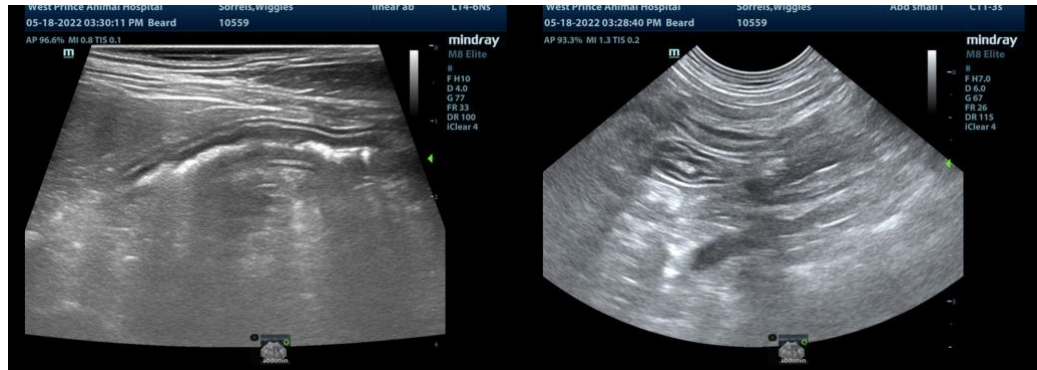Male

**AGE**

6 Years

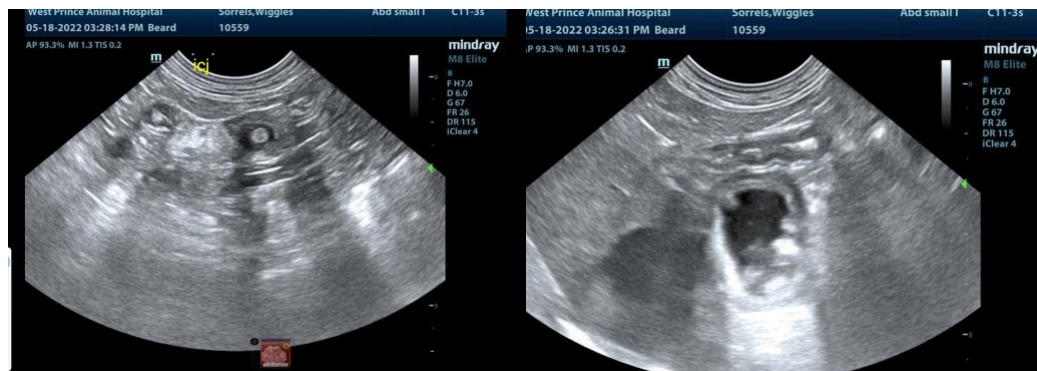
**WEIGHT**

10.4 Pounds



**INTERPRETED BY**

Eric Lindquist, DMV  
DABVP, Cert. IVUSS

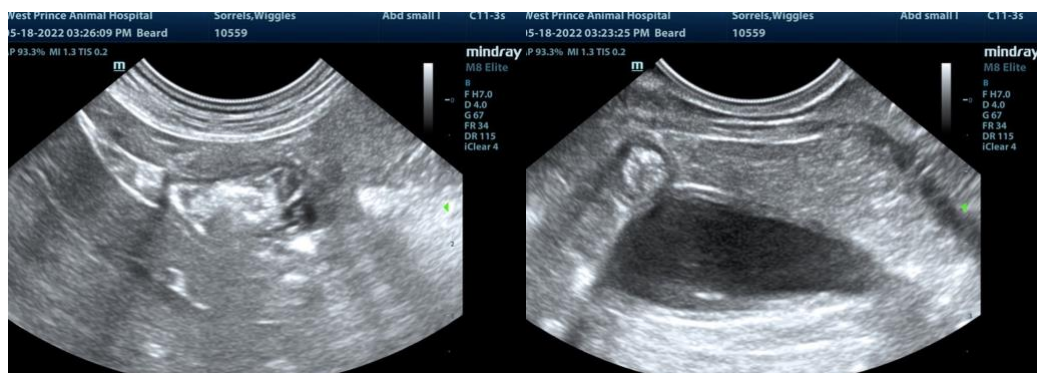


**IMAGING PERFORMED BY**

Harold Mike Beard

**HOSPITAL NAME**

West Prince AH



**REFERRING VET**

Dr. Hamm

**INVOICE**

37718

**DATE**

5/18/22



**PATIENT**

Wiggles Sorrels

The information and recommendations provided are based on the images presented by the referring veterinarian/sonographer. No evaluation can be communicated regarding pathology that was not visible in the image/video clips provided.

**SPECIES**

Canine

Thank you for this referral. If the clinical or image interpretation does not parallel your findings or if I can be of any further assistance please contact me.

**BREED**

Yorkshire Terrier

Eric Lindquist, DMV, DABVP, Cert. IVUSS, CEO of SonoPath.com

[info@SonoPath.com](mailto:info@SonoPath.com)

**SEX**

Male

**AGE**

6 Years

**WEIGHT**

10.4 Pounds

**INTERPRETED BY**

Eric Lindquist, DMV

DABVP, Cert. IVUSS

**IMAGING PERFORMED BY**

Harold Mike Beard

**HOSPITAL NAME**

West Prince AH

**REFERRING VET**

Dr. Hamm

**INVOICE**

37718

**DATE**

5/18/22