



**PATIENT**

Lucy Nowell

**PRESENTING CLINICAL SIGNS**

Vomited last night. Decreased appetite since.

**SPECIES**

Canine

**ULTRASONOGRAPHIC EXAMINATION OF THE ABDOMEN**

**Urinary System**

**BREED**

Lab

The **urinary bladder**, trigone, and pelvic urethra presented normal thicknesses and normal tone. The ureters were not visible which is normal. No uroliths or sediment were visualized and anechoic urine was present. No evidence of inflammatory or neoplastic changes were noted. Ureteral papillae were normal.

**SEX**

Spayed Female

The **kidneys** revealed normal size and structure, corticomedullary definition and ratio for this age. The cortices presented largely uniform texture with normal echogenic relationship to liver and spleen. Medullary structure differed distinctly from the cortex and no evidence of pelvic dilation was present. The capsules were acceptably uniform without significant irregularities. The left kidney measured 6.9 cm. The right kidney measured 6.35 cm.

**AGE**

2 Years

**Adrenal Glands**

**WEIGHT**

78 Pounds

Both **adrenal glands** were visualized and recognized as having normal shape, size, position and echogenicity for this breed. The phrenic vasculature, glandular echogenicity and detail were unremarkable. Capsule, cortex, and medullary definition were normal for this age patient. The right adrenal gland measured 3.05 cm x 0.89 cm. The left adrenal gland measured 2.47 cm x 0.61 cm.

**Spleen**

**INTERPRETED BY**

Eric Lindquist, DMV

DABVP, Cert. IVUSS

The **spleen** presented a smooth homogeneous parenchyma hyperechoic to liver and renal cortical parenchyma. The capsule was smooth without noticeable expansion or deviation from within the spleen or adjacent pathology. The splenic vasculature demonstrated normal volume without signs of congestion or thrombosis. No sonographic evidence of acute or chronic inflammatory, neoplastic, or infarctual changes were noted.

**IMAGING PERFORMED BY**

Dr. Rodriguez

**Liver**

**HOSPITAL NAME**

Foxfield Vet Services

The **liver** images submitted revealed subjectively normal liver size, contour, and structure. Parenchymal echogenicity was naturally coarse and hypoechoic to the spleen. Vascular and biliary tracts were of normal volume with no evidence of congestion. The gallbladder presented acceptably thin walls with primarily anechoic content. The cystic and common bile ducts were normal. No pathological hepatic lymphadenopathy was evident. No overt structural evidence of inflammatory, infiltrative or regenerative pathology was evident.

**REFERRING VET**

Dr. Rodriguez

**Gastrointestinal**

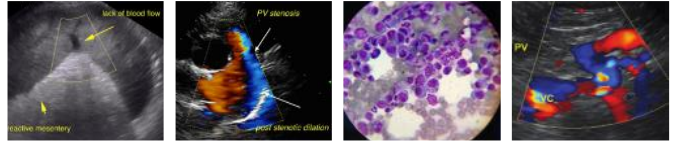
**INVOICE**

37721

The **gastrointestinal** presentation revealed mild uniform prominence of the gastric mucosa as well as areas of "ropey" small intestinal wall with slight disruption of the normal 1:3 muscularis/mucosal ratio. The intestinal submucosa was slightly irregular, thickened and hyperechoic suggestive of low grade, chronic disease. No concerning lymphadenopathy was visible. No evidence of obstruction was present. Chronic inflammatory bowel disease is likely with a low possibility of an early neoplastic event such as lymphoma. Full thickness tissue biopsies via open laparotomy, ideally guided by intraoperative ultrasound in order to obtain the most representative mural sample, would be necessary to rule out this possibility.

**DATE**

5/18/22



**PATIENT**

**Pancreas**

Lucy Nowell

The base and limbs of the **pancreas** were observed to be largely isoechoic to surrounding omental fat. Pancreatic duct and capsular contour were acceptably normal and parenchyma respected normal curvilinear patterns. No overt evidence of active inflammatory or neoplastic disease was noted.

**SPECIES**

Canine

**ULTRASONOGRAPHIC FINDINGS**

- Minor intestinal thickening, no evidence of foreign body

**BREED**

Lab

**INTERPRETATION OF THE FINDINGS & FURTHER RECOMMENDATIONS**

Underlying parasitic disease, inflammatory bowel, or chronic insult all possible. Anti-parasitic protocol, 24-hour NPO, hydrolyzed diet all indicated in this patient. No evidence of significant disease other than the intestinal thickening.

**SEX**

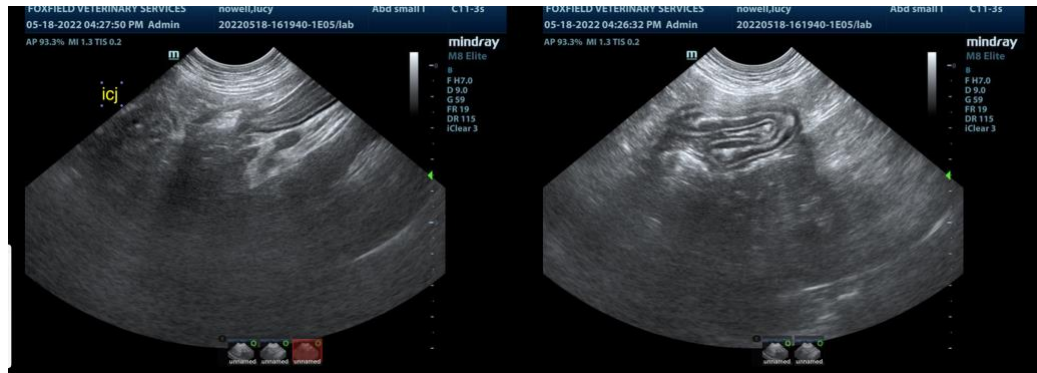
Spayed Female

**AGE**

2 Years

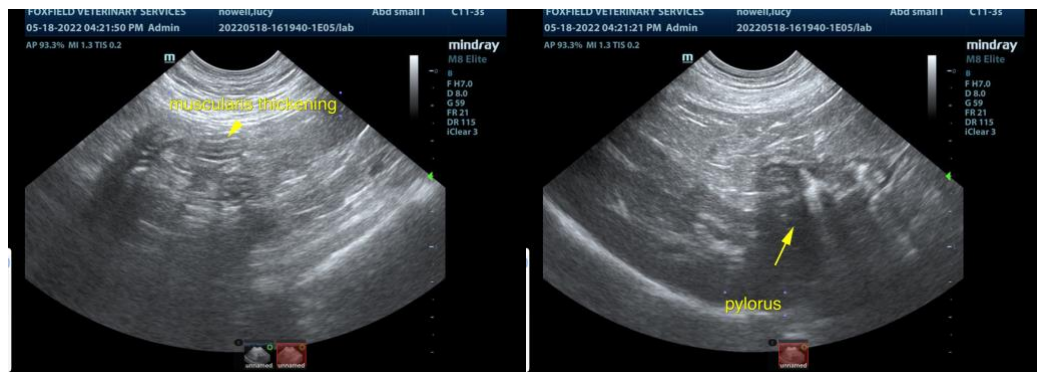
**WEIGHT**

78 Pounds



**INTERPRETED BY**

Eric Lindquist, DMV



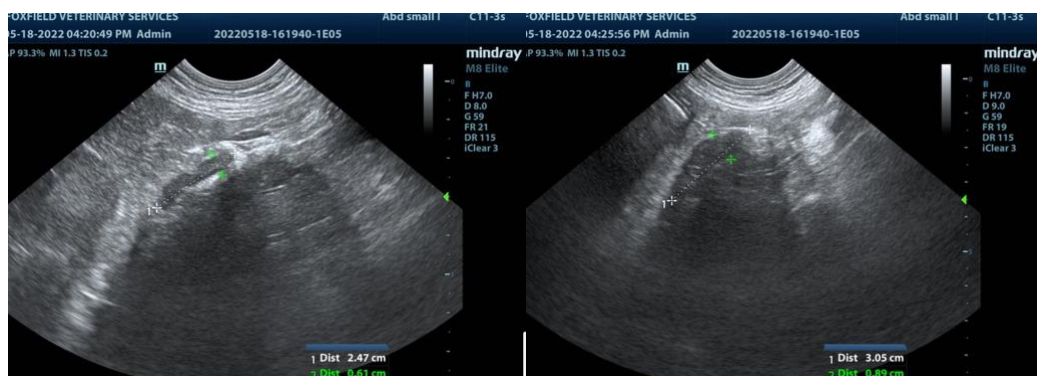DABVP, Cert. IVUSS

**IMAGING PERFORMED BY**

Dr. Rodriguez

**HOSPITAL NAME**

Foxfield Vet Services



**REFERRING VET**

Dr. Rodriguez

**INVOICE**

37721

**DATE**

5/18/22



**PATIENT**

Lucy Nowell

**SPECIES**

Canine

**BREED**

Lab

**SEX**

Spayed Female

**AGE**

2 Years

**WEIGHT**

78 Pounds

**INTERPRETED BY**

Eric Lindquist, DMV

DABVP, Cert. IVUSS

**IMAGING PERFORMED BY**

Dr. Rodriguez

**HOSPITAL NAME**

Foxfield Vet Services

**REFERRING VET**

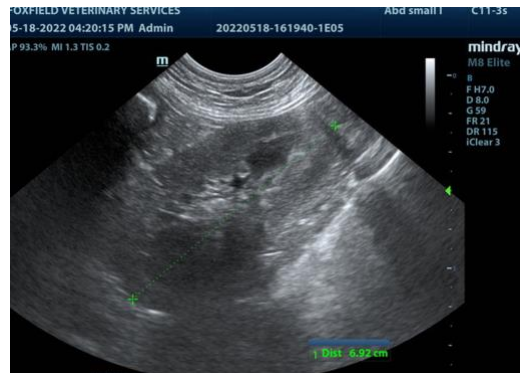Dr. Rodriguez

**INVOICE**

37721

**DATE**

5/18/22



The information and recommendations provided are based on the images presented by the referring veterinarian/sonographer. No evaluation can be communicated regarding pathology that was not visible in the image/video clips provided.

Thank you for this referral. If the clinical or image interpretation does not parallel your findings or if I can be of any further assistance please contact me.

Eric Lindquist, DMV, DABVP, Cert. IVUSS, CEO of SonoPath.com

[info@SonoPath.com](mailto:info@SonoPath.com)