

PATIENT PRESENTING CLINICAL SIGNS

Barkley Cramer
 Enlarged soft tissue structure adjacent to larynx. On palpation there may be mild enlargement of thyroid but no firm swellings

SPECIES Abnormal PE/Chem/CBC/UA Results: 166/113 Current Medications LRS 20ml/hr Buprenorphine 0.01mg/kg IV q8h

Canine

BREED

Havanese X

SEX

Neutered Male

AGE

11 Years

WEIGHT

5.94 kg

INTERPRETED BY

Eric Lindquist, DMV
 DABVP, Cert. IVUSS

IMAGING PERFORMED BY

Sara Hansen

HOSPITAL NAME

Wilvet Salem

REFERRING VET

Dr. Wepprich

INVOICE

37738

DATE

5/18/22

ULTRASONOGRAPHIC EXAMINATION OF THE NECK

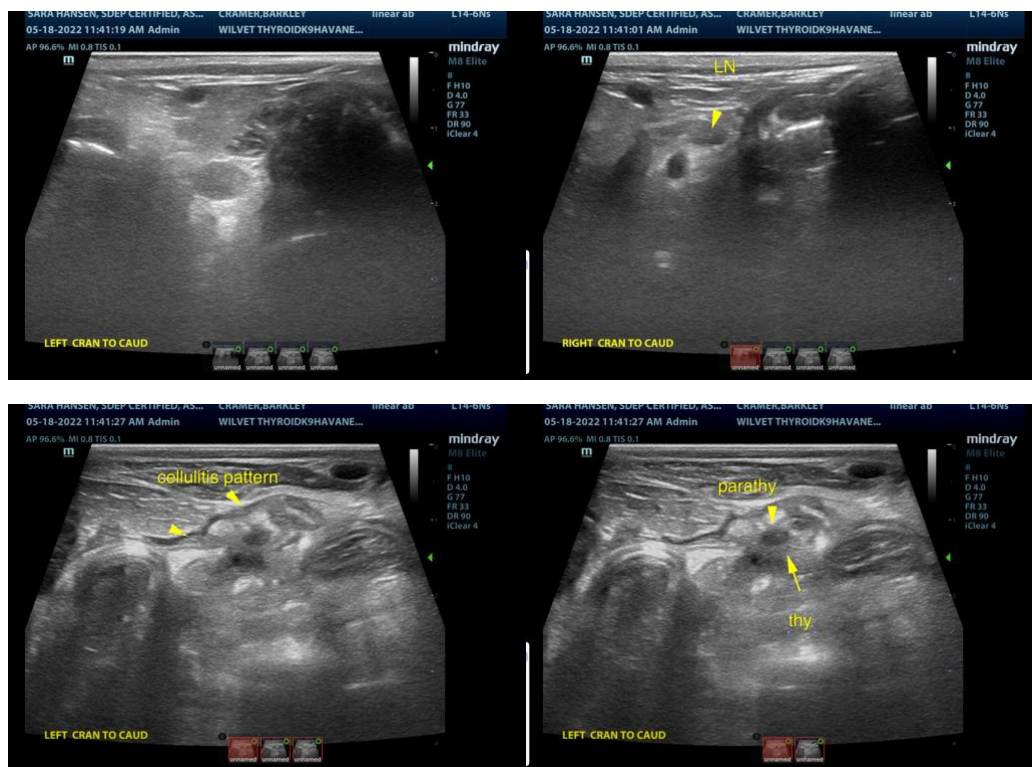
The region of the left thyroid lobe revealed reactive hyperechoic fat and hypoechoic lymphadenopathy. Regional cellulitis pattern noted. The left thyroid parenchyma was unremarkable with a 3.0 mm parathyroid nodule. This is most consistent with cellulitis/lymphadenitis. No masses noted. The region to the right of the trachea and larynx revealed slight reactive lymphadenopathy. The trachea, esophagus and salivary glands all appeared unremarkable. The hyperechoic inflamed/reodeled fat in the region obscured some visibility of underlying structures.

ULTRASONOGRAPHIC FINDINGS

- Cellulitis pattern with minor lymphadenopathy

INTERPRETATION OF THE FINDINGS & FURTHER RECOMMENDATIONS

No overt evidence of neoplasia. Recommend a broad-spectrum antibiotic protocol in this patient and reassessment of the region in approximately one week.





PATIENT

Barkley Cramer

SPECIES

Canine

BREED

Havanese X

SEX

Neutered Male

AGE

11 Years

WEIGHT

5.94 kg

INTERPRETED BY

Eric Lindquist, DMV
DABVP, Cert. IVUSS

IMAGING PERFORMED BY

Sara Hansen

HOSPITAL NAME

Wilvet Salem

REFERRING VET

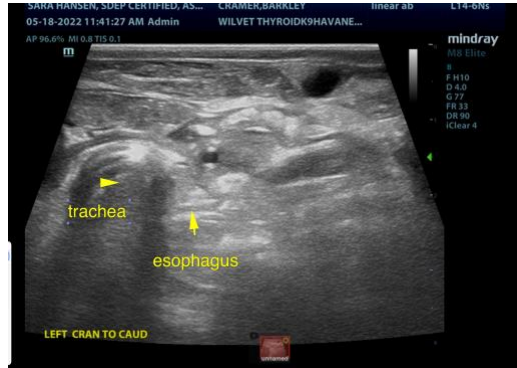Dr. Wepprich

INVOICE

37738

DATE

5/18/22



The information and recommendations provided are based on the images presented by the referring veterinarian/sonographer. No evaluation can be communicated regarding pathology that was not visible in the image/video clips provided.

Thank you for this referral. If the clinical or image interpretation does not parallel your findings or if I can be of any further assistance please contact me.

Eric Lindquist, DMV, DABVP, Cert. IVUSS, CEO of SonoPath.com

info@SonoPath.com