

**DATE**

5/17/22

PATIENT

Trifecta Eubank-Warble

SPECIES

Feline

BREED

DSH

SEX

Spayed Female

AGE

1/1/07

WEIGHT

5.75 Pounds

INTERPRETED BYEric Lindquist, DMV
DABVP, Cert. IVUS**IMAGING PERFORMED BY**

Rachel Brillhart RDMS

HOSPITAL NAMECat Sense Feline
Hospital**REFERRING VET**

Dr. Sinclair

INVOICE

37695

PRESENTING CLINICAL SIGNS

Trifecta has been losing weight and is also having diarrhea that is often the color of baby food. She is hyperthyroid but I am concerned that she may also have concurrent intestinal disease as well. On PE she has a grade 3/6 heart murmur and the intestines feel thickened. We are assessing her abdomen for signs of neoplasia/other reason not to pursue I-131 therapy to tx the hyperthyroidism.

Current Medications: None currently.

Lab Results: T4 10.6.

Date of Previous IntraPet Ultrasound: No previous.

Sedation: Not required to complete full diagnostic ultrasound.

Stat Report: Not requested.

ULTRASONOGRAPHIC EXAMINATION OF THE ABDOMEN**Urinary System**

The **urinary bladder**, trigone, and pelvic urethra presented normal thicknesses and normal tone. The ureters were not visible which is normal. No uroliths or sediment were visualized and anechoic urine was present. No evidence of inflammatory or neoplastic changes were noted. Ureteral papillae were normal.

The **kidneys** revealed largely normal size and structure, corticomedullary definition and ratio (cortex 1/3 of medulla) were essentially maintained with some age-related loss of curvilinear patterns regarding the capsule and C/M junction. The cortices presented largely uniform texture with some increased echogenicity expected for his age patient. Medullary structure differed distinctly from that of the cortex and no evidence of pelvic dilation was present. The right kidney measured 3.82 cm. The left kidney measured 4.19 cm.

Adrenal Glands

Both **adrenal glands** were visualized and recognized as having normal shape, size, position and echogenicity for this breed. The phrenic vasculature, glandular echogenicity and detail were unremarkable. Capsule, cortex, and medullary definition were normal for this age patient. The left adrenal gland measured 0.57 cm.

Spleen

The **spleen** was mildly enlarged at 1.0 cm. Scalloping contour noted.

Liver

The **liver** revealed coarse architecture and increased portal markings. A moderate amount of remodeling present, history of chronic cholangitis likely. Duplicated gallbladder noted. The common bile duct was normal at 0.35 cm, slightly thickened duodenal papilla. Hepatic veins were dilated in this patient. A slight amount of free fluid was present.

Gastrointestinal

The **stomach** was overdistended with chyme. Delayed GI outflow present. Small intestine and colon were unremarkable with normal curvilinear mural patterns and chyme transit. Reactive lymph nodes noted in the mesenteric root.

Pancreas

The base and limbs of the **pancreas** were observed to be largely isoechoic to surrounding omental fat. Some parenchymal remodeling, however, with mild deviation from curvilinear normalcy was observed. Pancreatic duct and capsular irregularities were present consistent with age related changes. If pain upon imaging (+ Murphy sign) was present or if the patient is focally painful in subxyphoid palpation then low-grade smoldering chronic pancreatitis should be suspected.

Free Abdomen

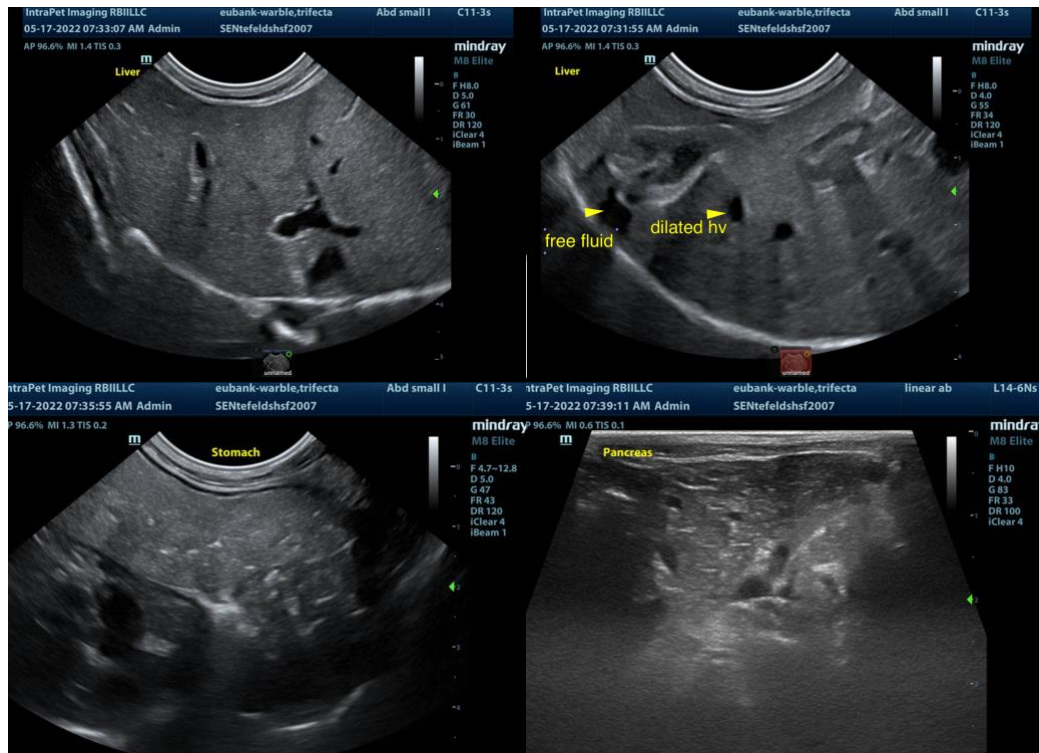
Rapid view of the heart revealed mild volume overload. However, full echocardiogram is likely in this patient's best interest.

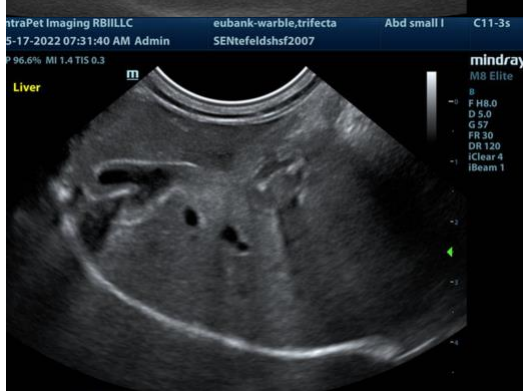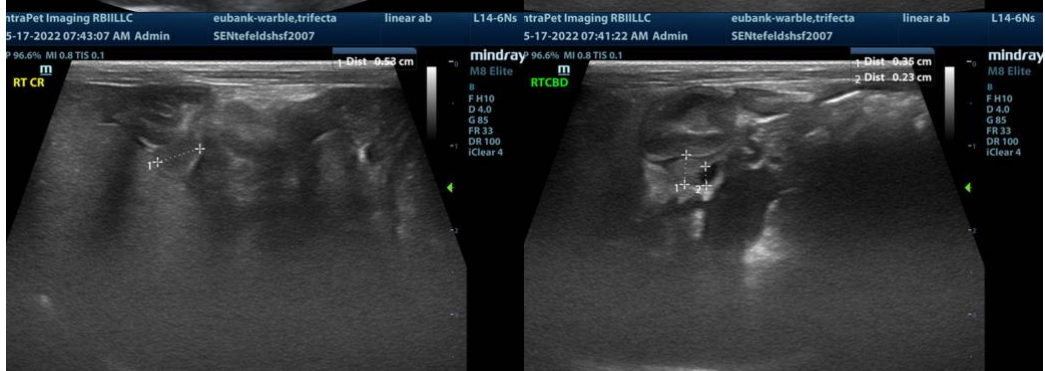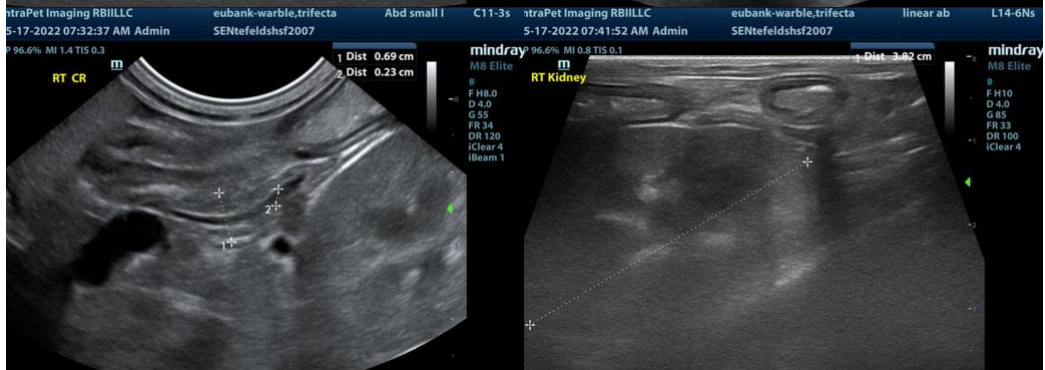
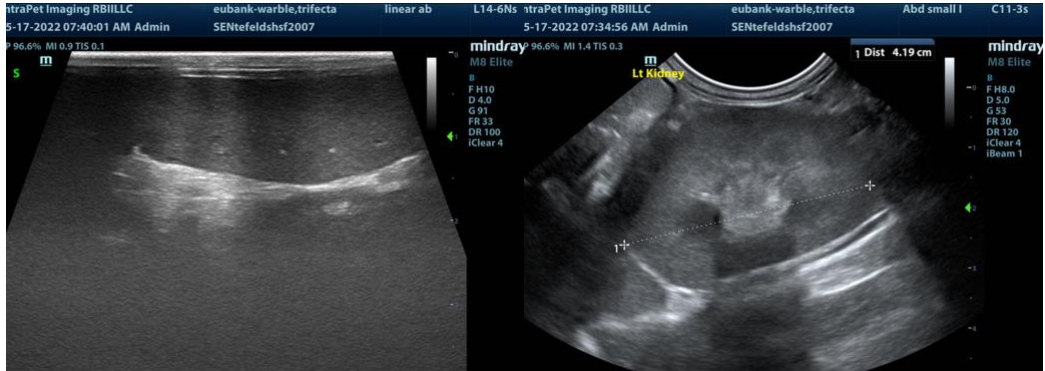
ULTRASONOGRAPHIC FINDINGS

- Chronic triad presentation with duplicated gallbladder
- Passive congestion liver pattern

INTERPRETATION OF THE FINDINGS & FURTHER RECOMMENDATIONS

Chest radiographs +/- echocardiogram recommended to assess for any evidence of obstructive or right-sided cardiac disease to be responsible for passive congestion. Chronic triad presentation. No evidence of neoplasia. Maldigestion panel, three view chest radiographs and full CNS examination is recommended to examine for occult disease that could be responsible for the weight loss. Evaluation for competitive eating environments should also be considered.





The information and recommendations provided are based on the images presented by the referring veterinarian/sonographer. No evaluation can be communicated regarding pathology that was not visible in the image/video clips provided.

Thank you for this referral. If the clinical or image interpretation does not parallel your findings or if I can be of any further assistance please contact me.

Eric Lindquist, DMV, DABVP, Cert. IVUSS, CEO of SonoPath.com
info@SonoPath.com