



PATIENT PRESENTING CLINICAL SIGNS

Sassy Sisak History: vomiting, hematochezia HGE with pancreatitis R/O additional underlying dz Current meds IVF PlasmaLyte Metro and Unasyn

SPECIES ULTRASONOGRAPHIC EXAMINATION OF THE ABDOMEN

Canine

Urinary System

BREED

Schnauzer

The **urinary bladder**, trigone, and pelvic urethra presented normal thicknesses and normal tone. The ureters were not visible which is normal. No uroliths or sediment were visualized and anechoic urine was present. No evidence of inflammatory or neoplastic changes was noted. Ureteral papillae were normal.

SEX

Female

The **kidneys** revealed largely normal size and structure, corticomedullary definition and ratio (cortex 1/3 of medulla) were essentially maintained with some age-related loss of curvilinear patterns regarding the capsule and C/M junction. The cortices presented largely uniform texture with some increased echogenicity expected for this age patient. Medullary structure differed distinctly from that of the cortex and no evidence of pelvic dilation was present. Mild mineralization was noted. The left kidney measured 3.9 cm.

AGE

12 years

WEIGHT

15 lbs

Adrenal Glands

Both **adrenal glands** were visualized and recognized as having normal shape, size, position and echogenicity for this breed. The phrenic vasculature, glandular echogenicity and detail were unremarkable. Capsule, cortex, and medullary definition were normal for this age patient. The right adrenal gland measured 1.99 x 0.49 cm at the caudal pole and 0.91 cm at the cranial pole. The left adrenal gland measured 1.1 x 0.42 cm at the caudal pole and 0.53 cm at the cranial pole.

INTERPRETED BY

Eric Lindquist, DMV
DABVP, Cert. IVUSS

Spleen

The **spleen** presented a smooth homogeneous parenchyma hyperechoic to liver and renal cortical parenchyma. The capsule was smooth without noticeable expansion or deviation from within the spleen or adjacent pathology. The splenic vasculature demonstrated normal volume without signs of congestion or thrombosis. No sonographic evidence of acute or chronic inflammatory, neoplastic, or infarctual changes was noted.

IMAGING PERFORMED BY

Jenn

HOSPITAL NAME

Rockaway AH

Liver

The **liver** images from right and left intercostal as well as subcostal views revealed subjectively normal liver size, contour, and structure. Some age-related parenchymal remodeling was noted but likely not clinically significant at this time. Vascular and biliary tracts were of normal volume and no evidence of congestion was noted. The gallbladder presented some dependent debris with essentially normal contour. The cystic and common bile ducts were normal. No overt evidence of active inflammatory, infiltrative or regenerative pathology was noted but should be paired with current or past LE elevations regarding any clinical significance to this presentation. The hepatic lymph nodes were unremarkable.

REFERRING VET

Dr. Maniar

INVOICE

30464

DATE

5/17/22



PATIENT *Gastrointestinal*

Sassy Sisak

The **gastrointestinal tract** revealed an edematous wall and hyperperistalsis with no loss of mural detail. Minor enhanced surrounding fat was noted around the regions of the gastrointestinal serosa. There was no evidence of foreign body or neoplastic criteria. Images from the stomach, small intestine and colon were presented. This is most consistent with gastroenteritis owing to viral, bacterial/endotoxin or possible parasitic disease.

SPECIES

Canine

BREED *Pancreas*

Schnauzer

The base and limbs of the **pancreas** were observed to be largely isoechoic to surrounding omental fat. Pancreatic duct and capsular contour were acceptably normal and parenchyma respected normal curvilinear patterns. No overt evidence of active inflammatory or neoplastic disease was noted.

SEX

Female

ULTRASONOGRAPHIC FINDINGS

AGE

12 years

Non-specific gastroenteritis.

INTERPRETATION OF THE FINDINGS & FURTHER RECOMMENDATIONS

WEIGHT

15 lbs

Dietary indiscretion, food intolerance/indiscretion, structurally insignificant inflammatory bowel or occult parasitism and occult Addison's are all potentials.

INTERPRETED BY

Eric Lindquist, DMV
DABVP, Cert. IVUSS

IMAGING PERFORMED BY

Jenn

HOSPITAL NAME

Rockaway AH

REFERRING VET

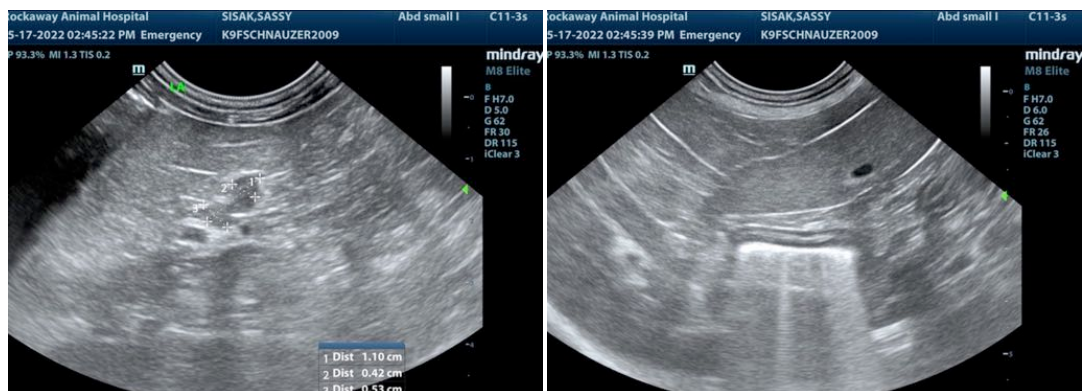
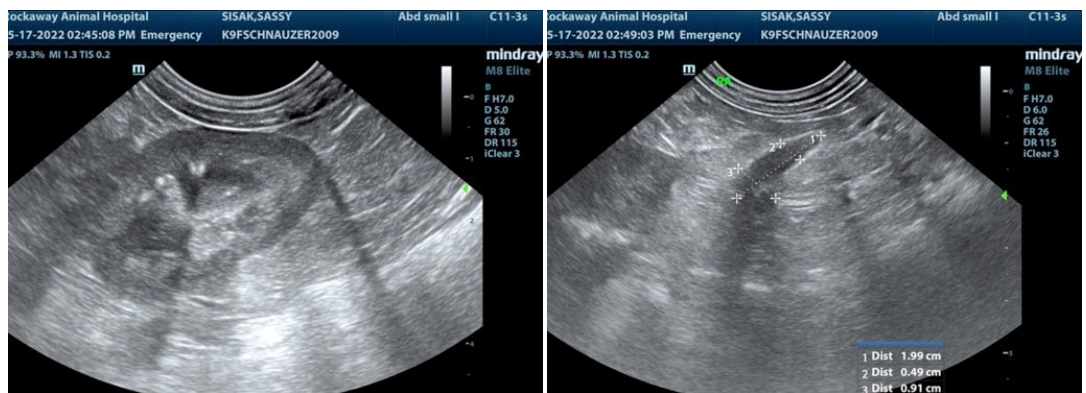
Dr. Maniar

INVOICE

30464

DATE

5/17/22





PATIENT

Sassy Sisak

SPECIES

Canine

BREED

Schnauzer

SEX

Female

AGE

12 years

WEIGHT

15 lbs

INTERPRETED BY

Eric Lindquist, DMV
DABVP, Cert. IVUSS

IMAGING PERFORMED BY

Jenn

HOSPITAL NAME

Rockaway AH

REFERRING VET

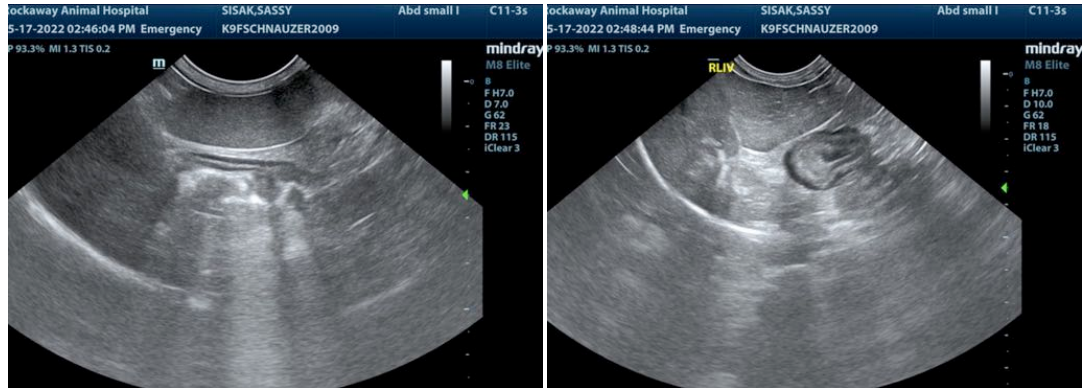
Dr. Maniar

INVOICE

30464

DATE

5/17/22



The information and recommendations provided are based on the images presented by the referring veterinarian/sonographer. No evaluation can be communicated regarding pathology that was not visible in the image/video clips provided.

Thank you for this referral. If the clinical or image interpretation does not parallel your findings or if I can be of any further assistance please contact me.

Eric Lindquist, DMV, DABVP, Cert. IVUSS, CEO of SonoPath.com
info@SonoPath.com