



PATIENT

Patches Kapitula

SPECIES

Feline

BREED

DSH

SEX

Neutered Male

AGE

9 Years 11 Months

WEIGHT

9.88 Pounds

INTERPRETED BY

Eric Lindquist, DMV
DABVP, Cert IVUSS

IMAGING PERFORMED BY

Denise Bruno, LVT,
RDMS

HOSPITAL NAME

Brooklyn Heights VH

REFERRING VET

Dr. Thomson

INVOICE

37702

DATE

5/17/22

PRESENTING CLINICAL SIGNS

Weight loss 2 lbs/ cachexia. Hx early renal disease- stable. Hypercalcemia. Evaluate for lymphoma, idiopathic hypercalcemia, other. Labs attached. Serum Calcium 12.7, Chol 348, USG 1.038.

ULTRASONOGRAPHIC EXAMINATION OF THE ABDOMEN

Urinary System

The **urinary bladder**, trigone, and pelvic urethra presented normal thicknesses and normal tone. The ureters were not visible which is normal. No uroliths or sediment were visualized and anechoic urine was present. No evidence of inflammatory or neoplastic changes were noted. Ureteral papillae were normal.

The **kidneys** revealed largely normal size and structure, corticomedullary definition and ratio (cortex 1/3 of medulla) were essentially maintained with some age-related loss of curvilinear patterns regarding the capsule and C/M junction. The cortices presented largely uniform texture with some increased echogenicity expected for his age patient. Medullary structure differed distinctly from that of the cortex and no evidence of pelvic dilation was present. The right kidney measured 3.76 cm. The left kidney measured 3.57 cm.

Adrenal Glands

Both **adrenal glands** were visualized and recognized as having normal shape, size, position and echogenicity for this breed. The phrenic vasculature, glandular echogenicity and detail were unremarkable. Capsule, cortex, and medullary definition were normal for this age patient. The right adrenal gland measured 0.31 cm. The left adrenal gland measured 0.34 cm.

Spleen

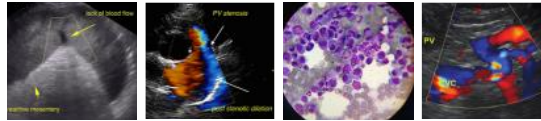
The **spleen** presented a smooth homogeneous parenchyma hyperechoic to liver and renal cortical parenchyma. The capsule was smooth without noticeable expansion or deviation from within the spleen or adjacent pathology. The splenic vasculature demonstrated normal volume without signs of congestion or thrombosis. No sonographic evidence of acute or chronic inflammatory, neoplastic, or infarctual changes were noted.

Liver

The **liver** images from right and left intercostal as well as subcostal views revealed subjectively normal liver size, contour, and structure. Some age-related parenchymal remodeling was noted but likely not clinically significant at this time. The left cranial liver revealed a hypoechoic 1.05 cm x 0.79 cm disruptive nodule. Vascular and biliary tracts were of normal volume and no evidence of congestion was noted. The gallbladder presented some dependent debris with essentially normal contour. The cystic and common bile ducts were normal. No overt evidence of active inflammatory, infiltrative or regenerative pathology was noted but should be paired with current or past LE elevations regarding any clinical significance to this presentation. The hepatic lymph nodes were unremarkable.

Gastrointestinal

The **gastrointestinal** presentation revealed mild uniform prominence of the gastric mucosa as well as areas of "ropey" small intestinal wall with slight disruption of the normal 1:3 muscularis/mucosal ratio. The intestinal submucosa was slightly irregular, thickened and hyperechoic suggestive of low grade, chronic disease. No concerning lymphadenopathy was visible. No evidence of obstruction was present. Chronic inflammatory bowel disease is likely with a low possibility of an early neoplastic event such as lymphoma. Full thickness tissue biopsies via open laparotomy, ideally guided by intraoperative



PATIENT

Patches Kapitula

ultrasound in order to obtain the most representative mural sample, would be necessary to rule out this possibility.

Pancreas

SPECIES

Feline

The base and limbs of the **pancreas** were observed to be largely isoechoic to surrounding omental fat. Undulating contour noted. Some parenchymal remodeling, however, with mild deviation from curvilinear normalcy was observed. Pancreatic duct and capsular irregularities were present consistent with age related changes. Dilated duct noted at 3.0 mm. If pain upon imaging (+ Murphy sign) was present or if the patient is focally painful in subxyphoid palpation then low-grade smoldering chronic pancreatitis should be suspected.

BREED

DSH

SEX

Neutered Male

- Minor intestinal thickening
- Chronic pancreatic changes
- Undefined hepatic nodule – differentials include emerging hepatic lymphoma, nodular hyperplasia, less likely abscessation.

AGE

9 Years 11 Months

INTERPRETATION OF THE FINDINGS & FURTHER RECOMMENDATIONS

Strong concern for emerging hepatic neoplasia/lymphoma. No other evidence of neoplasia present. FNA of the hepatic nodule recommended. Idiopathic hypercalcemia possible. Full thickness gastrointestinal, pancreatic and hepatic biopsies from a surgical perspective also an option. Chronic active pancreatitis and inflammatory bowel likely the cause of the immediate clinical presentation. Maldigestion panel, three view chest radiographs and full CNS examination is recommended to examine for occult disease that could be responsible for the weight loss. Evaluation for competitive eating environments should also be considered.

WEIGHT

9.88 Pounds

INTERPRETED BY

Eric Lindquist, DMV
DABVP, Cert IVUSS

IMAGING PERFORMED BY

Denise Bruno, LVT,
RDMS

HOSPITAL NAME

Brooklyn Heights VH

REFERRING VET

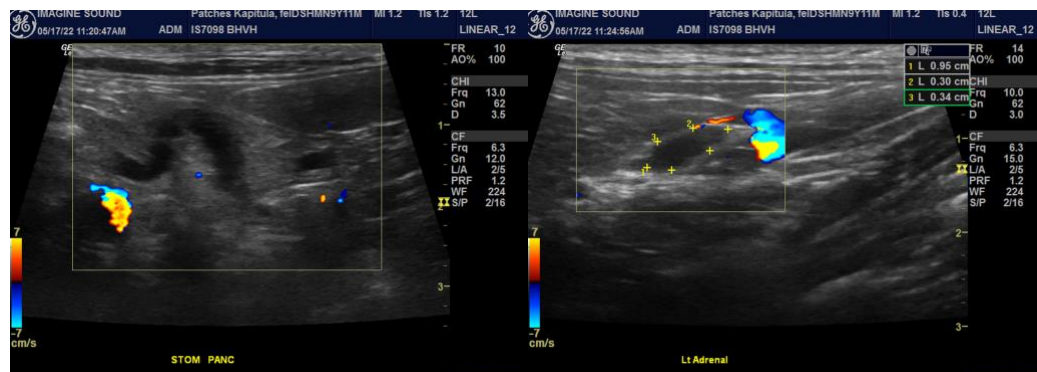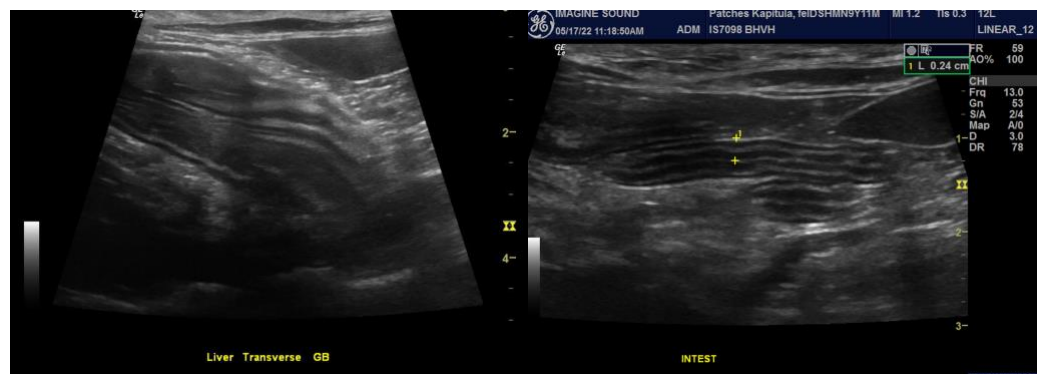
Dr. Thomson

INVOICE

37702

DATE

5/17/22





PATIENT

Patches Kapitula

SPECIES

Feline

BREED

DSH

SEX

Neutered Male

AGE

9 Years 11 Months

WEIGHT

9.88 Pounds

INTERPRETED BY

Eric Lindquist, DMV
 DABVP, Cert IVUSS

IMAGING PERFORMED BY

Denise Bruno, LVT,
 RDMS

HOSPITAL NAME

Brooklyn Heights VH

REFERRING VET

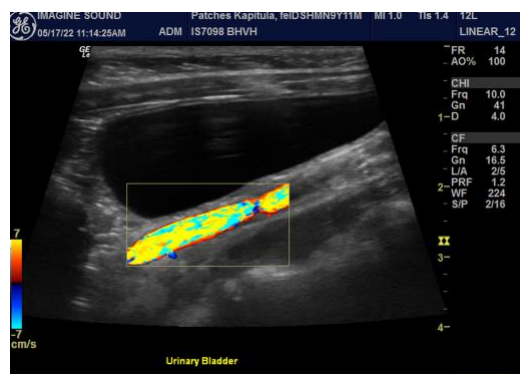
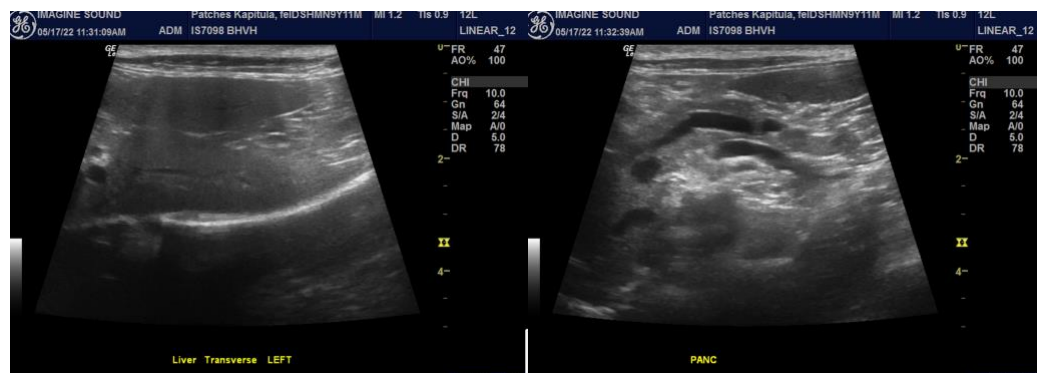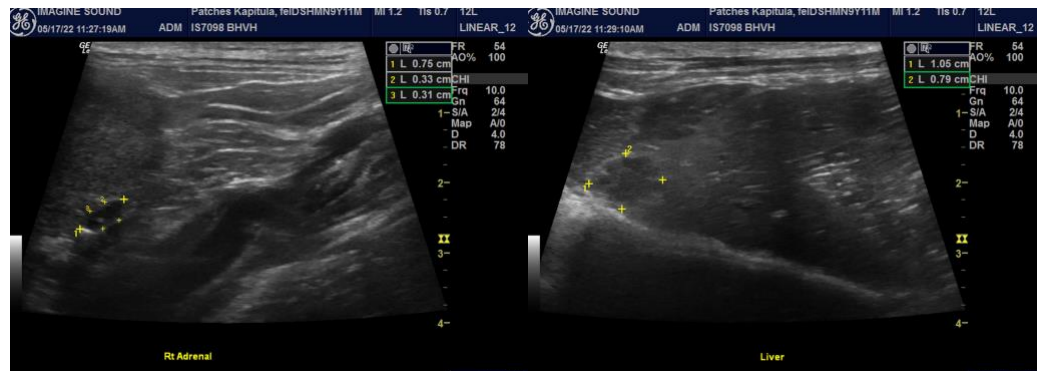Dr. Thomson

INVOICE

37702

DATE

5/17/22

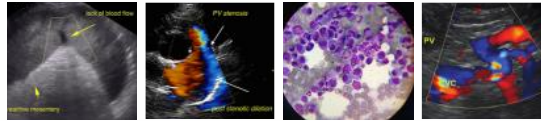


The information and recommendations provided are based on the images presented by the referring veterinarian/sonographer. No evaluation can be communicated regarding pathology that was not visible in the image/video clips provided.

Thank you for this referral. If the clinical or image interpretation does not parallel your findings or if I can be of any further assistance please contact me.

Eric Lindquist, DMV, DABVP, Cert. IVUSS, CEO of SonoPath.com

info@SonoPath.com



PATIENT

Patches Kapitula

SPECIES

Feline

BREED

DSH

SEX

Neutered Male

AGE

9 Years 11 Months

WEIGHT

9.88 Pounds

INTERPRETED BY

Eric Lindquist, DMV
DABVP, Cert IVUSS

**IMAGING
PERFORMED BY**

Denise Bruno, LVT,
RDMS

HOSPITAL NAME

Brooklyn Heights VH

REFERRING VET

Dr. Thomson

INVOICE

37702

DATE

5/17/22

Feline Hypercalcemia

<http://www.sonopath.com/FelineHypercalcemia>

Description: Feline hypercalcemia can be a frustrating diagnosis for practitioner and concerned cat owner alike. When making a diagnosis of hypercalcemia, it is important to consider the physiology of calcium homeostasis. Calcium levels measured using standard chemistry profiles represent the total serum calcium, which is comprised of: i) calcium bound to proteins complexed with anions, such as citrate and phosphate, and ii) ionized or “free” calcium, which is the metabolically active form of the element. The total calcium level *should not*, however, be used to make a diagnosis of hypercalcemia, as it is influenced by the patient’s acid-base status and by various bound proteins, specifically albumin. To this end, the formula used to correct for calcium is based on albumin levels. Only the ionized calcium level can be utilized to arrive at an accurate diagnosis of hypercalcemia.

Causes of Hypercalcemia:

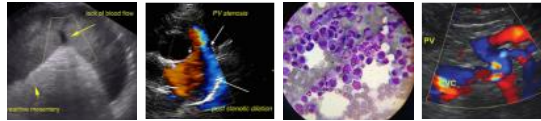
1. Hyperparathyroidism

Benign adenomas of the parathyroid gland create an excess of parathyroid hormone (PTH), which in turn stimulates calcium release from bones and increases renal reabsorption of calcium while promoting phosphorus excretion. A diagnosis can be made by evaluating a paired PTH/ionized calcium sample. Generally, high PTH combined with elevated ionized calcium is indicative of primary hyperparathyroidism; however, one may find that even when ionized calcium is high, PTH levels may still fall within the “normal” range. An inappropriately “high-normal” PTH level, in conjunction with an elevated ionized calcium level, may therefore indicate primary hyperparathyroidism, especially if it is clinically consistent with the signalment (primarily geriatric patients) and clinical findings. In such cases, reevaluation of the panel in 6 weeks is recommended to determine whether the PTH is trending upwards. Sonographic examination of the parathyroid glands can also be performed, as hypertrophy of a single parathyroid or an associated nodule may be discovered. It is common for patients with hyperparathyroidism to also display hypophosphatemia, which may aid in the diagnosis of borderline cases.

2. Renal Disease

It has long been thought that renal failure is a common cause of hypercalcemia, primarily because it increases calcium complexes, which in turn lead to elevated total serum calcium. Yet, ionized calcium frequently remains at normal levels during renal failure, and patients in these circumstances are not truly hypercalcemic. Some cats with renal compromise do display both elevated ionized calcium and PTH (tertiary hyperparathyroidism). Although the mechanism is unclear, it is thought that parathyroid glands affected by chronically elevated calcium levels become autonomous (i.e., they no longer respond to calcium levels). In fact, the elevated level of calcium becomes dependent on excess PTH instead of PTH rising in response to low blood calcium levels. There has been evidence of this in human renal transplant patients who continue to be hypercalcemic after successful transplantation, and is corroborated further by sonographic evaluations that reveal global hypertrophy of the parathyroid glands. These patients also tend to become azotemic and hyperphosphatemic, which is consistent with renal compromise.

3. Hypercalcemia of Malignancy



PATIENT

Patches Kapitula

SPECIES

Feline

BREED

DSH

SEX

Neutered Male

AGE

9 Years 11 Months

WEIGHT

9.88 Pounds

INTERPRETED BY

Eric Lindquist, DMV
DABVP, Cert IVUSS

IMAGING PERFORMED BY

Denise Bruno, LVT,
RDMS

HOSPITAL NAME

Brooklyn Heights VH

REFERRING VET

Dr. Thomson

INVOICE

37702

DATE

5/17/22

A variety of neoplastic conditions are related to hypercalcemia, the most common in cats being lymphoma and squamous cell carcinoma of the head and neck. Other causes include carcinomas originating in other tissues, multiple myeloma, leukemia, and sarcomas (e.g. osteosarcoma and fibrosarcoma). Hypercalcemia of malignancy is caused primarily by systemic humoral factor stimulation, which further incites osteoclastic activity. The most important factor is a fetal protein called PTH related protein (PTHrp). This protein acts like PTH and can be detected in the serum. It should be noted that although a positive result indicates hypercalcemia of malignancy, a negative result does not rule it out. Moreover, hematopoietic bone neoplasms, such as multiple myeloma or leukemia, or primary or metastatic bone tumors, can cause local osteolytic effects. In multiple myeloma, plasma cells also secrete an osteoclastic activation factor. Further diagnostics should include, at a minimum, a thorough physical examination, abdominal ultrasound, and thoracic radiographs. A tissue biopsy or aspirate, or a bone marrow evaluation may also be necessary. Skeletal radiographs or bone scans may also be required to help diagnose bone or hematopoietic neoplasia. Interestingly, hypercalcemia related to lymphoma often resolves abruptly with chemotherapy. Hypercalcemia related to carcinoma (if inoperable) and other neoplasms may be managed by glucocorticoid therapy and fluid administration as well as bisphosphonates.

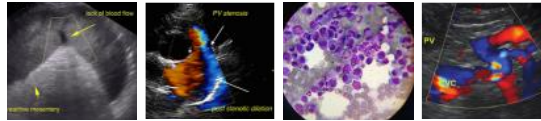
4. Idiopathic Hypercalcemia

Also called "benign hypercalcemia," idiopathic hypercalcemia frustrates veterinarians and cat owners alike. It refers to a condition where the total calcium is mildly to moderately elevated (usually < 15mg/dl) and ionized calcium is high, yet no cause can be identified. PTH is normal or low, and PTHrp is not detectable. Some patients display no obvious clinical signs, while others present with nonspecific clinical signs, including weight loss, anorexia, vomiting, and constipation. In addition, signs associated with calcium urolithiasis (i.e., dysuria, stranguria, hematuria, abdominal pain) may exist as these patients are predisposed secondarily to increased calciuresis. Note that this diagnosis can be made only after all other potential causes of hypercalcemia have been ruled out.

5. Less Common Causes of Hypercalcemia

Vitamin D toxicity needs to be ruled out and a thorough evaluation of the patient's history should be obtained to determine whether accidental ingestion might have occurred. Vitamin D levels can also be evaluated in the serum. Granulomatous diseases, particularly fungal infections, can also lead to a hypercalcemic state and osteolytic lesions, depending on the site of infection. Elevated globulin levels may be seen and fungal serology should be evaluated.

Treatment: Treatment is indicated if calcium is chronically elevated (> 13 mg/dl), patients display clinical signs or calcium urolithiasis, or there are signs of renal failure. Patients in renal failure require diuresis and should undergo monitoring of their calcium blood level. It should be noted that diuretics that increase calciuresis may incite urolithiasis and should be avoided. Other effective treatments that may help include diet change and pharmaceutical intervention. Typically, alkalinizing diets are lower in calcium and phosphorus, help raise the pH, which may correct hypercalcemia, and decrease calciuresis, thereby diminishing the likelihood of calcium oxalate stone formation. High fiber diets may help decrease calcium absorption from the intestine; however, the nutrient content should be evaluated thoroughly as some of these diets may contain elevated levels of calcium and phosphorus. Renal diets are less acidifying and lower in calcium and phosphorus; however, they are also lower in protein, which is not ideal for most cats, and diminished phosphorus may stimulate calcitriol production. Homemade calcium-restricted diets and low carbohydrate/high protein diets may also be helpful in managing hypercalcemia. Ideally, wet food should be administered as it helps to reduce urine concentration and diminish the formation of calcium-based uroliths.



PATIENT

Patches Kapitula

SPECIES

Feline

BREED

DSH

SEX

Neutered Male

AGE

9 Years 11 Months

WEIGHT

9.88 Pounds

INTERPRETED BY

Eric Lindquist, DMV
DABVP, Cert IVUSS

IMAGING PERFORMED BY

Denise Bruno, LVT,
RDMS

HOSPITAL NAME

Brooklyn Heights VH

REFERRING VET

Dr. Thomson

INVOICE

37702

DATE

5/17/22

Glucocorticoids aid in decreasing intestinal calcium absorption but may increase renal excretion; monitoring the development of uroliths is therefore indicated. Glucocorticoids have been shown to decrease ionized calcium levels, yet high dosages appear to be necessary (1-2 mg/kg/day). In general, the owner should be prepared to repeat diagnostics (i.e., blood work, ultrasound, radiographs) to evaluate for emerging neoplasia, especially if the patient displays continued or worsening clinical signs. If the patient is nonresponsive, then alendronate (Fosamax) should be given at 10 mg/cat once a week and can be up-titrated to 30 mg/cat/week if necessary. Bisphosphonates act by inhibiting osteoclastic bone reabsorption through the obstruction of enzymatic pathways. These have been shown to be useful in both reducing hypercalcemia and potentially inhibiting tumor angiogenesis. (Note: Oral bisphosphonates can result in esophageal damage and strictures in people.) Give 5-6 ml of water following the administration of a pill as a preventative; alternatively, injectable forms can be utilized.

One can follow an algorithm-based approach to diagnosing hypercalcemic cats based on serum phosphorus levels:

↑PO₄ → Renal Failure → evaluate renal enzymes, urinalysis, blood pressure
Vitamin D Toxicity → evaluate serum vitamin D concentration and history
Osteolytic Disease → thorough physical examination, skeletal radiographs,

+/- fungal serology

↓PO₄ → Hyperparathyroidism → evaluate PTH level and ionized calcium; ultrasound of parathyroid glands

Malignancy → thorough physical examination, abdominal ultrasound, thoracic radiographs, PTHrp, and ionized calcium +/- tissue biopsy/aspirate or bone marrow evaluation

References:

Audrey K and Cook AK. Cats & calcium: the causes & consequences of hypercalcemia. Proceedings from the American College of Veterinary Internal Medicine and Canadian Veterinary Medical Association, Montreal, QC, June 3-6, 2009.

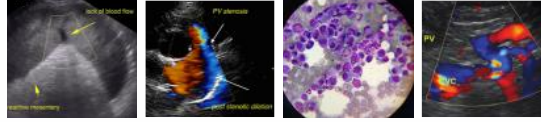
Chew D, Carothers M. Hypercalcemia. *Vet Clin North Am Small Pract* 1989;2:265-87.

Chew DJ, Schenck PA, Jaeger JQ. Clinical disorders of hypercalcemia and hypocalcemia in dogs and cats.

Proceedings from the American College of Veterinary Internal Medicine, Charlotte, NC, June 4-7, 2003.

Hostutler RA, Chew DJ, Jaeger JQ, et al. Uses and effectiveness of pamidronate disodium for treatment of dogs and cats with hypercalcemia. *J Vet Intern Med* 2005;19(1):29-33.

Midcliff A, Chew D, Randolph J, et al. Idiopathic hypercalcemia in cats. *J Vet Intern Med* 2000;6:619-26.



PATIENT

Patches Kapitula

Peterson ME. Hypercalcemia in dogs & cats: differential diagnosis & treatment. Proceedings from the Western Veterinary Conference, Las Vegas, NV, February 19-23, 2012.

SPECIES

Feline

Peterson ME. Pitfalls in the management of idiopathic hypercalcemia in cats. Proceedings from the American College of Veterinary Internal Medicine, Seattle, WA, June 11-15, 2013.

BREED

DSH

Savary KC, Price GS, Vaden SL. Hypercalcemia in cats: a retrospective study of 71 cases (1991-1997) *J Vet Intern Med* 2000;14(2):184-89.

SEX

Neutered Male

Whitney JL, Barrs VR, Wilkinson MR, et al. Use of bisphosphonates to treat severe idiopathic hypercalcaemia in a young Ragdoll cat. *J Feline Med Surg* 2011;13(2):129-34.

AGE

9 Years 11 Months

WEIGHT

9.88 Pounds

INTERPRETED BY

Eric Lindquist, DMV
DABVP, Cert IVUSS

IMAGING PERFORMED BY

Denise Bruno, LVT,
RDMS

HOSPITAL NAME

Brooklyn Heights VH

REFERRING VET

Dr. Thomson

INVOICE

37702

DATE

5/17/22