



**PATIENT**

Nellie Dilling

**SPECIES**

Canine

**BREED**

Beagle

**SEX**

Spayed Female

**AGE**

11 ½ years

**WEIGHT**

12.5 kg

**INTERPRETED BY**

Eric Lindquist, DMV  
DABVP, Cert. IVUSS

**IMAGING PERFORMED BY**

Dr. deCordon

**HOSPITAL NAME**

Mason Dixon AH

**REFERRING VET**

Dr. deCordon

**INVOICE**

30420

**DATE**

5/17/22

**PRESENTING CLINICAL SIGNS**

History: Presented for lethargy and not eating for one day. Abdomen seemed painful on presentation.

Abnormal PE/Chem/CBC/UA Results: Abnormal CPL test. Chemistry and Electrolytes within normal limits.

**ULTRASONOGRAPHIC EXAMINATION OF THE ABDOMEN**

**Urinary System**

The **urinary bladder**, trigone, and pelvic urethra presented normal thicknesses and normal tone. The ureters were not visible which is normal. No uroliths or sediment were visualized and anechoic urine was present. No evidence of inflammatory or neoplastic changes was noted. Ureteral papillae were normal.

The **kidneys** revealed largely normal size and structure, corticomedullary definition and ratio (cortex 1/3 of medulla) were essentially maintained with some age-related loss of curvilinear patterns regarding the capsule and C/M junction. The cortices presented largely uniform texture with some increased echogenicity expected for this age patient. Medullary structure differed distinctly from that of the cortex and no evidence of pelvic dilation was present. The right kidney measured 5.28 cm with trace pyelectasia. The left kidney measured 5.36 cm.

**Adrenal Glands**

The left **adrenal gland** was isoechoic and slightly subnormal in width measuring 1.22 x 0.25 cm. The region of the right adrenal gland revealed no evidence of pathology.

**Spleen**

The **spleen** presented a smooth homogeneous parenchyma hyperechoic to liver and renal cortical parenchyma. The capsule was smooth without noticeable expansion or deviation from within the spleen or adjacent pathology. The splenic vasculature demonstrated normal volume without signs of congestion or thrombosis. No sonographic evidence of acute or chronic inflammatory, neoplastic, or infarctual changes was noted.

**Liver**

The **liver** images submitted revealed subjectively normal liver size, contour, and structure. Parenchymal echogenicity was naturally coarse and hypoechoic to the spleen. Vascular and biliary tracts were of normal volume with no evidence of congestion. The gallbladder presented acceptably thin walls with primarily anechoic content. The cystic and common bile ducts were normal. No pathological hepatic lymphadenopathy was evident. No overt structural evidence of inflammatory, infiltrative or regenerative pathology was evident.



**PATIENT**

**Gastrointestinal**

Nellie Dilling

Examination of the **gastrointestinal tract** revealed a stomach and intestine free of stasis, of normal wall thickness, acceptable curvilinear mural detail, and peristaltic activity. Small and large intestine demonstrated normal luminal chyme and stool consistency respectively. The colon was mildly thickened, yet there was no loss of detail. No obstructive or overt infiltrative disease was noted. No associated abnormal lymphatic activity was noted.

**SPECIES**

Canine

**BREED**

Beagle

**Pancreas**

The base and limbs of the **pancreas** were observed to be largely isoechoic to surrounding omental fat. Some parenchymal remodeling, however, with mild deviation from curvilinear normalcy was observed. Pancreatic duct and capsular irregularities were present consistent with age related changes. If pain upon imaging (+ Murphy sign) was present or if the patient is focally painful in subxiphoid palpation then low-grade smoldering chronic pancreatitis should be suspected.

**SEX**

Spayed Female

**AGE**

11 ½ years

**ULTRASONOGRAPHIC FINDINGS**

Structurally unremarkable abdomen with minor colonic thickening.

**WEIGHT**

12.5 kg

**INTERPRETATION OF THE FINDINGS & FURTHER RECOMMENDATIONS**

There was no overt evidence of disease in the abdomen that would be responsible for the clinical signs. Other causes of anorexia/lethargy such as orthopedic pain, CNS disease and thoracic disease should be considered. Screening for Addison's would be appropriate with baseline cortisol as the adrenal gland was not overtly visible and the left adrenal gland was subjectively subnormal in width. Some level of low-grade gastritis, pancreatitis may be present in this patient, yet was structurally unremarkable.

**INTERPRETED BY**

Eric Lindquist, DMV  
DABVP, Cert. IVUSS

**IMAGING PERFORMED BY**

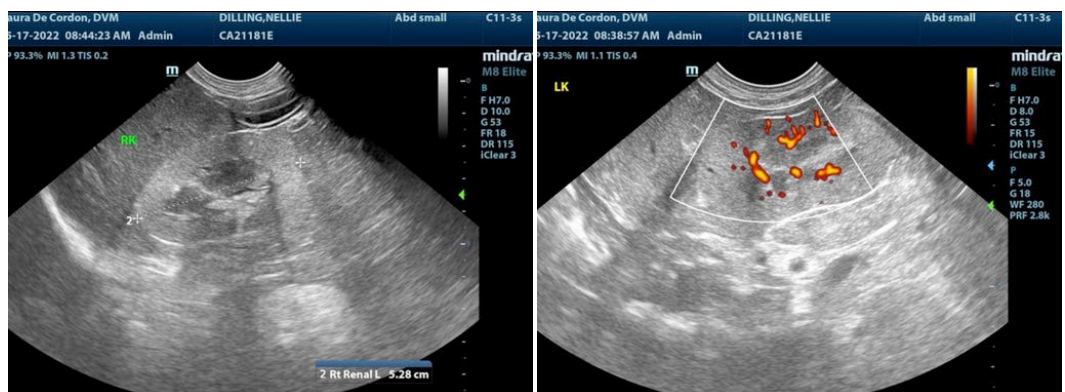
Dr. deCordon

**HOSPITAL NAME**

Mason Dixon AH

**REFERRING VET**

Dr. deCordon



**INVOICE**

30420

**DATE**

5/17/22



**PATIENT**

Nellie Dilling

**SPECIES**

Canine

**BREED**

Beagle

**SEX**

Spayed Female

**AGE**

11 ½ years

**WEIGHT**

12.5 kg

**INTERPRETED BY**

Eric Lindquist, DMV  
DABVP, Cert. IVUSS

**IMAGING PERFORMED BY**

Dr. deCordon

**HOSPITAL NAME**

Mason Dixon AH

**REFERRING VET**

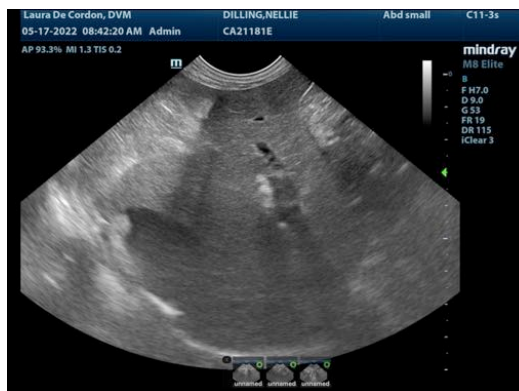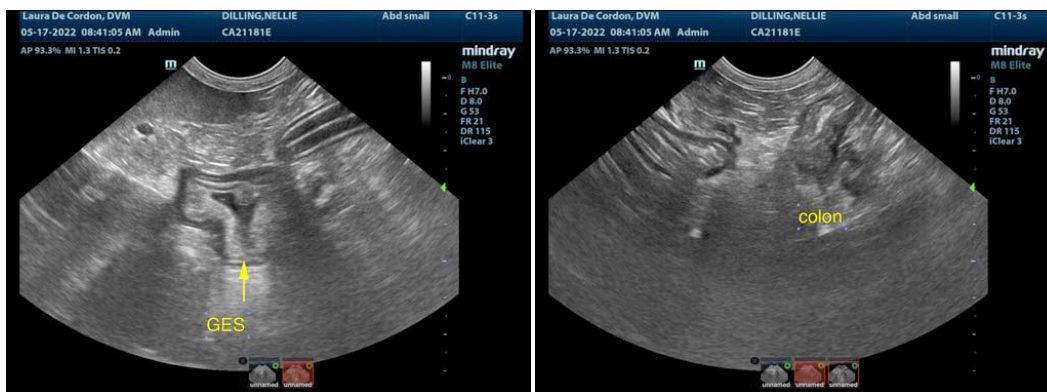
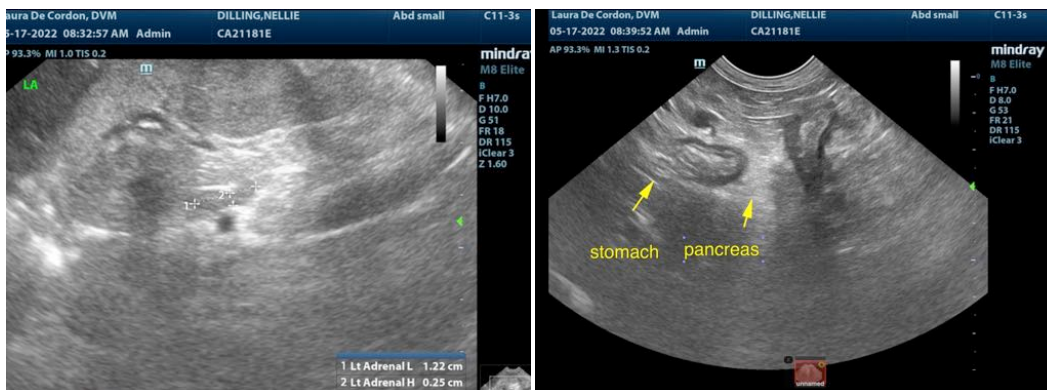Dr. deCordon

**INVOICE**

30420

**DATE**

5/17/22



The information and recommendations provided are based on the images presented by the referring veterinarian/sonographer. No evaluation can be communicated regarding pathology that was not visible in the image/video clips provided.

Thank you for this referral. If the clinical or image interpretation does not parallel your findings or if I can be of any further assistance please contact me.

Eric Lindquist, DMV, DABVP, Cert. IVUSS, CEO of SonoPath.com  
info@SonoPath.com