

**DATE**

5/17/22

PRESENTING CLINICAL SIGNS

Was on vacation in Florida: was normal initially - on the 6th started eating grass and had an episode of vomiting the next day - owner noted that she was in a hunch posture like she was in pain - presented to ER in Florida: xrays had gassy appearance but treated outpatient with famotidine, cerenia, and GI diet - seemed to improve On the 10th: was exhibit the same signs again - presented again to the ER: has circular material in the stomach - did U/S in hospital and noted suspected thickening of the stomach: discussed gastritis vs cancer - discussed attempting treatment for gastritis vs abdominal explore vs barium study - owners opted to treat and came home Not a typical eater of things - did tear up a stuff toy after was seen the first time at the ER Has been eating, drinking, urinating, and defecating normally Last night seemed perkier and less lethargic No vomiting since Saturday Has not eaten since 12a Known sensitive stomach Current meds: - Famotidine - last give 4a - Cerenia - last given 4a.

PATIENT

Kali Wasmer

SPECIES

Canine

BREED

German Shepherd Mix

Current Medications: None listed.
Date of Previous IntraPet Ultrasound: No previous.

Sedation: IV sedation.

Stat Report: Not requested.

Imaging Performed By: Rachel Brillhart, RDMS.

SEX

Spayed Female

ULTRASONOGRAPHIC EXAMINATION OF THE ABDOMEN**Urinary System**

The **urinary bladder**, trigone, and pelvic urethra presented normal thicknesses and normal tone. The ureters were not visible which is normal. No uroliths or sediment were visualized and anechoic urine was present. No evidence of inflammatory or neoplastic changes was noted. Ureteral papillae were normal.

AGE

12/5/14

WEIGHT

44.2 lbs

The **kidneys** revealed normal size and structure, corticomedullary definition and ratio for this age. The cortices presented largely uniform texture with normal echogenic relationship to liver and spleen. Medullary structure differed distinctly from the cortex and no evidence of pelvic dilation was present. The capsules were acceptably uniform without significant irregularities. The right kidney measured 6.21 cm. The left kidney measured 5.94 cm.

INTERPRETED BYEric Lindquist, DMV
DABVP, Cert. IVUSS**Adrenal Glands**

Both **adrenal glands** were visualized and recognized as having normal shape, size, position and echogenicity for this breed. The phrenic vasculature, glandular echogenicity and detail were unremarkable. Capsule, cortex, and medullary definition were normal for this age patient. The right adrenal gland measured 3.02 x 0.73 cm at the caudal pole and 0.82 cm at the cranial pole.

HOSPITAL NAMEAnimal Emergency
Hospital**Spleen**

The **spleen** in this patient was mildly enlarged with uniform parenchyma and was folded upon itself caudally. This is a positional variant and is likely induced by gastric over distension given the gastrosplenic ligament attachment. There was no evidence of significant disease.

REFERRING VET

Dr. Nacke-Horney

INVOICE

30472

Liver

The **liver** images submitted revealed subjectively normal liver size, contour, and structure. Parenchymal echogenicity was naturally coarse and hypoechoic to the spleen. Vascular and biliary tracts were of normal volume with no evidence of congestion. The gallbladder presented acceptably thin walls with primarily anechoic content. The cystic and common bile ducts were normal. No pathological hepatic lymphadenopathy was evident. No overt structural evidence of inflammatory, infiltrative or regenerative pathology was evident.

Gastrointestinal

The **stomach** was filled with shadowing luminal material. This is consistent with fabric type foreign body or similar. The material in the stomach measured 5.67 cm. The small intestine and colon were unremarkable.

Pancreas

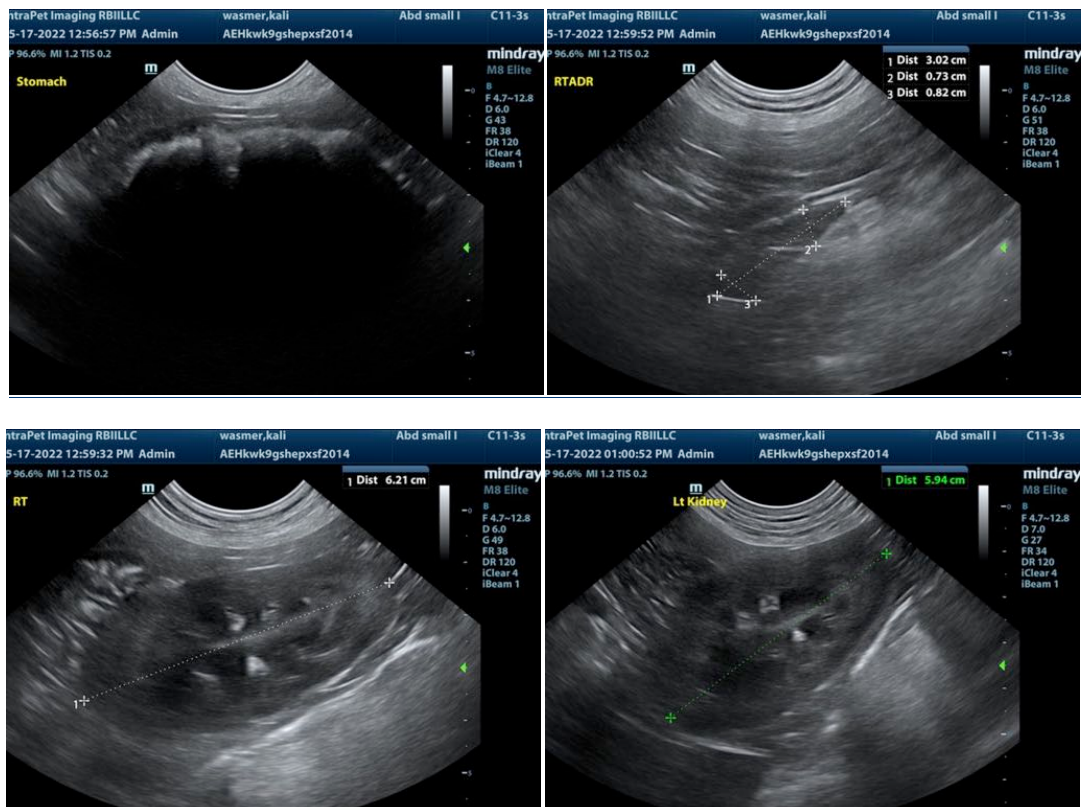
The base and limbs of the **pancreas** were observed to be largely isoechoic to surrounding omental fat. Pancreatic duct and capsular contour were acceptably normal and parenchyma respected normal curvilinear patterns. No overt evidence of active inflammatory or neoplastic disease was noted.

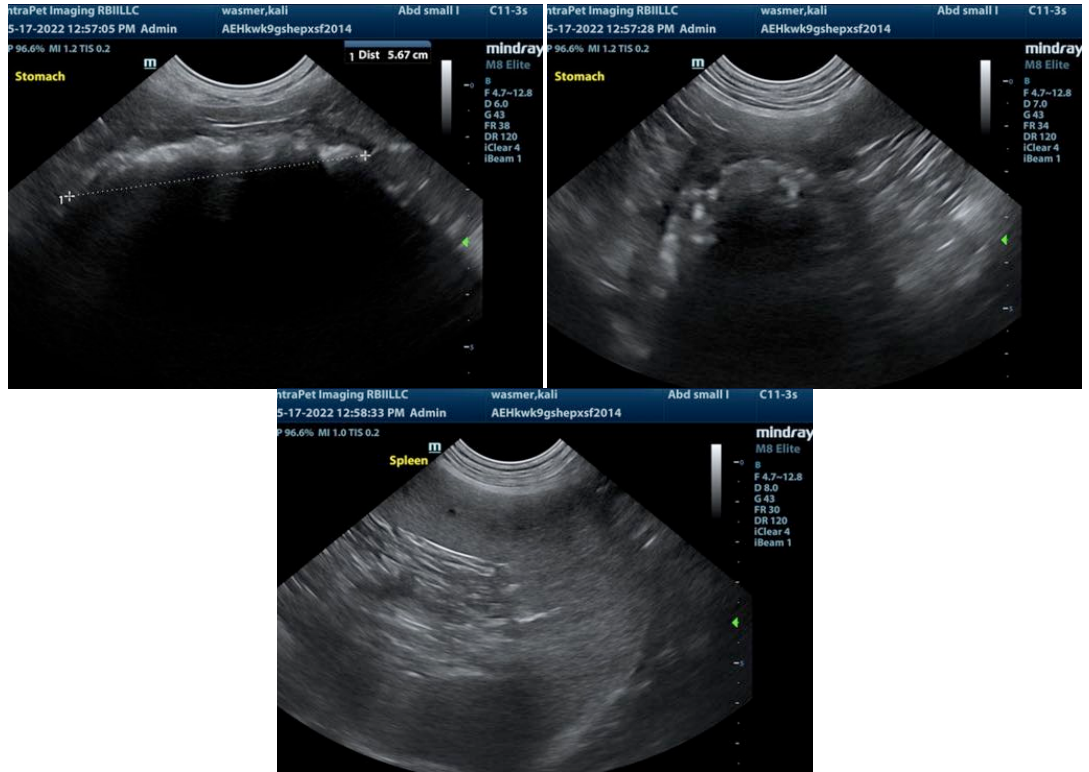
ULTRASONOGRAPHIC FINDINGS

Gastric foreign body.

INTERPRETATION OF THE FINDINGS & FURTHER RECOMMENDATIONS

Gastrotomy and GI biopsies are recommended to rule out underlying disease. According to Sonopath research presented at ECVIM 2016 (Stockholm, Sweden), Advances in Small Animal Medicine and Surgery (May 2017), and EVDI 2017 (Verona, Italy), concurrent underlying chronic inflammatory neoplastic intestinal disease can often reside in PICA patients. Therefore, surgical biopsies are essential in this case regardless of the exploratory findings.





The information and recommendations provided are based on the images presented by the referring veterinarian. No evaluation can be communicated regarding pathology that was not visible in the image/video clips provided.

Thank you for this referral. If the clinical or image interpretation does not parallel your findings or if I can be of any further assistance please contact me.

Eric Lindquist, DMV, DABVP, Cert. IVUSS, CEO of SonoPath.com
Eric.Lindquist@SonoPath.com