



PATIENT

Jack Greenlief

SPECIES

Canine

BREED

Mix

SEX

Neutered Male

AGE

5 Years

WEIGHT

99 Pounds

INTERPRETED BY

Eric Lindquist, DMV

DABVP, Cert. IVUSS

IMAGING PERFORMED BY

Dr. Michelle Bartus

HOSPITAL NAME

Valley Vet Service

REFERRING VET

Dr. Michelle Bartus

INVOICE

37690

DATE

5/17/22

PRESENTING CLINICAL SIGNS

Overweight dog yelped and suddenly pulled up right rear leg while running in the yard. Non weight bearing.

Abnormal PE/Chem/CBC/UA Results: Non weight bearing RH. Increased forward motion (anterior drawer sign) felt once dog was relaxed. Stifle and Pelvic rads WNL.

ULTRASONOGRAPHIC EXAMINATION OF THE RIGHT STIFLE

10 video clips of the right stifle submitted.

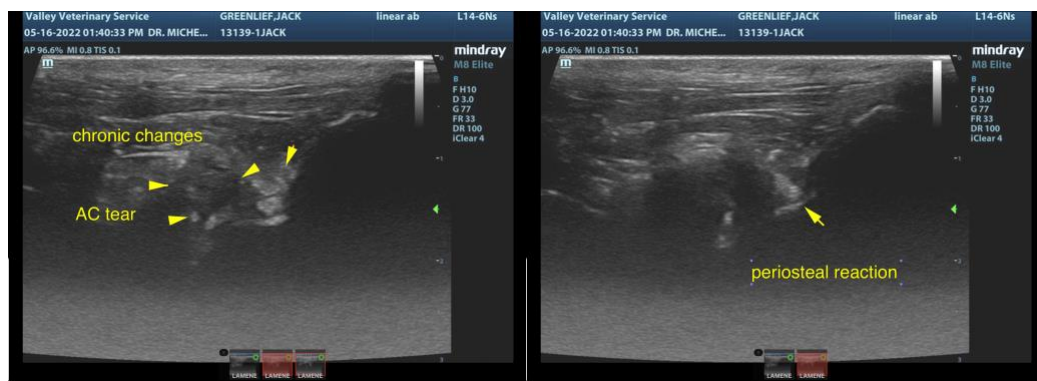
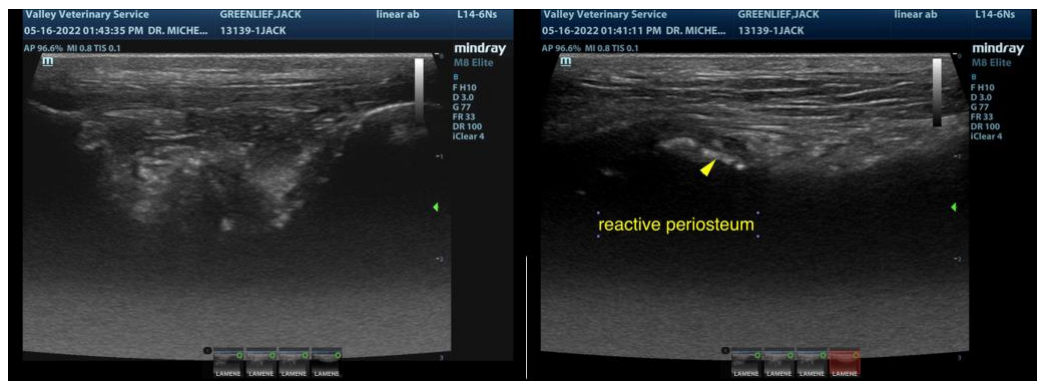The joint revealed multifocal mixed hyperechoic changes, involving intraarticular fat. The area of the cruciate ligament revealed irregular thickening. No intact cruciate ligaments appeared to be present. Multifocal areas of mineralization were present in the region as well as periosteal reactivity and degenerative joint disease. A minimal amount of effusion was noted.

ULTRASONOGRAPHIC FINDINGS

- Chronic degenerative joint disease – likely owing to long-term cruciate tear.

INTERPRETATION OF THE FINDINGS & FURTHER RECOMMENDATIONS

The meniscus was not visible. However, given the degree of degenerative changes within the joint, meniscal tear should be expected. Surgical intervention recommended for stabilization of the joint as well as inspection of the medial meniscus.





PATIENT

Jack Greenlief

The information and recommendations provided are based on the images presented by the referring veterinarian/sonographer. No evaluation can be communicated regarding pathology that was not visible in the image/video clips provided.

SPECIES

Canine

Thank you for this referral. If the clinical or image interpretation does not parallel your findings or if I can be of any further assistance please contact me.

Eric Lindquist, DMV, DABVP, Cert. IVUSS, CEO of SonoPath.com

BREED

Mix

info@SonoPath.com

SEX

Neutered Male

AGE

5 Years

WEIGHT

99 Pounds

INTERPRETED BY

Eric Lindquist, DMV

DABVP, Cert. IVUSS

IMAGING PERFORMED BY

Dr. Michelle Bartus

HOSPITAL NAME

Valley Vet Service

REFERRING VET

Dr. Michelle Bartus

INVOICE

37690

DATE

5/17/22