



PATIENT PRESENTING CLINICAL SIGNS

Chewie Walsh Recheck after medication (4/19/22) Current meds: Vetmedin 1.25mg BID, Enalapril 2.5mg SID (currently), Spironolactone 25mg (1/4 tab BID)

SPECIES ULTRASONOGRAPHIC EXAMINATION OF THE HEART

Canine

BREED

Mix

SEX

Neutered Male

AGE

10 Years

WEIGHT

12.6 Pounds

CANINE CARDIAC PARAMETERS	MR VMAX (m/s)	TR VMAX (m/s)	LA/AO (Boon method)	LA/AO (Heart Base; Swe)	FS (%)	EF (%)	EPSS (cm)
NORMAL PARAMETER	4.5-5.5	<2.7	1.3	<1.6	28-40	40-100	<0.6
PATIENT	6.28	3.55	1.33	1.43	46	78	0.1
CANINE CARDIAC PARAMETERS	HR (BPM)	AV VMAX (m/s)	PV MAX (m/s)	BODY WEIGHT (kg)	LA 2D short axis Base view (cm)	LVIDd Avg; 2D and m-mode short axis (cm)	LVIDs Avg; 2D and m-mode short axis (cm)
NORMAL PARAMETER	50-100	0.7-1.7	0.7-1.6	BELOW	BELOW	BELOW	BELOW
PATIENT	180	1.24			3.4	3.14	

Cardiac Presentation

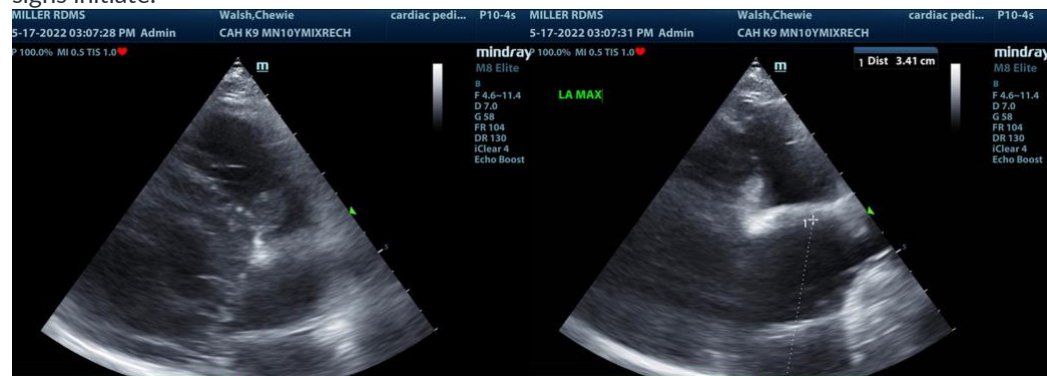
The cardiac presentation revealed slight persistent volume overload of the left atrium. However, left ventricular internal diameter and contractility appeared to be stable. No pericardial or pleural effusion noted. Mild to moderate tricuspid insufficiency present. Complete filling of the left atrium noted on color flow assessment of the mitral valve.

ULTRASONOGRAPHIC FINDINGS

- Fairly stable valve disease on current protocol

INTERPRETATION OF THE FINDINGS & FURTHER RECOMMENDATIONS

As long as the patient is not clinical and systolic pressure is <160, no adjustment in medications recommended at this time. Recheck echo in 6 months, earlier if murmur grade increases or clinical signs initiate.



INTERPRETED BY

Eric Lindquist, DMV
DABVP, Cert. IVUSS

IMAGING PERFORMED BY

Jessica Miller

HOSPITAL NAME

Companion AH

REFERRING VET

Dr. Tsai

INVOICE

37685

DATE

5/17/22



PATIENT

Chewie Walsh

SPECIES

Canine

BREED

Mix

SEX

Neutered Male

AGE

10 Years

WEIGHT

12.6 Pounds

INTERPRETED BY

Eric Lindquist, DMV
DABVP, Cert. IVUSS

IMAGING PERFORMED BY

Jessica Miller

HOSPITAL NAME

Companion AH

REFERRING VET

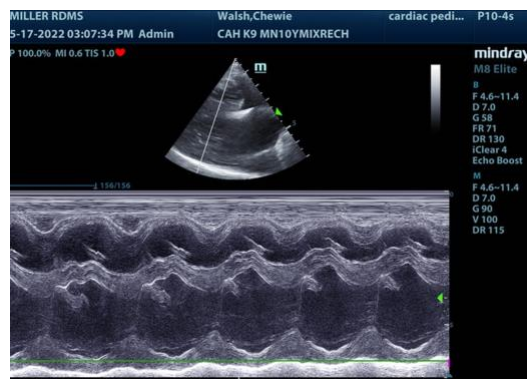
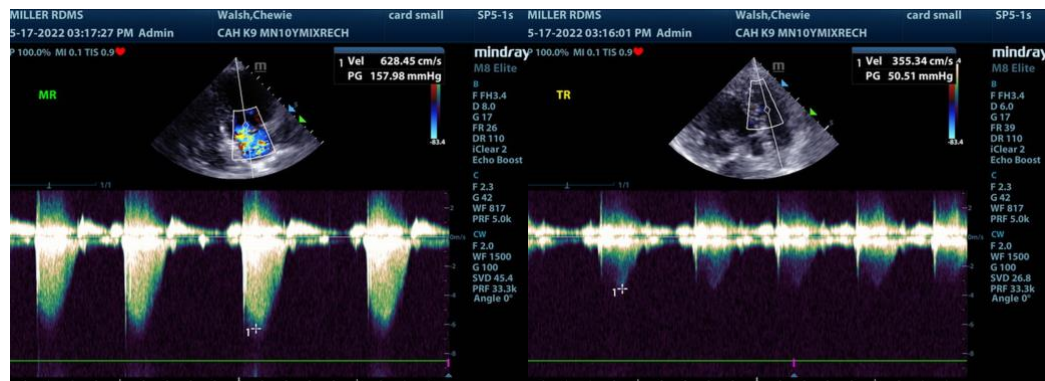
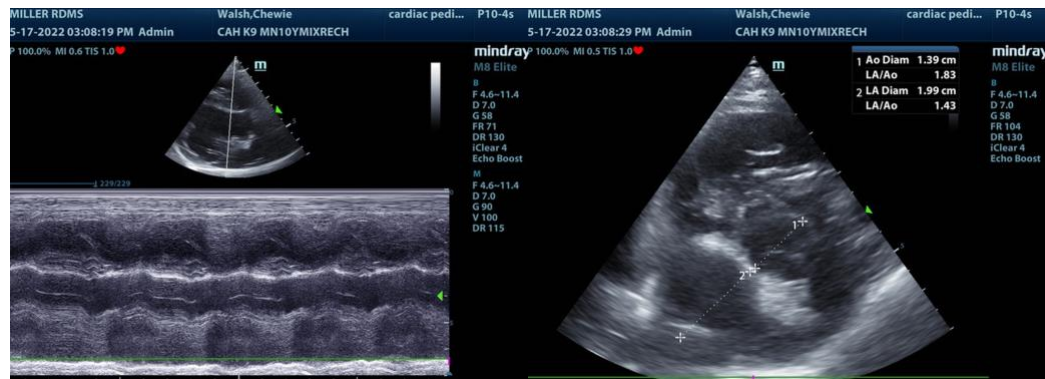
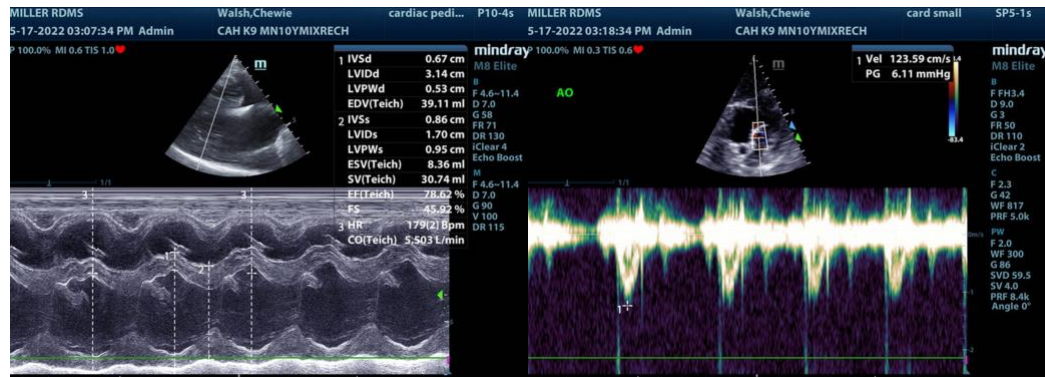
Dr. Tsai

INVOICE

37685

DATE

5/17/22





PATIENT

Chewie Walsh

The information and recommendations provided are based on the images presented by the referring veterinarian/sonographer. No evaluation can be communicated regarding pathology that was not visible in the image/video clips provided.

SPECIES

Canine

Thank you for this referral. If the clinical or image interpretation does not parallel your findings or if I can be of any further assistance please contact me.

Eric Lindquist, DMV, DABVP, Cert. IVUSS, CEO of SonoPath.com

info@SonoPath.com

BREED

Mix

SEX

Neutered Male

AGE

10 Years

WEIGHT

12.6 Pounds

INTERPRETED BY

Eric Lindquist, DMV

DABVP, Cert. IVUSS

IMAGING PERFORMED BY

Jessica Miller

HOSPITAL NAME

Companion AH

REFERRING VET

Dr. Tsai

INVOICE

37685

DATE

5/17/22