



**PATIENT**

Porter Massey

**PRESENTING CLINICAL SIGNS**

History: Weight loss, intermit vomiting  
Abnormal PE/Chem/CBC/UA Results: Elevated lipase >6000 otherwise WNL

**SPECIES**

Feline

**ULTRASONOGRAPHIC EXAMINATION OF THE ABDOMEN**

**Urinary System**

**BREED**

Domestic Longhair

The **urinary bladder**, trigone, and pelvic urethra presented normal thicknesses and normal tone. The ureters were not visible which is normal. No uroliths or sediment were visualized and anechoic urine was present. No evidence of inflammatory or neoplastic changes was noted. Ureteral papillae were normal.

**SEX**

Neutered male

The **kidneys** presented a relatively uniform cortical hyperechogenicity when compared to the renal medulla, spleen and liver. No overt masses were noted. Corticomedullary definition was nebulous and the ratio favored the cortex slightly. The ureters were not visible and assumed to be normal. These changes are most consistent with chronic interstitial nephritis yet infiltrative disease could not be entirely ruled out without biopsy though neoplasia is not suspected. The right kidney measured 3.28 cm.

**AGE**

14 years

**WEIGHT**

8.2 lbs

**Adrenal Glands**

Both **adrenal glands** were visualized and recognized as having normal shape, size, position and echogenicity for this breed. The phrenic vasculature, glandular echogenicity and detail were unremarkable. Capsule, cortex, and medullary definition were normal for this age patient. The left adrenal gland measured 0.44 cm. The right adrenal gland measured 0.41 cm.

**INTERPRETED BY**

Eric Lindquist, DMV  
DABVP, Cert. IVUSS

**Spleen**

**IMAGING PERFORMED BY**

Dr. Rodriguez

The **spleen** presented a smooth homogeneous parenchyma hyperechoic to liver and renal cortical parenchyma. The capsule was smooth without noticeable expansion or deviation from within the spleen or adjacent pathology. The splenic vasculature demonstrated normal volume without signs of congestion or thrombosis. No sonographic evidence of acute or chronic inflammatory, neoplastic, or infarctual changes was noted.

**HOSPITAL NAME**

Foxfield VS

**Liver**

**REFERRING VET**

Dr. Rodriguez

The **liver** images submitted revealed subjectively normal liver size, contour, and structure. Parenchymal echogenicity was naturally coarse and hypoechoic to the spleen. Vascular and biliary tracts were of normal volume with no evidence of congestion. The gallbladder presented acceptably thin walls with primarily anechoic content. The cystic and common bile ducts were normal. No pathological hepatic lymphadenopathy was evident. No overt structural evidence of inflammatory, infiltrative or regenerative pathology was evident.

**INVOICE**

30407

**DATE**

5/17/22

**Gastrointestinal**



**PATIENT**

Porter Massey

The **gastrointestinal** presentation revealed mild uniform prominence of the gastric mucosa as well as areas of "ropey" small intestinal wall with slight disruption of the normal 1:3 muscularis/mucosal ratio. The intestinal submucosa was slightly irregular, thickened and hyperechoic suggestive of low grade, chronic disease. The mesenteric lymph nodes were reactive and measured 0.8 x 0.3 cm.

**SPECIES**

Feline

**Pancreas**

The **pancreas** revealed hypoechoic, undulating contour, primarily in the right limb.

**BREED**

Domestic Longhair

**Free Abdomen**

Mild, enhanced mesentery was noted around the pancreas.

**SEX**

Neutered male

**ULTRASONOGRAPHIC FINDINGS**

Inflammatory bowel/pancreatitis pattern with moderate chronic degenerative renal changes.

**AGE**

14 years

Reactive mesenteric lymph nodes.

Interstitial nephrosis.

**WEIGHT**

8.2 lbs

**INTERPRETATION OF THE FINDINGS & FURTHER RECOMMENDATIONS**

There was no evidence of foreign bodies or overt neoplastic criteria. Supportive care should prove effective. A clinical trial of the following may prove effective.

**INTERPRETED BY**

Eric Lindquist, DMV  
DABVP, Cert. IVUSS

**Triaditis/Pancreatitis protocol**

Part or all of this protocol may be considered based on your clinical impression of the patient:

**IMAGING PERFORMED BY**

Dr. Rodriguez

Recommend pain management when anorexic with **Buprenorphine** (0.01-0.02 mg/kg IM or SC), clinical trial of **Zithromax** (50 mg sid/cat x 10 days, 3 weeks if bartonella +), **Prednisolone** (0.5-2 mg/kg tapering over 1 week to minimal effective dose), and **B12 injections** if weight loss (Cyanobalamine 250 mcg sub-q once-weekly x six weeks, then every other week for six weeks and then once-monthly, long-term if necessary), **novel-protein or hydrolyzed diet** (*Hydrolyzed diets have been shown to be more effective in dietary intolerance case management compared to hypoallergenic diets*) or the **magical Purina DM** (changing protein source is crucial and may need rotation every 6 months if clinical signs recur) Diet trials is a whatever works phenomenon. If vomiting becomes a persistent issue then endoscopy would be warranted and/or recheck sonogram to assess more emerging disease. One diet does not work for all patients so different trials may be necessary or protein source rotation every 6 months as new sensitivities develop.

**HOSPITAL NAME**

Foxfield VS

**REFERRING VET**

Dr. Rodriguez

**INVOICE**

30407

**DATE**

5/17/22



**PATIENT**

Porter Massey

**SPECIES**

Feline

**BREED**

Domestic Longhair

**SEX**

Neutered male

**AGE**

14 years

**WEIGHT**

8.2 lbs

**INTERPRETED BY**

Eric Lindquist, DMV  
DABVP, Cert. IVUSS

**IMAGING PERFORMED BY**

Dr. Rodriguez

**HOSPITAL NAME**

Foxfield VS

**REFERRING VET**

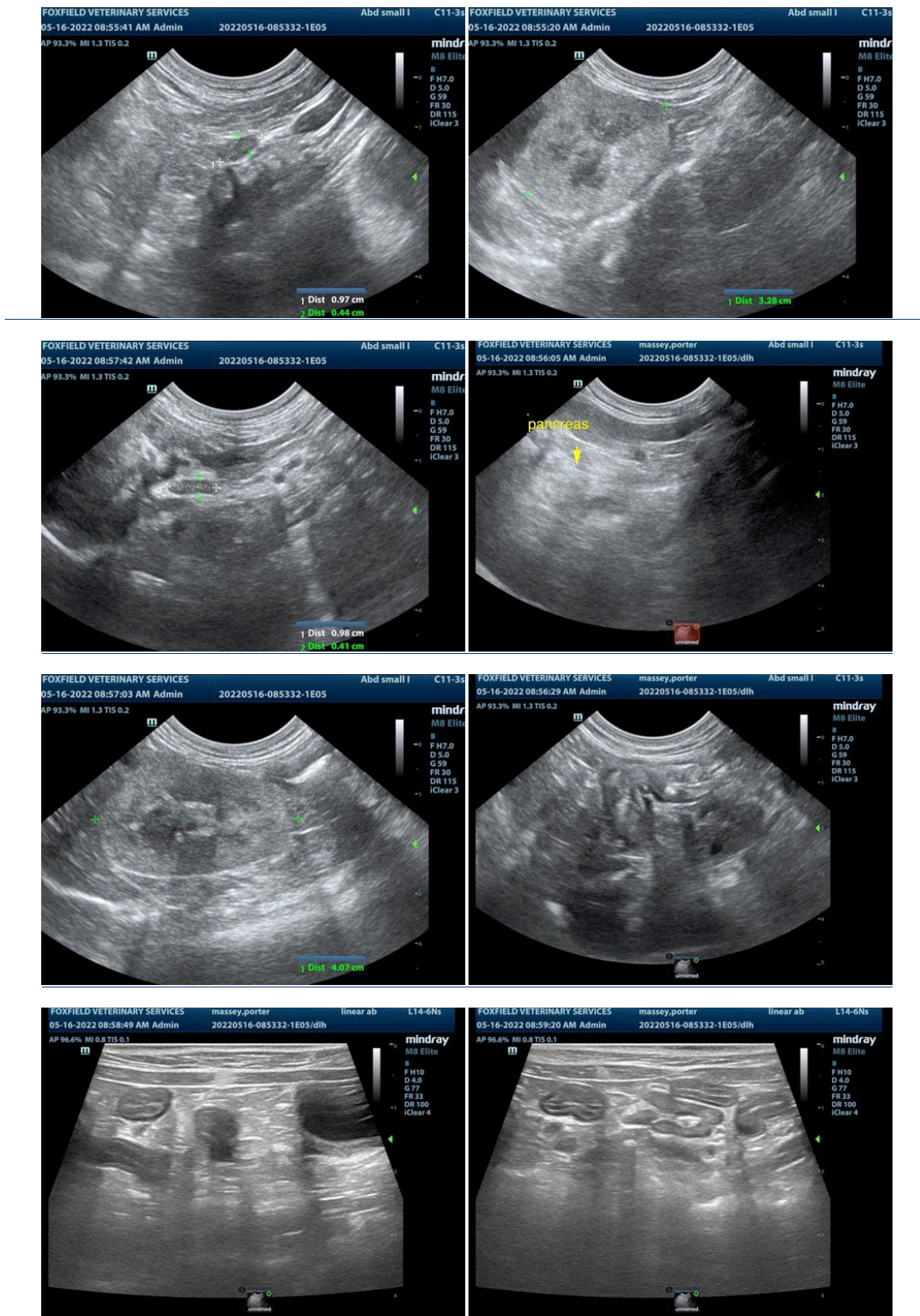
Dr. Rodriguez

**INVOICE**

30407

**DATE**

5/17/22





**PATIENT**

Porter Massey

**SPECIES**

Feline

**BREED**

Domestic Longhair

**SEX**

Neutered male

**AGE**

14 years

**WEIGHT**

8.2 lbs

**INTERPRETED BY**

Eric Lindquist, DMV  
DABVP, Cert. IVUSS

**IMAGING  
PERFORMED BY**

Dr. Rodriguez

**HOSPITAL NAME**

Foxfield VS

**REFERRING VET**

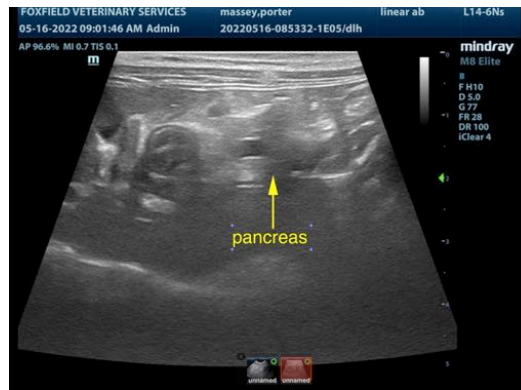
Dr. Rodriguez

**INVOICE**

30407

**DATE**

5/17/22



The information and recommendations provided are based on the images presented by the referring veterinarian/sonographer. No evaluation can be communicated regarding pathology that was not visible in the image/video clips provided.

Thank you for this referral. If the clinical or image interpretation does not parallel your findings or if I can be of any further assistance please contact me.

Eric Lindquist, DMV, DABVP, Cert. IVUSS, CEO of SonoPath.com  
info@SonoPath.com