



PATIENT

Milly Bazen

SPECIES

Canine

BREED

Boston Terrier

SEX

Spayed Female

AGE

6 Years

WEIGHT

11.62 Pounds

INTERPRETED BY

Eric Lindquist, DMV
DABVP, Cert. IVUSS

**IMAGING
PERFORMED BY**

Adrienne Waffle

HOSPITAL NAME

Torch Lake VC

REFERRING VET

Adrienne Waffle

INVOICE

15213

DATE

5/16/22

PRESENTING CLINICAL SIGNS

History: Presented as referral from ER clinic for abdominal ultrasound. Milly has been treated for the past 4 days for suspect pancreatitis. Her BG has decreased from 50-60 initially with no supplementation to now requiring a CRI of dextrose.

Abnormal PE/Chem/CBC/UA Results: Will attach ER records

ULTRASONOGRAPHIC EXAMINATION OF THE ABDOMEN

Urinary System

The **urinary bladder**, trigone, and pelvic urethra presented normal thicknesses and normal tone. The ureters were not visible which is normal. No uroliths or sediment were visualized, and anechoic urine was present. No evidence of inflammatory or neoplastic changes were noted. Ureteral papillae were normal. The pelvic urethra was imaged 1.0 cm beyond the cystourethral junction.

The **kidneys** revealed normal size and structure, corticomedullary definition and ratio for this age. The cortices presented largely uniform texture with normal echogenic relationship to liver and spleen. Medullary structure differed distinctly from the cortex and no evidence of pelvic dilation was present. The capsules were acceptably uniform without significant irregularities. The left kidney measured 4.08 cm. The right kidney measured 5.0 cm.

Adrenal Glands

The **left adrenal gland** was visualized and recognized as having normal shape, size, position and echogenicity for this breed. The phrenic vasculature, glandular echogenicity and detail were unremarkable. Capsule, cortex, and medullary definition were normal for this age patient. The left adrenal gland measured 0.5 cm.

The **right adrenal gland** was not visualized.

Spleen

The **spleen** revealed mild heterogeneous parenchymal changes. A slight hypoechoic nodule was noted in the mid body, measuring 5.0 mm.

Liver

The **liver** was subnormal in size with echogenic portal markings and gallbladder.

Gastrointestinal

Examination of the **gastrointestinal tract** revealed a stomach and intestine free of stasis, of normal wall thickness, acceptable curvilinear mural detail, and peristaltic activity. Small and large intestine demonstrated normal luminal chyme and stool consistency respectively. No obstructive or overt infiltrative disease was noted. No associated abnormal lymphatic activity was noted.

Pancreas

The majority of the **pancreas** was imaged and appeared normal.

ULTRASONOGRAPHIC FINDINGS

- Mild Microhepatica and hepatic remodeling



PATIENT

- Heterogeneous spleen

Milly Bazen

INTERPRETATION OF THE FINDINGS & FURTHER RECOMMENDATIONS

SPECIES

Canine

The pancreas appears structurally unremarkable. Cross reactivity with GI lipase amylase may be an issue. Screening for Addisons warranted in this patient. There is no overt evidence of insulinoma, however, these can be exceedingly small. Insulin/glucose ratio warranted. If no significant proteinuria is present, then GI protein loss is likely. Assessment for history of exposure to xylitol would be warranted. If insulin/glucose ratio is suggestive of insulinoma, then CT with contrast would be warranted, as this is the gold standard diagnostic procedure for insulinoma. However, the majority of the pancreas was imaged and appeared normal.

BREED

Boston Terrier

SEX

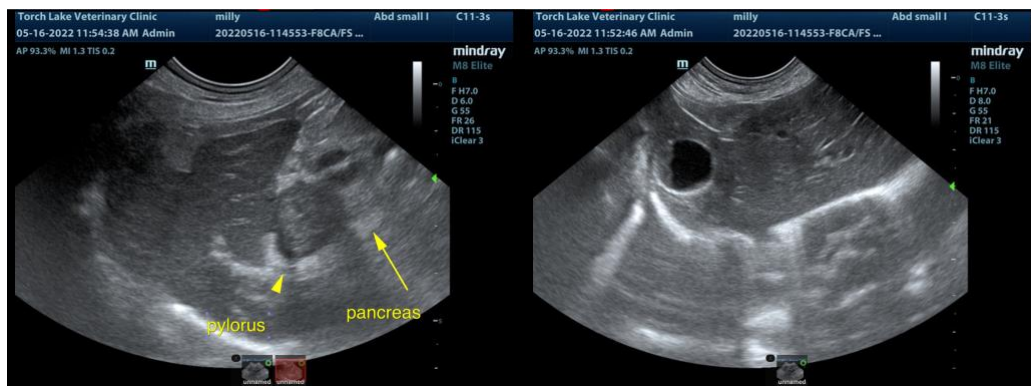
Spayed Female

AGE

6 Years

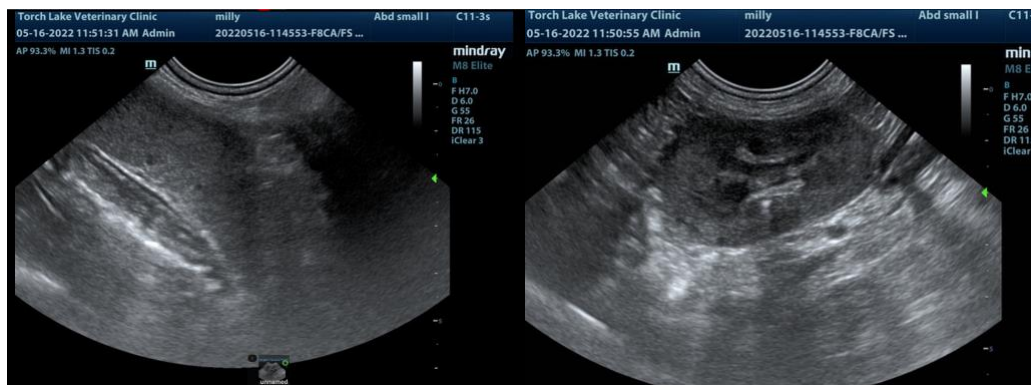
WEIGHT

11.62 Pounds



INTERPRETED BY

Eric Lindquist, DMV
DABVP, Cert. IVUSS



IMAGING PERFORMED BY

Adrienne Waffle

HOSPITAL NAME

Torch Lake VC

The information and recommendations provided are based on the images presented by the referring veterinarian. No evaluation can be communicated regarding pathology that was not visible in the image/video clips provided.

REFERRING VET

Adrienne Waffle

Thank you for this referral. If the clinical or image interpretation does not parallel your findings or if I can be of any further assistance please contact me.

INVOICE

Eric Lindquist, DMV, DABVP, Cert. IVUSS, CEO of SonoPath.com
info@SonoPath.com

15213

DATE

5/16/22



PATIENT

Milly Bazen

The following is an applicable excerpt from the *Curbside Guide to Diagnosis & Treatment of Sonographic Disease* offered by [SonoPath.com](http://www.sonopath.com) Lindquist, Frank, Lobetti, and Modler.


SPECIES

Canine

An essential quick guide for every general practitioner and sonographer.

BREED

Boston Terrier



SEX

Spayed Female

AGE

6 Years

Hypoglycemic Syndrome: Insulinoma and Other

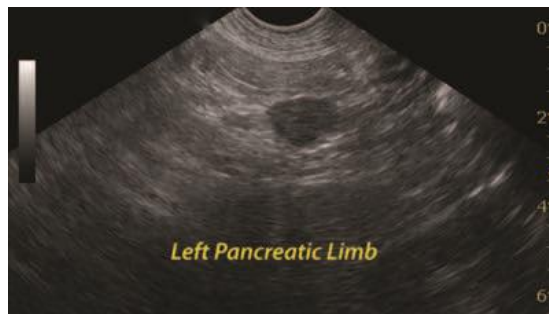
<http://www.sonopath.com/Hypoglycemia>

WEIGHT

11.62 Pounds

INTERPRETED BY

Eric Lindquist, DMV
DABVP, Cert. IVUSS



Short axis of the left pancreatic limb in a dog with an insulinoma seen as an ovoid hypoechoic mass lesion expanding the pancreatic capsule.

IMAGING PERFORMED BY

Adrienne Waffle

HOSPITAL NAME

Torch Lake VC

Description: Hypoglycemia can be found incidentally or associated with non-specific clinical signs, such as listlessness and weakness. It is essential to consider the multiple differentials for hypoglycemia in order to avoid a potential hypoglycemic crisis. One must perform a rapid and efficient workup to arrive at a diagnosis and prescribe the proper therapy.

REFERRING VET

Adrienne Waffle

INVOICE

15213

Differentials for hypoglycemia include: laboratory or handling error; sepsis; toxins (e.g. xylitol, ethylene glycol); hunting dog hypoglycemia; Addison's disease; polycythemia; liver failure; poorly regulated diabetes mellitus; and neoplasia (e.g. leiomyosarcoma, hepatic, lymphoma, and insulinoma).

DATE

5/16/22

Once other causes of hypoglycemia have been ruled out, one may initiate an investigation into the



PATIENT

Milly Bazen

possibility of insulinoma. Insulinoma is a tumor of the pancreas that originates in the beta cells and leads to the unregulated secretion of insulin and hypoglycemic syndrome. The tumor can be a malignant carcinoma or a more benign form of adenoma. There is, however, controversy regarding the exact histopathology associated with insulinoma types.

SPECIES

Canine

Insulinoma patients are usually middle-aged dogs. Half of all cases present with metastasis to the lymph nodes, liver, and mesentery at the time of diagnosis. There are 3 stages of insulinoma:

BREED

Boston Terrier

Stage 1: Pancreatic localization

SEX

Spayed Female

Stage 2: Pancreas and lymph nodes with a median survival time (MST) of 1.5 years

Stage 3: Organ metastasis with an MST of 6 months.

AGE

6 Years

Clinical Signs: Neuroglycopenia syndrome results in lethargy, ataxia, collapse, and seizures. Catecholamine release from hypoglycemia leads to hunger, behavior changes, and muscle tremors. Postprandial exacerbation of clinical signs can occur.

WEIGHT

11.62 Pounds

Diagnostics: When investigating for insulinoma, one should use a fluoride-containing tube (i.e., a grey top tube) to obtain an accurate glucose level. A fasting glucose level below 60 mg/dl is diagnostic for hypoglycemia. Insulinoma is indicated when one observes the Whipple's triad of hypoglycemia, clinical signs consistent are with hypoglycemia, and the latter resolve with the administration of dextrose.

INTERPRETED BY

Eric Lindquist, DMV
DABVP, Cert. IVUSS

Fasting insulin and glucose ratio: A high normal to elevated insulin level with glucose < 60 mg/dl is diagnostic for insulinoma.

IMAGING PERFORMED BY

Adrienne Waffle

Imaging: Localizing the lesion with staging is best approached by ultrasound. The ability to localize the lesion may be highly operator- and/or machine-dependent given the often small or even microscopic nature of insulinoma, especially early on in the disease. Primary or secondary lesions associated with insulinoma can often be identified with higher resolution sonography. Appropriate ultrasound-guided sampling (FNA or core biopsy) can be performed of any enlarged lymph node or hepatic nodule if a primary pancreatic lesion is not seen.

HOSPITAL NAME

Torch Lake VC

REFERRING VET

Adrienne Waffle

INVOICE

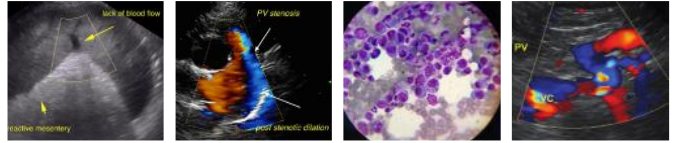
15213

Computed tomography (CT) with contrast is likely more sensitive than the average sonographer when it comes to assessing insulinoma.

DATE

5/16/22

Tumor staging and histopathological characterization in conjunction with the Ki67 biomarker index will yield solid criteria for the prognostic evaluation of insulinoma.



PATIENT

Milly Bazen

Treatment:

SPECIES

Canine

In cases of emergency hypoglycemic crisis, apply corn syrup to the gums. Administer a dextrose bolus (0.5g/kg IV) and maintain 2.5-10% dextrose solution. If cerebral edema occurs, one should administer dexamethasone (2 mg/kg IV) and give mannitol (0.5 mg/kg IV) over a 20-minute period.

BREED

Boston Terrier

One should perform a surgical pancreatectomy if the tumor is localized (i.e., stage 1 insulinoma). Given that the lesion may be difficult to locate with the naked surgical eye or via palpation, the surgical procedure can be enhanced by intraoperative ultrasound.

SEX

Spayed Female

In cases of stage 2 and 3 insulinoma, administer prednisolone (0.25 mg/kg PO BID). A glucagon IV infusion has also been suggested; it should be infused with saline at 5 mg/kg/min for refractory cases. If prednisone is not adequate, one can supplement with benzothiadiazide diazoxide (5 mg/kg PO BID).

AGE

6 Years

Patients should be fed small, frequent portions of a diet high in fat, complex carbohydrates, and protein.

WEIGHT

11.62 Pounds

Chemotherapy: In some cases, the use of alloxan (65 mg/ kg IV) has been shown to be helpful.

INTERPRETED BY

Eric Lindquist, DMV
DABVP, Cert. IVUSS

Conclusion: The largest study of insulinoma patients identified a general MST of 547 days; however, the MST was 785 days for those undergoing pancreatectomy and 1316 days for those that relapsed after surgery and received treatment with prednisone. Other studies have reported an MST of 258 days with pancreatectomy. All of these results indicate that insulinoma is treatable. Using ultrasonography for staging and histopathological characterization is essential in order to determine whether the appropriate treatment should be surgical, medical, or both.

IMAGING PERFORMED BY

Adrienne Waffle

HOSPITAL NAME

Torch Lake VC

REFERRING VET

Adrienne Waffle

INVOICE

15213

DATE

5/16/22



PATIENT

Milly Bazen

SPECIES

Canine

BREED

Boston Terrier

SEX

Spayed Female

AGE

6 Years

WEIGHT

11.62 Pounds

INTERPRETED BY

Eric Lindquist, DMV
DABVP, Cert. IVUSS

IMAGING PERFORMED BY

Adrienne Waffle

HOSPITAL NAME

Torch Lake VC

REFERRING VET

Adrienne Waffle

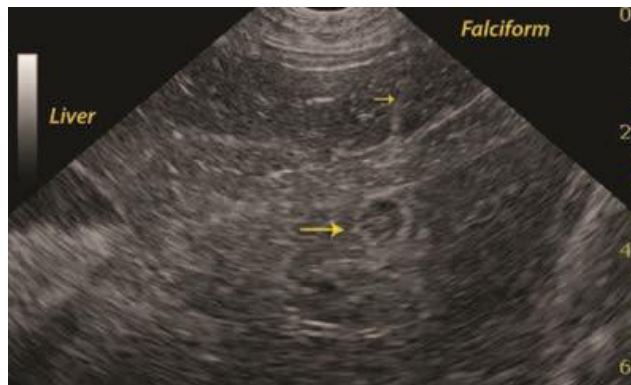
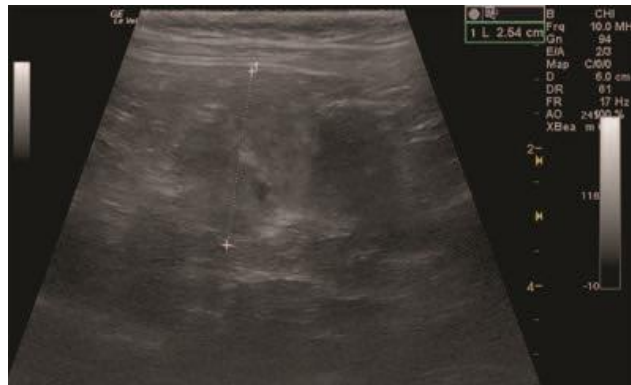INVOICE

15213

DATE

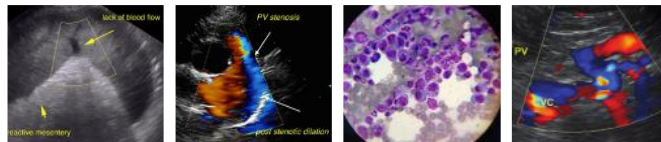
5/16/22

Short axis of the left pancreatic limb in a cat with an insulinoma seen as a complex heterogenous mass lesion expanding the pancreatic capsule (between calipers). Note the mass effect of the tumor displacing the transverse colon caudally.



Subxiphoidal short axis of the liver in a dog with an insulinoma during ultrasound guided sampling of a suspected metastatic lesion.

The needle trajectory is seen as a hyperechoic line (small arrow) approaching the hypoechoic nodule (large arrow) within the liver parenchyma.



PATIENT

Milly Bazen

SPECIES

Canine

BREED

Boston Terrier

SEX

Spayed Female

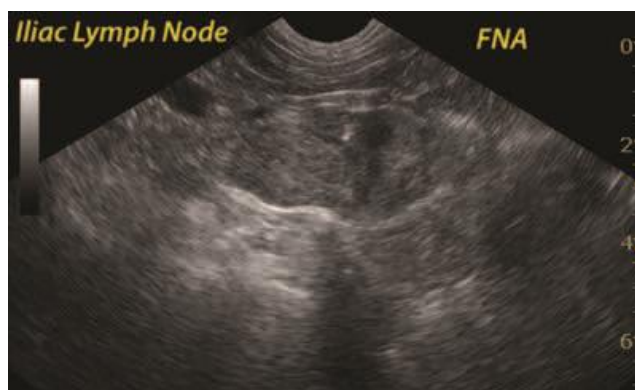
AGE

6 Years

WEIGHT

11.62 Pounds

Long axis of the medial iliac lymph node during ne needle aspiration in a dog with multifocal metastatic spread of an insulinoma. The echogenic needle tip is seen within the lymph node. The metastatic lymph node is enlarged, rounded, hypochoic and heterogenous. The primary metastatic loci in insulinoma are the regional lymph nodes (hepatic, pancreaticoduodenal, gastric) and the liver. Hence, metastatic insulinoma lesions in the iliac lymph node in this case was not a typical occurrence.



INTERPRETED BY

Eric Lindquist, DMV
DABVP, Cert. IVUSS

IMAGING PERFORMED BY

Adrienne Waffle

HOSPITAL NAME

Torch Lake VC

REFERRING VET

Adrienne Waffle

INVOICE

15213

DATE

5/16/22

References:

Buishand FO, Kik M, Kirpensteijn J. Evaluation of clinico-pathological criteria and the Ki67 index as prognostic indicators in canine insulinoma. *Vet J* 2010;185:62-67.

Fischer JR, Smith SA, Harkin KR: Glucagon constant-rate infusion: A novel strategy for management of hyperinsulinemic-hypoglycemia crisis in the dog. *J Am Anim Hosp Assoc* 2000;36:27-32.

Polton GA, White RN, Brearley MJ, et al. Improved survival in a retrospective cohort of 28 dogs with insulinoma. *J Small Anim Pract* 2000;48:151-56.

Steiner JM, Bruyette DS: Canine insulinoma. *Compend Contin Educ Pract Vet* 1996;18:31-36.

Tobin RL, Nelson RW, Lucroy MD, et al. Outcome of surgical versus medical treatment of dogs with beta cell neoplasia: 39 cases (1990-1997). *JAVMA* 1999;215:226-30.