



**PATIENT PRESENTING CLINICAL SIGNS**

Cody Buonadonna History: Newly dx murmur 2/6. Echo prior to dental and GA

**SPECIES ULTRASONOGRAPHIC EXAMINATION OF THE HEART**

Canine

BREED

Australian Shepard

SEX

Neutered male

AGE

10 years

WEIGHT

61.8 lbs

INTERPRETED BY

Eric Lindquist, DMV  
DABVP, Cert. IVUSS

IMAGING PERFORMED BY

Dr. Rodriguez

HOSPITAL NAME

Foxfield VS

REFERRING VET

Dr. Rodriguez

INVOICE

30411

DATE

5/17/22

The echocardiogram in this patient demonstrated normal **left atrial** size based on 3 different LA measurement methods. Chamber volumes and echogenicity were normal. The cranial and caudal **mitral** valve leaflets presented vegetative thickening consistent with endocardiosis. Doppler indicated measurable insufficiency. The **left ventricle** presented thicknesses with linear contour and was not dilated nor restricted. The **myocardium** presented normal echogenicity without subjective evidence of significant fibrotic or ischemic disease. **Contractility** of the ventricular walls was adequate and in normal range for this patient evidenced by the fractional shortening measurement and subjective evaluation of the different regions of the myocardium. The **left ventricular outflow** tract demonstrated normal laminar flow and subjective structural integrity. The **right atrium** and auricle revealed normal size, structure and content. No evidence of masses was noted or chamber overload. **Tricuspid** valvular assessment demonstrated adequate linear morphology. The **right ventricle** was of normal size (1/3 diameter of LV), chordae structure, myocardial echogenicity and thickness. **Pulmonic** tract assessment revealed normal valve structure, laminar flow, and diameter (approx. 1:1 pa/ao ratio). No visible **pericardial** or free pleura fluid was noted. No echographically detectable evidence of infiltrative disease was visible. The cranial **mediastinum** and **pericardial** regions were free of masses in the visible window.

CANINE	MR	TR	LA/AO	LA/AO	FS	EF	EPSS
CARDIAC	VMAX	VMAX	(Boon method)	(Heart Base; Swe)	(%)	(%)	(cm)
PARAMETERS	(m/s)	(m/s)					
NORMAL PARAMETER	4.5-5.5	<2.7	1.3	<1.3	28-40	40-100	<0.6
PATIENT	6.2		1.0	1.4	34	64	0.25
CANINE	HR	AV	PV	BODY WEIGHT	LA	LVIDd	LVIDs
CARDIAC	(BPM)	VMAX	MAX	lbs	2D short axis Base view	Avg; 2D and m-mode short axis	Avg; 2D and m-mode short axis
PARAMETERS		(m/s)	(m/s)		(cm)	(cm)	(cm)
NORMAL PARAMETER	50-100	0.7-1.7	0.7-1.6				
PATIENT	100	1.6		61.8 lbs	4.4	3.1	

**ULTRASONOGRAPHIC FINDINGS**

Stage B1 valvular disease.

MR filling of the left atrium was moderate.

**INTERPRETATION OF THE FINDINGS & FURTHER RECOMMENDATIONS**

There is no overt contraindication to anesthetic procedure.



## PATIENT

Cody Buonadonna

B1: The heart is stable without clinical disease. No overt contraindication for anesthesia of brief to moderate duration. I suggest Torbutrol premed, Propofol induction, Isoflurane maintenance or similar protocol if anesthesia is desired. Blood pressure recommended if not already performed and target white coat negative systolic pressure of < 160 mmHg. If higher than this ACE-inhibitor is suggested to reach this level. Recheck echocardiogram is recommended in 6 months, earlier if murmur grade increases or clinical signs initiate.

## SPECIES

Canine

## BREED

Australian Shepard

## SEX

Neutered male

## AGE

10 years

## WEIGHT

61.8 lbs

## INTERPRETED BY

Eric Lindquist, DMV  
DABVP, Cert. IVUSS

## IMAGING PERFORMED BY

Dr. Rodriguez

## HOSPITAL NAME

Foxfield VS

## REFERRING VET

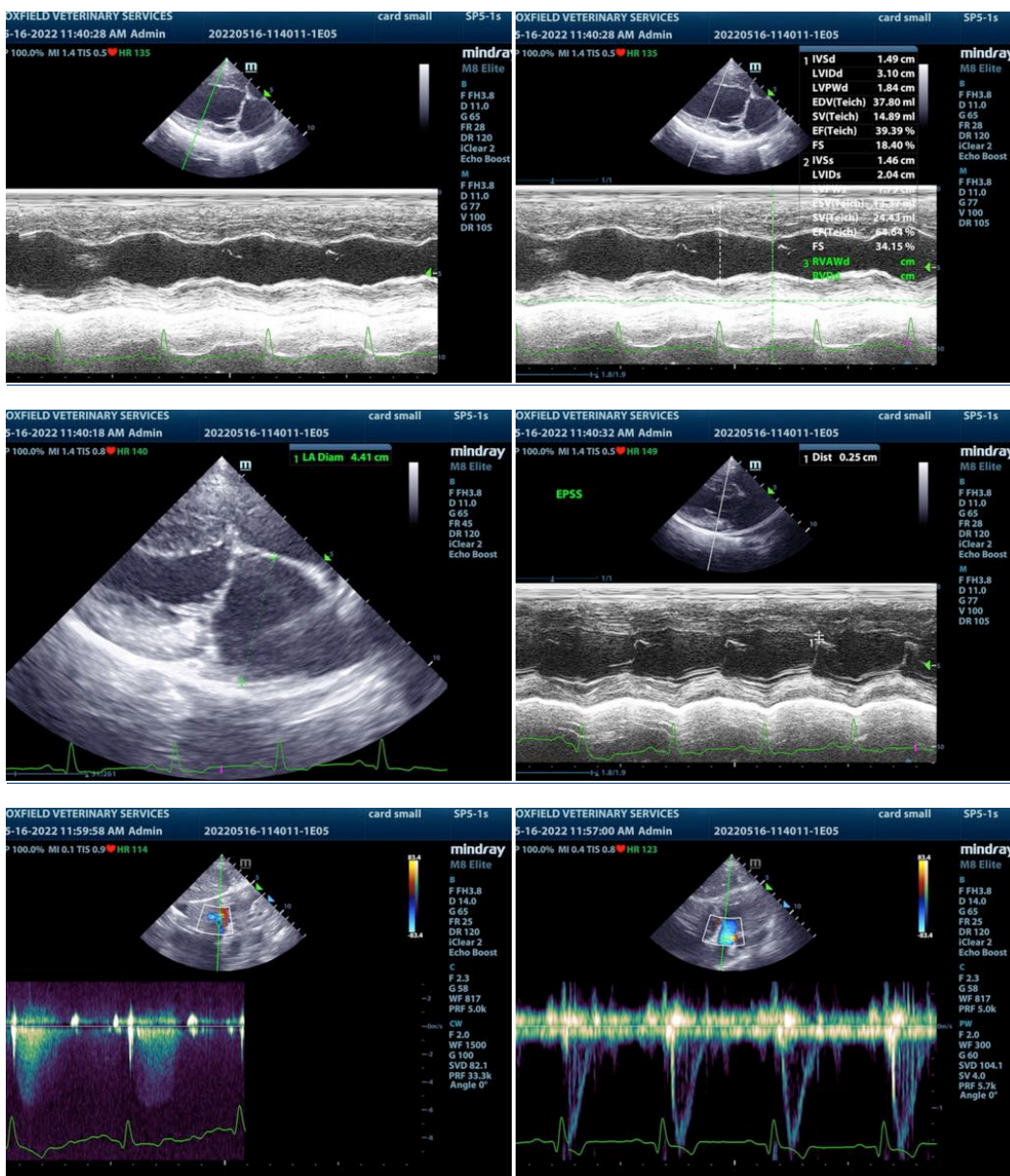
Dr. Rodriguez

## INVOICE

30411

## DATE

5/17/22





**PATIENT**

Cody Buonadonna

**SPECIES**

Canine

**BREED**

Australian Shepard

**SEX**

Neutered male

**AGE**

10 years

**WEIGHT**

61.8 lbs

**INTERPRETED BY**

Eric Lindquist, DMV  
DABVP, Cert. IVUSS

**IMAGING PERFORMED BY**

Dr. Rodriguez

**HOSPITAL NAME**

Foxfield VS

**REFERRING VET**

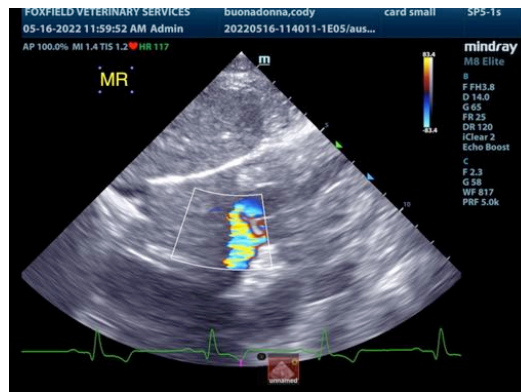
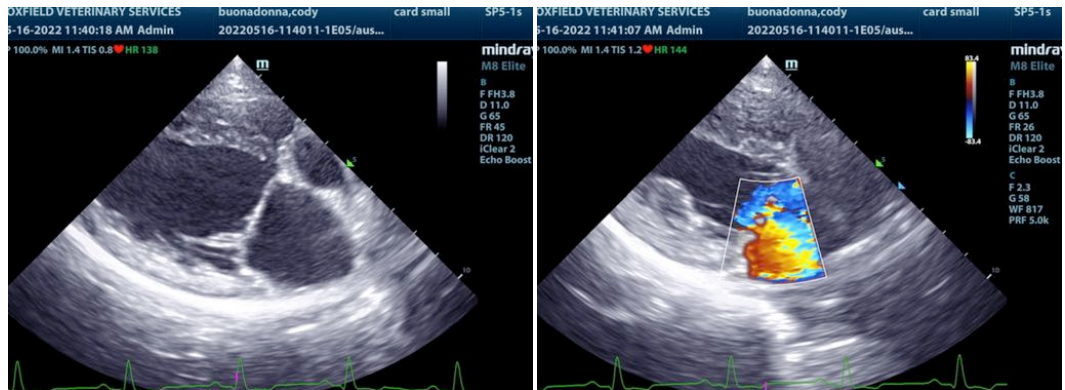
Dr. Rodriguez

**INVOICE**

30411

**DATE**

5/17/22



The information and recommendations provided are based on the images presented by the referring veterinarian/sonographer. No evaluation can be communicated regarding pathology that was not visible in the image/video clips provided.

Thank you for this referral. If the clinical or image interpretation does not parallel your findings or if I can be of any further assistance please contact me.

**Eric Lindquist, DMV, DABVP, Cert. IVUSS, CEO of SonoPath.com**  
info@SonoPath.com