



PATIENT

Ricki Birch

SPECIES

Feline

BREED

DSH

SEX

Neutered Male

AGE

1 Year

WEIGHT

7.6 lbs

INTERPRETED BY

Eric Lindquist, DMV,
 DABVP(CFM), Cert.
 IVUSS

IMAGING PERFORMED BY

Rebecca Hamilton

HOSPITAL NAME

Rondout Valley
 Veterinary Associates

REFERRING VET

Dr. Hartelius

INVOICE

16254

DATE

05/15/26

PRESENTING CLINICAL SIGNS

Cardiac enlargement with bulge at heart base on radiographs. Deep pitch prominent cardiac sounds bilaterally with reduced femoral pulse quality

Abnormal PE/Chem/CBC/UA Results: WNL

ULTRASONOGRAPHIC EXAMINATION OF THE HEART

FELINE CARDIAC PARAMETERS	BODY WEIGHT (lbs)	HR (BPM)	IVSd (cm)	LVIDd (cm)	LVWd (cm)	FS (%)	EF (%)
NORMAL PARAMETER	-----	150-240	0.3-0.6	1.0-2.1	0.25-0.6	35-67	80-100
PATIENT	7.6	NM	0.5	1.6	0.5	--	--
FELINE CARDIAC PARAMETERS	LA/AO (M-mode)	LA/AO HEART BASE (Sisson)	LAD LA MAX 4 Chamber		LVOT VEL (m/s)	RVOT VEL (m/s)	IVRT (m/)
NORMAL PARAMETER	<1.5	1.6	0.7-1.7		<1.6	<1.3	40-60
PATIENT	1.4	--	--		1.46	1.2	NM
Adapted from June Boon, Veterinary Echocardiography, 1998							
Sisson D et al. JVIM 1991; 5: 232, Jacobs et al. Am J Vet Res 1985; 46:1705							

EPSS: 0.1

Cardiac Presentation

Ventricular septal defect was noted in this patient. Tricuspid insufficiency was present measuring 2.0 m/s. Ventricular septal defect measured 0.65 cm in width. Right ventricular hypertrophy was noted. Bidirectional flow was noted in this patient, indicative of right-sided pressures starting to exceed the left side. Significant right-sided volume overload was noted.

ULTRASONOGRAPHIC FINDINGS

- Moderate/severe ventricular septal defect with right sided volume overload in early development of Eisenmenger's physiology.

INTERPRETATION OF THE FINDINGS & FURTHER RECOMMENDATIONS

Attention should be paid towards potential exercise intolerance. Specific treatment is debatable. Cardiologist review should be considered. Prognosis long-term is guarded.



PATIENT

Ricki Birch

SPECIES

Feline

BREED

DSH

SEX

Neutered Male

AGE

1 Year

WEIGHT

7.6 lbs

INTERPRETED BY

Eric Lindquist, DMV,
 DABVP(CFM), Cert.
 IVUSS

IMAGING PERFORMED BY

Rebecca Hamilton

HOSPITAL NAME

Rondout Valley
 Veterinary Associates

REFERRING VET

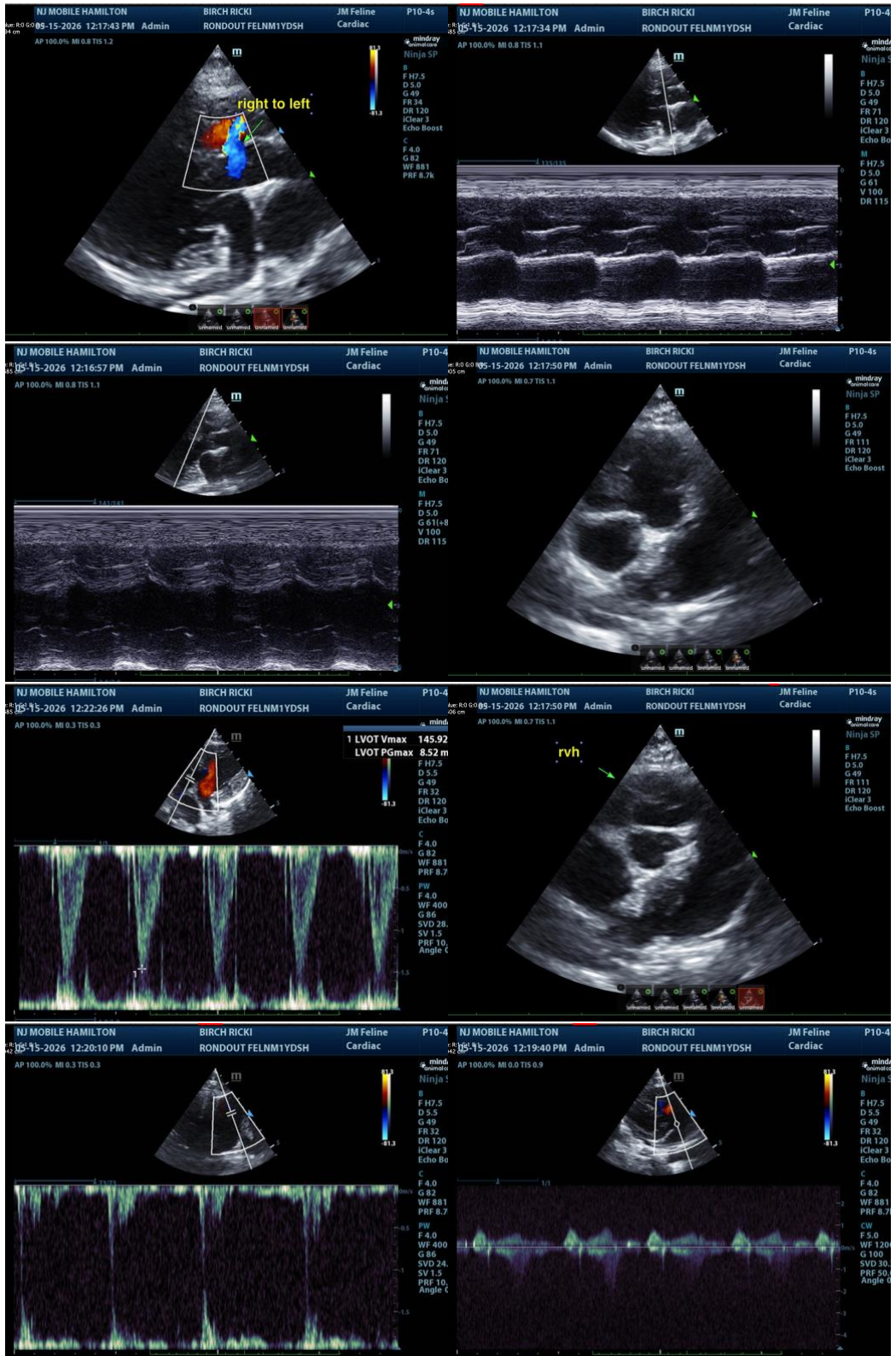
Dr. Hartelius

INVOICE

16254

DATE

05/15/26





PATIENT

Ricki Birch

SPECIES

Feline

BREED

DSH

SEX

Neutered Male

AGE

1 Year

WEIGHT

7.6 lbs

INTERPRETED BY

Eric Lindquist, DMV,
DABVP(CFM), Cert. IVUSS

IMAGING PERFORMED BY

Rebecca Hamilton

HOSPITAL NAME

Rondout Valley
Veterinary Associates

REFERRING VET

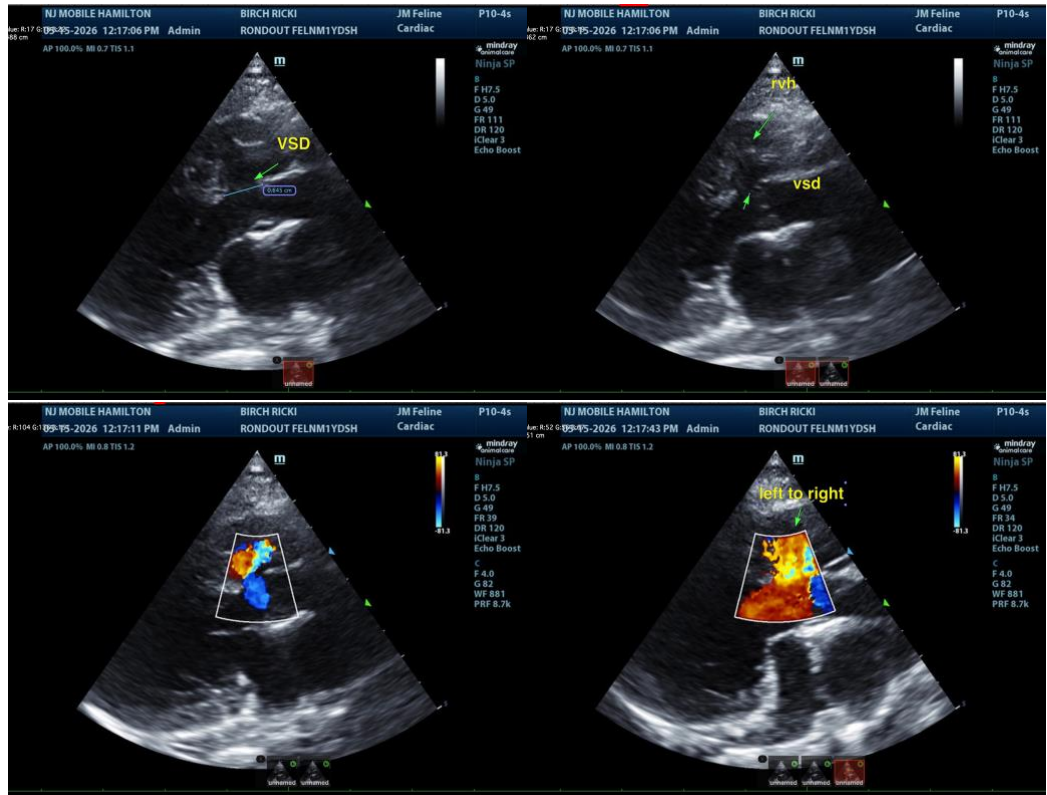
Dr. Hartelius

INVOICE

16254

DATE

05/15/26



The information and recommendations provided are based on the images presented by the referring veterinarian/sonographer. No evaluation can be communicated regarding pathology that was not visible in the image/video clips provided.

Thank you for this referral. If the clinical or image interpretation does not parallel your findings or if I can be of any further assistance, please contact me.

Eric Lindquist, DMV, DABVP(CFM), Cert. IVUSS,

CEO, Owner, Founder -- SonoPath.com

info@SonoPath.com

Ventricular Septal Defect

<http://www.sonopath.com/VSD>

<http://www.sonopath.com/EchoModler>

Description: Although ventricular septal defects (VSDs) account for less than 10% of congenital cardiac defects in dogs, they are far more common in cats, accounting for 56% of all cardiac defects. In dogs, the most frequently affected breeds



PATIENT

are the West Highland White Terrier, Keeshound, Mongrel, Pinscher, French Bulldog, German Shepherd, Labrador Retriever, English Springer Spaniel, and Basset Hound.

Ricki Birch

SPECIES

Feline

BREED

DSH

SEX

Neutered Male

AGE

1 Year

WEIGHT

7.6 lbs

INTERPRETED BY

Eric Lindquist, DMV,
DABVP(CFM), Cert.
IVUSS

**IMAGING
PERFORMED BY**

Rebecca Hamilton

HOSPITAL NAME

Rondout Valley
Veterinary Associates

REFERRING VET

Dr. Hartelius

INVOICE

16254

DATE

05/15/26

The most common VSDs in dogs and cats are located in the basal septum. The left side of the defect is typically located just below the aortic valve, while the right side of the defect is located either in the inflow tract ("subcrystal" or "perimembranous") or the outflow tract ("supracrystal"). VSDs can occur in combination with other congenital abnormalities or as part of an endocardial cushion defect. Muscular defects are less common. The resulting hemodynamic consequence depends mainly on the size of the VSD. In small defects, the pressure difference between the left and right heart remains normal and the shunt flow moves at a high velocity. Depending on the shunt volume, VSDs can lead to volume overload in the left heart and pulmonary artery. A large shunt will typically result in a pressure equilibrium across both chambers; however, if pulmonary hypertension develops, then reverse shunting can occur. The latter occurs mainly in cats and only rarely in dogs. VSDs that develop in combination with other defects will have a completely different pathophysiology.

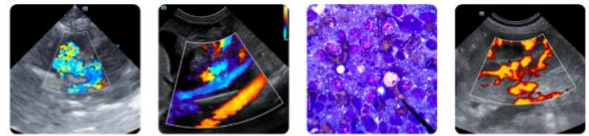
Clinical signs: Only a minority of patients with VSDs will show clinical signs. If the VSD is not too large (i.e., still resistive), a (usually loud) heart murmur can be auscultated on the right hemithorax. Large, non-resistive defects are not necessarily associated with a murmur.

Diagnostics: Perimembranous VSDs are easily seen on a right-sided apical five-chamber view just below the aortic valve. They can also be clearly seen on short axis views of the heart base. Supracrystal defects are easier to see on short axis views than on regular five-chamber views. To identify muscular defects, careful tracking of the interventricular septum using multiple short axis views is necessary. They can also be seen on left apical views when the transducer is placed a bit further dorsally (i.e., not perfectly apical). In small, resistive defects, the shunt flow will be observed as a high-velocity systolic jet. The typical maximal flow velocity (V_{max}) is approximately 5 m/s if normal pressure differences between the chambers are still present. Large defects do not show high-velocity flows. Slow left-to-right, right-to-left, or bidirectional flow can be displayed on a color Doppler ultrasound. In the latter case, the flow velocities are best displayed by PW-Doppler. Reversal of flow may also be demonstrated with a bubble study.

Treatment: The treatment depends on the pathophysiological status of the patient. Patients that have small defects with an insignificant flow do not require therapy; they can lead normal lives. Larger defects with marked left-sided and pulmonary arterial volume overload can be treated medically with the following: pimobendan (0.25-0.3 mg/kg PO BID); angiotensin-converting enzyme (ACE) inhibitors (enalapril at 0.5 mg/kg PO Q12-24hr or benazepril 0.25-0.5 mg/kg PO Q24hr); furosemide (1-2 mg/kg PO Q12-24hr, which can be increased incrementally, as needed); and/or spironolactone (0.25-2 mg/kg PO BID). Alternatively, they can be treated surgically via one of two options: pulmonary artery banding to increase right ventricular pressures and reduce shunting volumes, or closure of the defect via open heart surgery or a minimally invasive VSD closure.

References:

Bonagura JD, Lehmkuhl LB. Congenital heart disease. In Fox PR, Sisson D, Moise NS, eds. Canine and Feline Cardiology. Philadelphia, PA: WB Saunders; 1999:471-535.



PATIENT

Oliveira P, Domenech O, Silva J, et al. Retrospective review of congenital heart disease in 976 dogs. *J Vet Int Med* 2011;25:477-83.

Ricki Birch

SPECIES

Riesen S, Kovacevic A, Lombard C, Amberger C. Prevalence of heart disease in symptomatic cats: an overview from 1998 to 2005. *Schweiz Arch Tierheilk* 2007;149:65-72.

Feline

BREED

Saunders AB, Carlson JA, Nelson DA, et al. Hybrid technique for ventricular septal defect closure in a dog using an Amplatz Duct Occluder II. *J Vet Cardiol* 2013;15:217-24.

DSH

SEX

Neutered Male

AGE

1 Year

WEIGHT

7.6 lbs

INTERPRETED BY

Eric Lindquist, DMV,
DABVP(CFM), Cert.
IVUSS

**IMAGING
PERFORMED BY**

Rebecca Hamilton

HOSPITAL NAME

Rondout Valley
Veterinary Associates

REFERRING VET

Dr. Hartelius

INVOICE

16254

DATE

05/15/26