



PATIENT

Ohnmeiss Gus

SPECIES

Canine

BREED

Rottweiler

SEX

Male

AGE

6 months

WEIGHT

56.6 lbs

INTERPRETED BY

Eric Lindquist, DMV
DABVP, Cert. IVUSS

IMAGING PERFORMED BY

Alex McFeely

HOSPITAL NAME

Centre AH

REFERRING VET

Dr. McFeely

INVOICE

77610

DATE

5/15/26

PRESENTING CLINICAL SIGNS

History: Gus presented for PU/PD in late March 2026 (4.5 months of age). His urine was hyposthenuric but kidney values were elevated. He was started on a prescription kidney diet. Historically, Gus was rejected by his mother and bottle-fed as a neonatal puppy. UA: 1.011, sp gr 5.5, trace protein, rest neg/normal and quiet sediment Blood work: BUN elevated 62, Creat elevated 1.9, SDMA elevated 24, P elevated 10.3 and Ca elevated 12.2, albumin 2.5 (slightly decreased), rest of values normal CBC showed mild inflammatory leukogram/stress leukogram

ULTRASONOGRAPHIC EXAMINATION OF THE ABDOMEN

Urinary System

The **urinary bladder** presented minor, micropolypoid changes.

The **kidneys** revealed increased cortical echogenicity and slight irregular contour. There was cortical indentation on the dorsal cranial aspect of the right kidney. For this age patient these changes are not normal structure. There may be some level of minor renal dysplasia. The right kidney measured 5.4 cm. The left kidney measured 5.58 cm.

Adrenal Glands

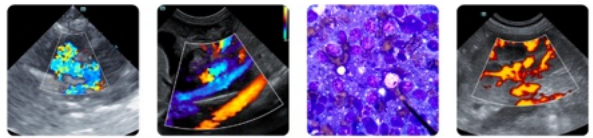
Both **adrenal glands** were visualized and recognized as having normal shape, size, position and echogenicity for this breed. The phrenic vasculature, glandular echogenicity and detail were unremarkable. Capsule, cortex, and medullary definition were normal for this age patient. The left adrenal gland measured 0.63 cm.

Spleen

The **spleen** presented a smooth homogeneous parenchyma hyperechoic to liver and renal cortical parenchyma. The capsule was smooth without noticeable expansion or deviation from within the spleen or adjacent pathology. The splenic vasculature demonstrated normal volume without signs of congestion or thrombosis. No sonographic evidence of acute or chronic inflammatory, neoplastic, or infarctual changes was noted.

Liver

The **liver** images submitted revealed subjectively normal liver size, contour, and structure. Parenchymal echogenicity was naturally coarse and hypoechoic to the spleen. Vascular and biliary tracts were of normal volume with no evidence of congestion. The gallbladder presented acceptably thin walls with primarily anechoic content. The cystic and common bile ducts were normal. No pathological hepatic lymphadenopathy was evident. No overt structural evidence of inflammatory, infiltrative or regenerative pathology was evident.



PATIENT

Ohnmeiss Gus

SPECIES

Canine

BREED

Rottweiler

SEX

Male

AGE

6 months

WEIGHT

56.6 lbs

INTERPRETED BY

Eric Lindquist, DMV
DABVP, Cert. IVUSS

IMAGING PERFORMED BY

Alex McFeely

HOSPITAL NAME

Centre AH

REFERRING VET

Dr. McFeely

INVOICE

77610

DATE

5/15/26

Gastrointestinal

There was some residual chyme and gas was noted in the **stomach**, yet not pathological. This is consistent with post prandial presentation. Transit of chyme into the small intestine was normal. Curvilinear patterns were maintained throughout the GI tract. No evidence of pathology. Small and large intestine demonstrated normal luminal chyme and stool consistency respectively. No obstructive or overt infiltrative disease was noted. No associated abnormal lymphatic activity was noted.

Pancreas

The base and limbs of the **pancreas** were observed to be largely isoechoic to surrounding omental fat. Pancreatic duct and capsular contour were acceptably normal and parenchyma respected normal curvilinear patterns. No overt evidence of active inflammatory or neoplastic disease was noted.

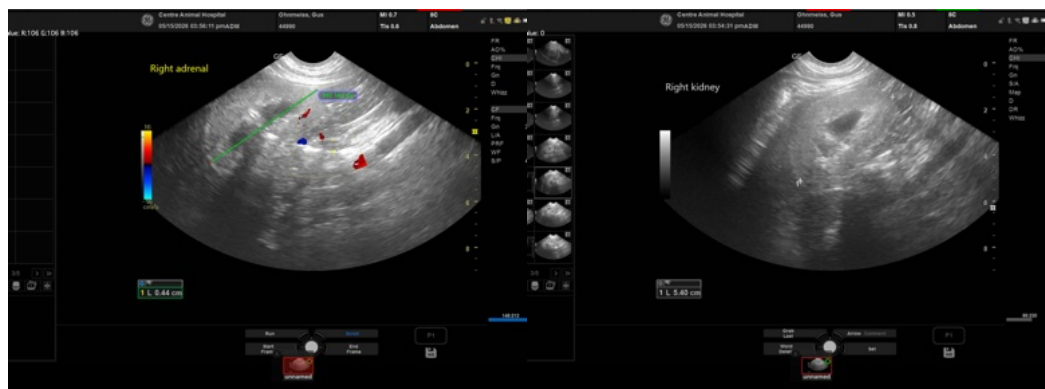
ULTRASONOGRAPHIC FINDINGS

Micronodular bladder changes.

Increased renal cortical echogenicity and slight irregular contour. Some form of minor renal dysplasia is possible.

INTERPRETATION OF THE FINDINGS & FURTHER RECOMMENDATIONS

Renal biopsy would be indicated. Underlying toxins or infectious agents such as Leptospirosis should be considered. There was no evidence of ectopic ureters. Underlying UTI with wash out effect such as E. Coli with ADH receptor inhibition could also be considered.





PATIENT

Ohnmeiss Gus

SPECIES

Canine

BREED

Rottweiler

SEX

Male

AGE

6 months

WEIGHT

56.6 lbs

INTERPRETED BY

Eric Lindquist, DMV
DABVP, Cert. IVUSS

IMAGING PERFORMED BY

Alex McFeely

HOSPITAL NAME

Centre AH

REFERRING VET

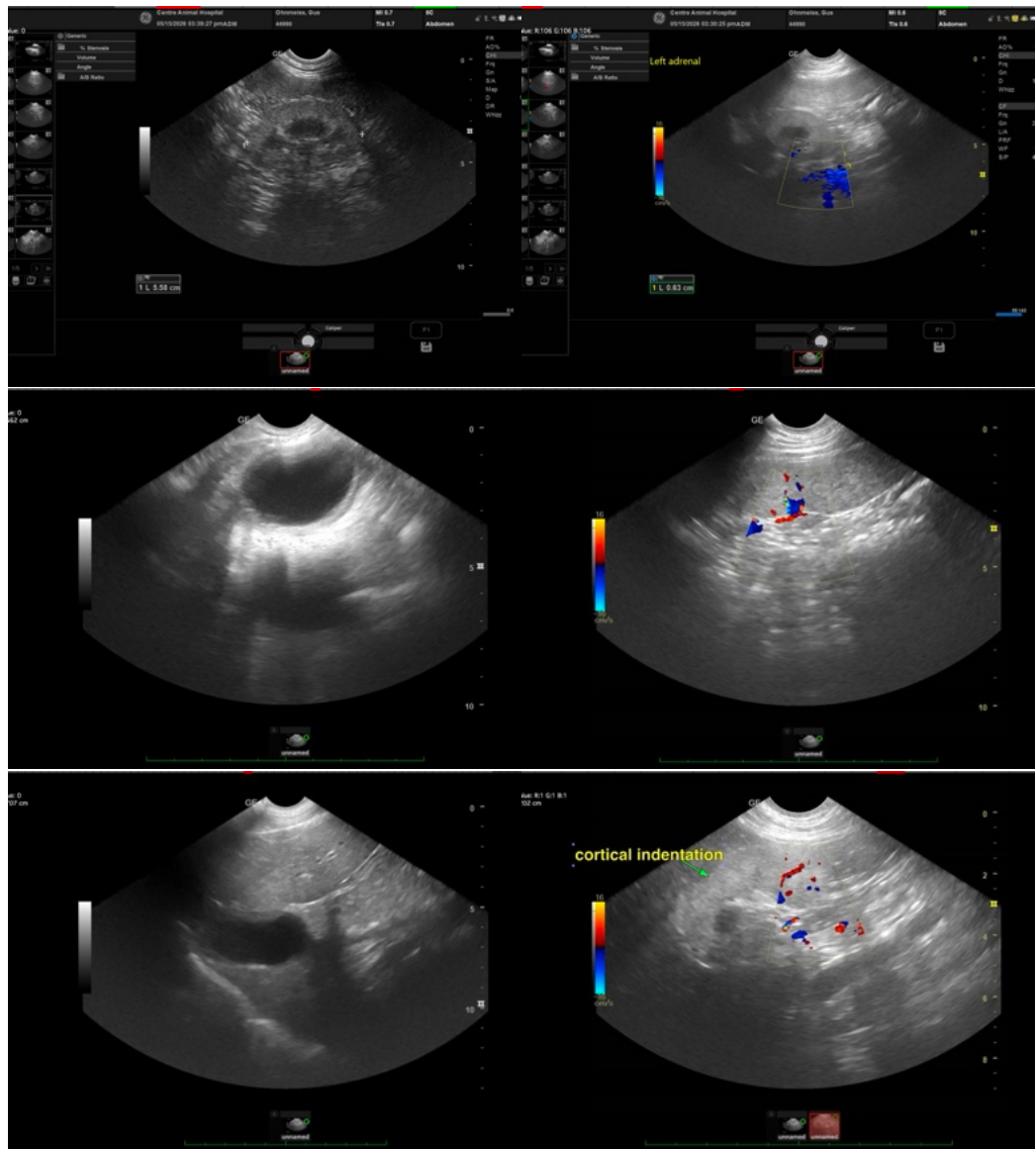
Dr. McFeely

INVOICE

77610

DATE

5/15/26



The information and recommendations provided are based on the images presented by the referring veterinarian/sonographer. No evaluation can be communicated regarding pathology that was not visible in the image/video clips provided.

Thank you for this referral. If the clinical or image interpretation does not parallel your findings or if I can be of any further assistance please contact me.

Eric Lindquist, DMV, DABVP (CFM), Cert. IVUSS, CEO of SonoPath.com

info@SonoPath.com