

## PATIENT

Melon Maki

## SPECIES

Canine

## BREED

Jindo Mix

## SEX

Neutered Male

## AGE

9

## WEIGHT

10.5 kg

## INTERPRETED BY

Eric Lindquist, DMV,  
DABVP(CFM), Cert.  
IVUSS

## IMAGING PERFORMED BY

Dr. Alastair Westcott,  
DVM

## HOSPITAL NAME

Dr. Alastair Westcott,  
DVM

## REFERRING VET

Dr. Alastair Westcott,  
DVM

## INVOICE

16297

## DATE

05/15/26

## PRESENTING CLINICAL SIGNS

Melon presented on an emergency basis for acute onset dyspnea, characterized by: Increased inspiratory effort. Panting. Obvious stress and discomfort. This represented an acute worsening of a chronic respiratory condition. Adopted from Korea in February 2024. Initial examinations unremarkable aside from dental disease. Heartworm testing negative at time of importation. Interceptor Plus dispensed for 6 months. Subsequent chronic respiratory history: Progressive chronic dry cough with gagging episodes. Goose-honk quality cough and wheeze. Progressive coughing fits with occasional collapse/stumbling episodes suggestive of possible vagal response. Previous investigations: Repeated thoracic radiographs demonstrating: Bronchointerstitial pulmonary disease. Suspected pulmonary hypertension. Right-sided cardiomegaly. Baermann fecal negative. Previous Echocardiogram (October 2025). ACVIM Stage B1 chronic valvular disease. Severe pulmonary hypertension. Current medications at presentation: Tadalafil SID. Prednisone 2.5 mg SID. Theophylline. Owner aware pulmonary hypertension management is palliative/supportive rather than curative.

Abnormal PE/Chem/CBC/UA Results: Mucous membranes pink; CRT <2 seconds Increased respiratory rate and inspiratory effort Diffuse pulmonary crackles obscuring cardiac auscultation Pulses fair and synchronous Patient placed immediately into oxygen supplementation. Thoracic Radiographs Subjective right-sided cardiomegaly Prominence/bulging of pulmonary trunk region Possible enlargement/thickening of right caudal pulmonary artery Severe generalized mixed bronchointerstitial pulmonary pattern most severe in middle to caudal lung lobes Mild alveolar spillover possible Mild neutrophilia Likely glucocorticoid/stress related Mild inflammatory contribution not excluded Mild ALT elevation Likely nonspecific/steroid related Low total T4 Most likely euthyroid sick syndrome or steroid suppression

## ULTRASONOGRAPHIC EXAMINATION OF THE HEART

CANINE CARDIAC PARAMETERS	MR VMAX (m/s)	TR VMAX (m/s)	LA/AO (M-Mode)	LA/AO (Heart Base; Swe)	FS (%)	EF (%)	EPSS (cm)
NORMAL PARAMETER	4.5-5.5	<2.7	1.3	Up to 1.6	28-40	40-100	<0.6
PATIENT	--	3.46	NM	--	55	87	NM
CANINE CARDIAC PARAMETERS	HR (BPM)	AV VMAX (m/s)	PV MAX (m/s)	BODY WEIGHT (kg)	LAD LA MAX 4 Chamber	LVIDd Avg; 2D and m-mode short axis (cm)	LVIDs Avg; 2D and m-mode short axis (cm)
NORMAL PARAMETER	50-100	0.7-1.7	0.7-1.6				
PATIENT	NM	1.47	0.94	10.5	1.34	2.8	--

E-wave velocity: 0.75

## Cardiac Presentation



## PATIENT

Melon Maki

## SPECIES

Canine

## BREED

Jindo Mix

## SEX

Neutered Male

## AGE

9

## WEIGHT

10.5 kg

## INTERPRETED BY

Eric Lindquist, DMV,  
DABVP(CFM), Cert.  
IVUSS

## IMAGING PERFORMED BY

Dr. Alastair Westcott,  
DVM

## HOSPITAL NAME

Dr. Alastair Westcott,  
DVM

## REFERRING VET

Dr. Alastair Westcott,  
DVM

## INVOICE

16297

## DATE

05/15/26

The echocardiogram in this patient demonstrated normal **left atrial** size based on 3 different LA measurement methods. Chamber volumes and echogenicity were normal. The cranial and caudal **mitral** valve leaflets presented vegetative thickening consistent with endocardiosis. Doppler indicated minor centralized insufficiency. The **left ventricle** presented normal thicknesses with linear contour and was not dilated nor restricted. The **myocardium** presented normal echogenicity without subjective evidence of significant fibrotic or ischemic disease. **Contractility** of the ventricular walls was adequate and in normal range for this patient evidenced by the fractional shortening measurement and subjective evaluation of the different regions of the myocardium. The **left ventricular outflow** tract demonstrated normal laminar flow and subjective structural integrity. The **right atrium** was a 1:1 ratio with the left atrium. Slight flattening of left ventricular septum was noted with mild volume overload of the right heart. Right ventricular hypertrophy was noted. The pulmonary artery appeared dilated with pulmonic insufficiency. The deep pulmonary artery presented with no evident turbulence. No evidence of PDA was noted. The branches of the pulmonary artery were also dilated. This is strongly suggestive of pulmonary hypertension. No visible **pericardial** or free pleura fluid was noted. No echographically detectable evidence of infiltrative disease was visible. The cranial **mediastinum and pericardial regions** were free of masses in the visible window.

## ULTRASONOGRAPHIC FINDINGS

- Stage B1 valvular disease with pulmonary hypertension.
- Secondary right sided enlargement.

## INTERPRETATION OF THE FINDINGS & FURTHER RECOMMENDATIONS

Recommend imaging the hepatic veins and vena cava in this patient to assess for potential passive congestion and emerging right-sided heart failure. Primary respiratory protocol is warranted in this patient. If any hepatic vein dilation is present, then sildenafil could be considered. However, heartworm infestation in the deep pulmonary artery on view is possible.

Sildenafil management would be recommended at 1.0 mg/kg BID increasing to 1.5 mg/kg after two weeks and then likely, depending upon patient status, increasing to 2 mg/kg, up titrating every two weeks.

Addressing the primary respiratory cause would be ideal in this patient depending upon radiograph and or CT findings. Abdominal sonogram would not be a bad idea to assess for any predisposing issues that may be contributing. Serial blood pressure is also warranted if not already performed.



## PATIENT

Melon Maki

## SPECIES

Canine

## BREED

Jindo Mix

## SEX

Neutered Male

## AGE

9

## WEIGHT

10.5 kg

## INTERPRETED BY

Eric Lindquist, DMV,  
DABVP(CFM), Cert.  
IUUSS

## IMAGING PERFORMED BY

Dr. Alastair Westcott,  
DVM

## HOSPITAL NAME

Dr. Alastair Westcott,  
DVM

## REFERRING VET

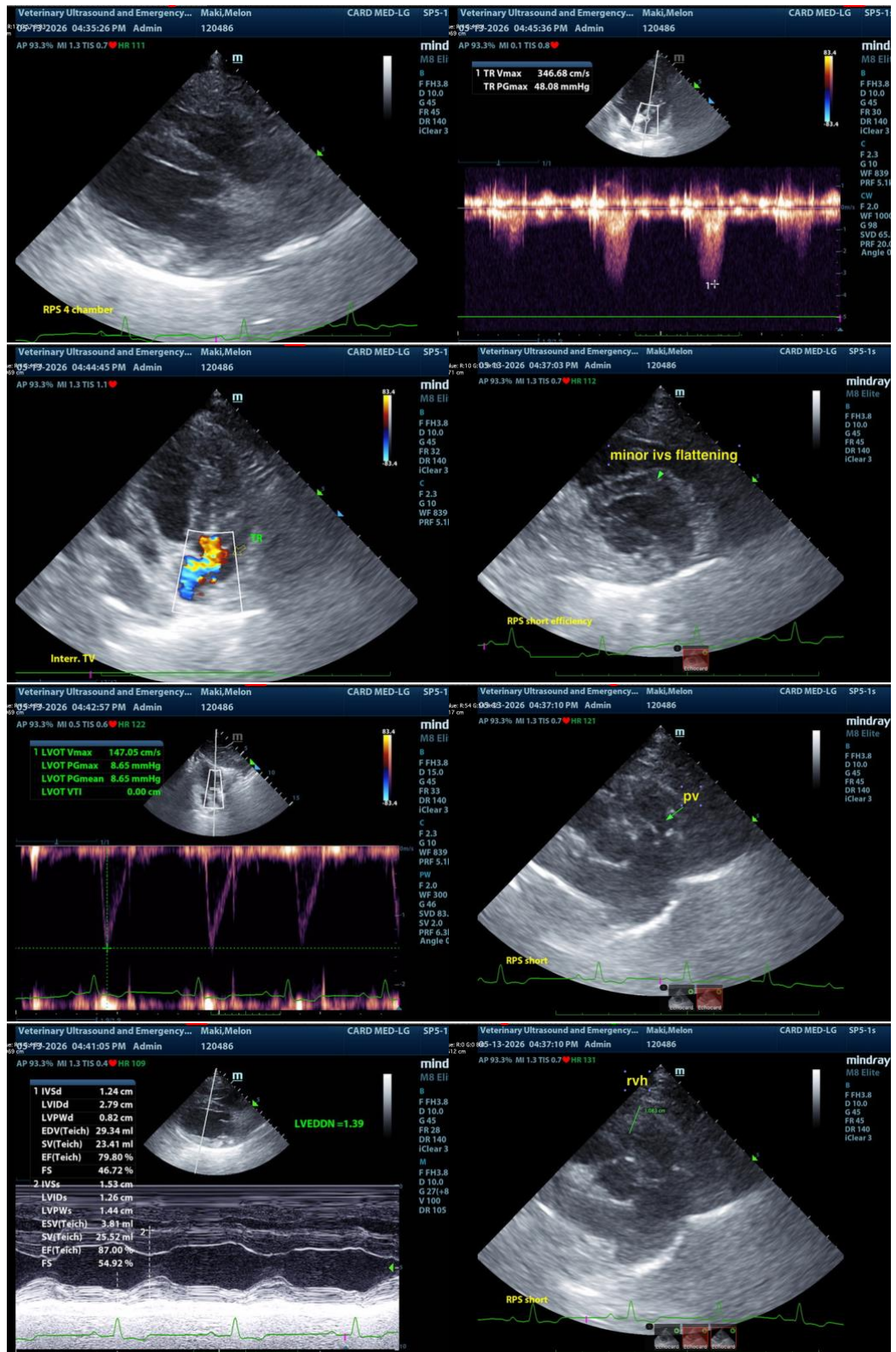
Dr. Alastair Westcott,  
DVM

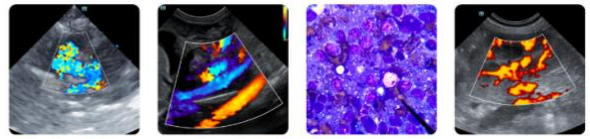
## INVOICE

16297

## DATE

05/15/26





**PATIENT**

Melon Maki

**SPECIES**

Canine

**BREED**

Jindo Mix

**SEX**

Neutered Male

**AGE**

9

**WEIGHT**

10.5 kg

**INTERPRETED BY**

Eric Lindquist, DMV,  
DABVP(CFM), Cert.  
IVUSS

**IMAGING PERFORMED BY**

Dr. Alastair Westcott,  
DVM

**HOSPITAL NAME**

Dr. Alastair Westcott,  
DVM

**REFERRING VET**

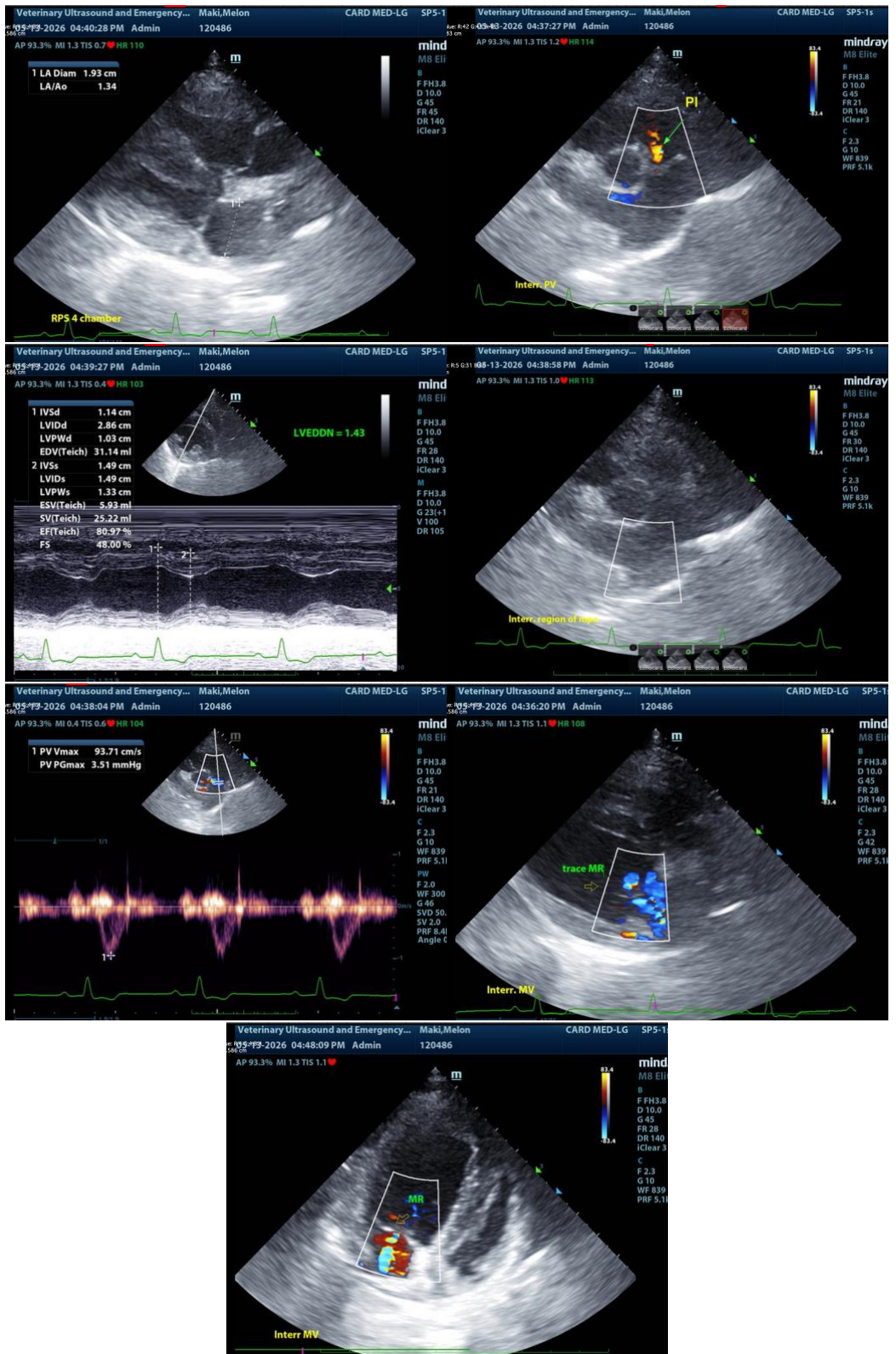
Dr. Alastair Westcott,  
DVM

**INVOICE**

16297

**DATE**

05/15/26





## PATIENT

Melon Maki

The information and recommendations provided are based on the images presented by the referring veterinarian/sonographer. No evaluation can be communicated regarding pathology that was not visible in the image/video clips provided.

## SPECIES

Canine

Thank you for this referral. If the clinical or image interpretation does not parallel your findings or if I can be of any further assistance, please contact me.

Eric Lindquist, DMV, DABVP(CFM), Cert. IVUSS,

## BREED

Jindo Mix

CEO, Owner, Founder -- SonoPath.com

[info@SonoPath.com](mailto:info@SonoPath.com)

## SEX

Neutered Male

## Right Heart Disease-General Considerations

## AGE

9

<http://www.sonopath.com/RightHeartDisease>

## WEIGHT

10.5 kg

**Description:** Right heart disease is often an incidental finding, which can be either cardiogenic or secondary to respiratory or systemic disease. The coughing patient with right heart disease may present with primary respiratory disease (i.e., bronchial collapse, collapsing trachea, pneumonitis) and suffer from secondary pulmonary hypertension (PHT). Concurrent mitral valve disease and chronic left-sided congestive heart failure (CHF) might also lead to PHT. The dyspeic patient with right heart enlargement might have pulmonary hypertension due to airway disease, chronic CHF, parenchymal lung disease (e.g. pulmonary fibrosis), or a cardiac shunt with secondary PHT and shunt reversal.

## INTERPRETED BY

Eric Lindquist, DMV,  
DABVP(CFM), Cert.  
IVUSS

Primary cardiac causes of right heart enlargement include: tricuspid dysplasia/degeneration; pulmonic stenosis; pulmonic insufficiency; atrial or septal defects; patent ductus arteriosus; right auricular masses; and pericardial peritoneal diaphragmatic hernias. The second most common cause of right-sided enlargement is secondary PHT, which results in high-velocity tricuspid insufficiency (TR vel.>2.8 m/sec) and pulmonic insufficiency due to diseases that cause increased pulmonary vascular resistance or increased pulmonary wedge pressures. The most common cause of secondary PHT is left-sided heart failure (LHF), which presents radiographically as a more globoid-shaped heart with marked left atrial and ventricular enlargement. There are also signs of left-sided CHF as opposed to a simple prominent cranial waist or reverse D radiographic presentation.

## IMAGING PERFORMED BY

Dr. Alastair Westcott,  
DVM

## HOSPITAL NAME

Dr. Alastair Westcott,  
DVM

## REFERRING VET

Dr. Alastair Westcott,  
DVM

Secondary, non-cardiac causes of PHT include: acute or chronic respiratory disease; pulmonary thromboembolic disease; thoracic neoplasia; excessive thoracic fat deposition (e.g. Pickwickian syndrome, which leads to chronic hypoxia); brachycephalic syndrome; high altitude disease; heartworm disease; and primary vascular disease.

## INVOICE

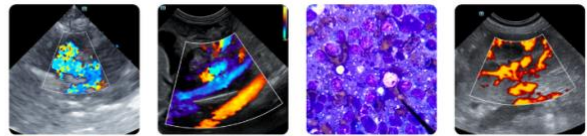
16297

**Clinical Signs:** The most common presenting symptoms of right heart disease are collapse, syncope, intermittent or constant acute respiratory distress (e.g. thromboembolic disease), and exercise intolerance.

## DATE

05/15/26

**Diagnostics:** Physical examination may reveal a right-sided apical heart murmur and/or a cranial left heart murmur, a split S2, jugular distension, ascites, and signs consistent with respiratory disease (i.e., cough, wheeze, tracheal collapse, tachypnea). Radiographic findings may reveal an enlarged right atrium, right ventricle, and/or primary/secondary branches of



## PATIENT

Melon Maki

## SPECIES

Canine

## BREED

Jindo Mix

## SEX

Neutered Male

## AGE

9

## WEIGHT

10.5 kg

## INTERPRETED BY

Eric Lindquist, DMV,  
DABVP(CFM), Cert.  
IVUSS

## IMAGING PERFORMED BY

Dr. Alastair Westcott,  
DVM

## HOSPITAL NAME

Dr. Alastair Westcott,  
DVM

## REFERRING VET

Dr. Alastair Westcott,  
DVM

## INVOICE

16297

## DATE

05/15/26

the pulmonary artery. In cases of PHT, an enlarged or engorged pulmonary artery is often present. Tortuous arteries or those that suddenly terminate can indicate the presence of thromboembolic disease or heartworms. An interstitial pattern might indicate the presence of pulmonary parasitism or primary interstitial lung disease. Pulmonic stenosis is suspected if the pulmonic segment is enlarged. ECG findings include tall P and S waves with a right axis shift.

**Treatment:** Please refer to the chapter "Pulmonary Hypertension" for therapeutic recommendations.

### References:

Oyama MA, Rush JE, Rozanski EA, et al. Assessment of serum N-terminal pro-B-type natriuretic peptide concentration for differentiation of congestive heart failure from primary respiratory tract disease as the cause of respiratory signs in dogs. *J Am Vet Med Assoc* 2009;235:1319-25.

Rozanski E. Interstitial lung disease in small animals. Proceedings from American College of Veterinary Internal Medicine Forum, Denver, CO, June 15-18, 2011.

Zoia A, Augusto M, Drigo M, Caldin M. Evaluation of hemostatic and fibrinolytic markers in dogs with ascites attributable to right-sided congestive heart failure. *J Am Vet Med Assoc* 2012;241:1336-43.