

PATIENT

Luke Kears

SPECIES

Canine

BREED

Terrier Mix

SEX

Neutered Male

AGE

6 Years 5 Months

WEIGHT

29 lbs

INTERPRETED BY

Eric Lindquist, DMV,
 DABVP(CFM), Cert.
 IVUSS

IMAGING PERFORMED BY

Kathleen Byrnes

HOSPITAL NAME

Animal Hospital of
 Boone

REFERRING VET

Dr. Watson

INVOICE

16255

DATE

05/15/26

PRESENTING CLINICAL SIGNS

P presented for US due to painful when defecating- possible swelling around rectum felt on rectal exam

ULTRASONOGRAPHIC EXAMINATION OF THE ABDOMEN

Urinary System

The **urinary bladder**, trigone, and pelvic urethra to a depth of 4.0 cm presented normal thicknesses and normal tone. The ureters were not visible which is normal. No uroliths or sediment were visualized, and anechoic urine was present. No evidence of inflammatory or neoplastic changes were noted. Ureteral papillae were normal.

The **residual prostate** was uniform measuring 0.87 cm.

The **iliac trifurcation** was unremarkable.

The **kidneys** revealed normal size and structure, corticomedullary definition and ratio for this age. The cortices presented largely uniform texture with normal echogenic relationship to liver and spleen. Medullary structure differed distinctly from the cortex and no evidence of pelvic dilation was present. The capsules were acceptably uniform without significant irregularities. The left kidney measured 5.24 cm in length. The right kidney measured 4.6 cm in length.

Adrenal Glands

Both **adrenal glands** were visualized and recognized as having normal shape, size, position and echogenicity for this breed. The phrenic vasculature, glandular echogenicity and detail were unremarkable. Capsule, cortex, and medullary definition were normal for this age patient. The left adrenal gland measured 2.4 cm x 0.43 cm width at the caudal pole and 0.49 cm width at the cranial pole. The right adrenal gland measured 2.0 cm x 0.5 cm width at the caudal pole and 0.35 cm width at the cranial pole.

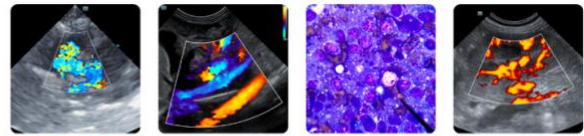
Spleen

The **spleen** presented a smooth homogeneous parenchyma hyperechoic to liver and renal cortical parenchyma. The capsule was smooth without noticeable expansion or deviation from within the spleen or adjacent pathology. The splenic vasculature demonstrated normal volume without signs of congestion or thrombosis. No sonographic evidence of acute or chronic inflammatory, neoplastic, or infarctual changes were noted.

Liver

The **liver** images submitted revealed subjectively normal liver size, contour, and structure. Parenchymal echogenicity was naturally coarse and hypoechoic to the spleen. Vascular and biliary tracts were of normal volume with no evidence of congestion. The gallbladder presented acceptably thin walls with primarily anechoic content. The cystic and common bile ducts were normal. No pathological hepatic lymphadenopathy was evident. No overt structural evidence of inflammatory, infiltrative or regenerative pathology was evident.

Gastrointestinal



PATIENT

Luke Kears

SPECIES

Canine

BREED

Terrier Mix

SEX

Neutered Male

AGE

6 Years 5 Months

WEIGHT

29 lbs

INTERPRETED BY

Eric Lindquist, DMV,
DABVP(CFM), Cert.
IVUSS

IMAGING PERFORMED BY

Kathleen Byrnes

HOSPITAL NAME

Animal Hospital of
Boone

REFERRING VET

Dr. Watson

INVOICE

16255

DATE

05/15/26

Examination of the **gastrointestinal tract** revealed a stomach and intestine free of stasis, of normal wall thickness, acceptable curvilinear mural detail, and peristaltic activity. Small intestine demonstrated normal luminal chyme respectively. No obstructive or overt infiltrative disease was noted. No associated abnormal lymphatic activity was noted.

The descending colon was unremarkable imaged deep into the pelvic inlet. Cannot rule out pathology in the last 2.0-4.0 cm of the descending colon, however, the entire pelvic colon appeared normal with normal stool consistency and wall thickness.

Pancreas

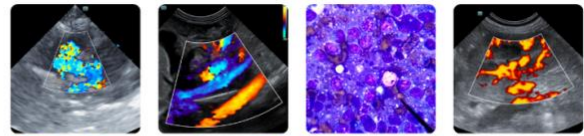
The base and limbs of the **pancreas** were observed to be largely isoechoic to surrounding omental fat. Pancreatic duct and capsular contour were acceptably normal and parenchyma respected normal curvilinear patterns. No overt evidence of active inflammatory or neoplastic disease was noted.

ULTRASONOGRAPHIC FINDINGS

- Structurally unremarkable abdomen.
- Normal visible colonic structure.

INTERPRETATION OF THE FINDINGS & FURTHER RECOMMENDATIONS

No evidence of pathology. Assessment for potential anal gland pathology with manual palpation +/- ultrasound. Orthopedic pain in the lumbosacral area should also be considered as a potential yet no evidence of visceral disease.



PATIENT

Luke Kearse

SPECIES

Canine

BREED

Terrier Mix

SEX

Neutered Male

AGE

6 Years 5 Months

WEIGHT

29 lbs

INTERPRETED BY

Eric Lindquist, DMV,
 DABVP(CFM), Cert.
 IUUSS

IMAGING PERFORMED BY

Kathleen Byrnes

HOSPITAL NAME

Animal Hospital of
 Boone

REFERRING VET

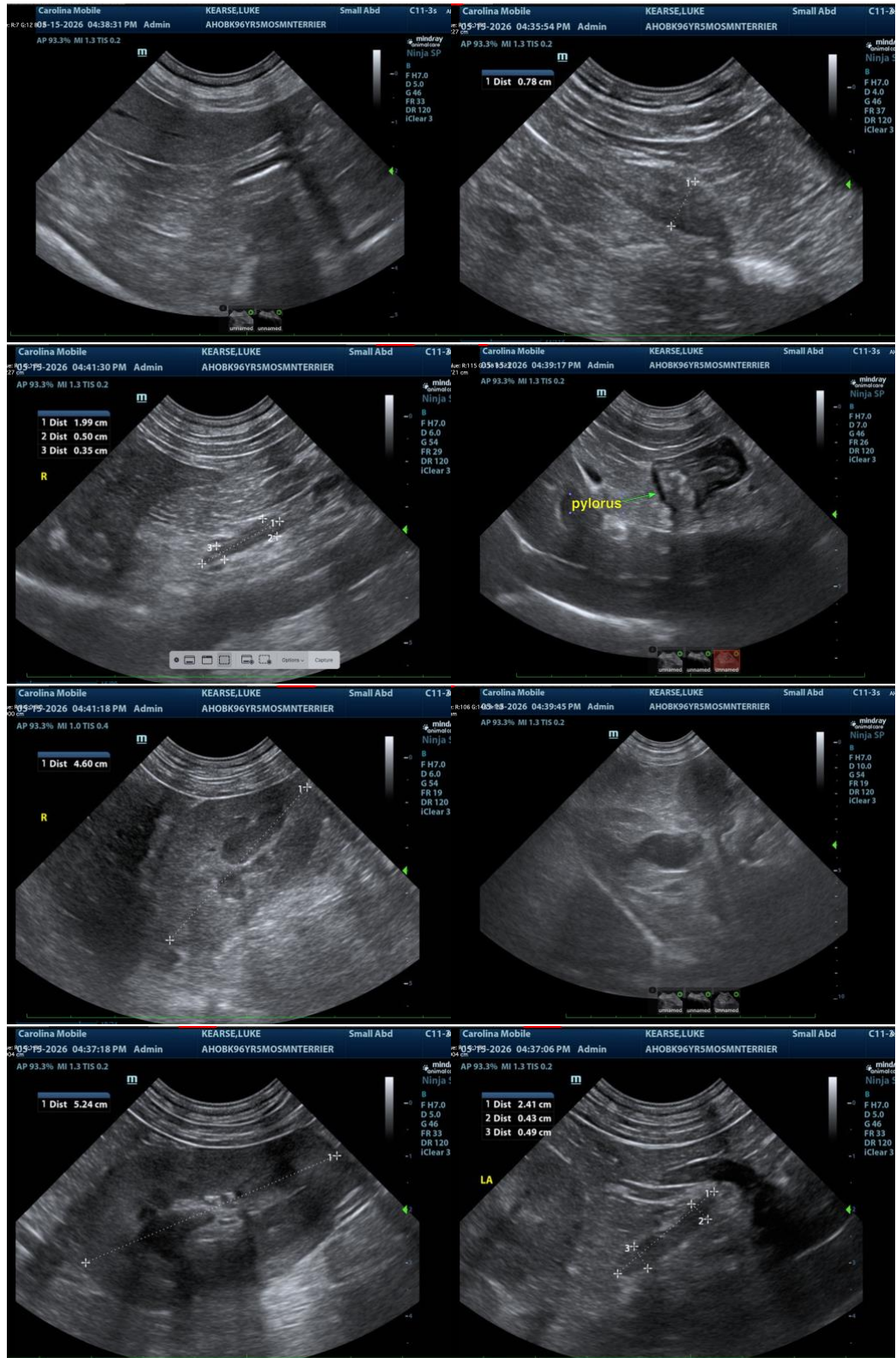
Dr. Watson

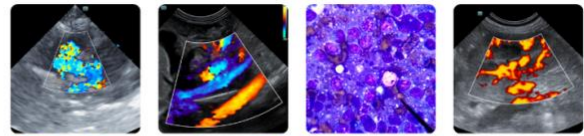
INVOICE

16255

DATE

05/15/26





PATIENT

Luke Kearse

SPECIES

Canine

BREED

Terrier Mix

SEX

Neutered Male

AGE

6 Years 5 Months

WEIGHT

29 lbs

INTERPRETED BY

Eric Lindquist, DMV,
 DABVP(CFM), Cert. IVUSS

IMAGING PERFORMED BY

Kathleen Byrnes

HOSPITAL NAME

Animal Hospital of
 Boone

REFERRING VET

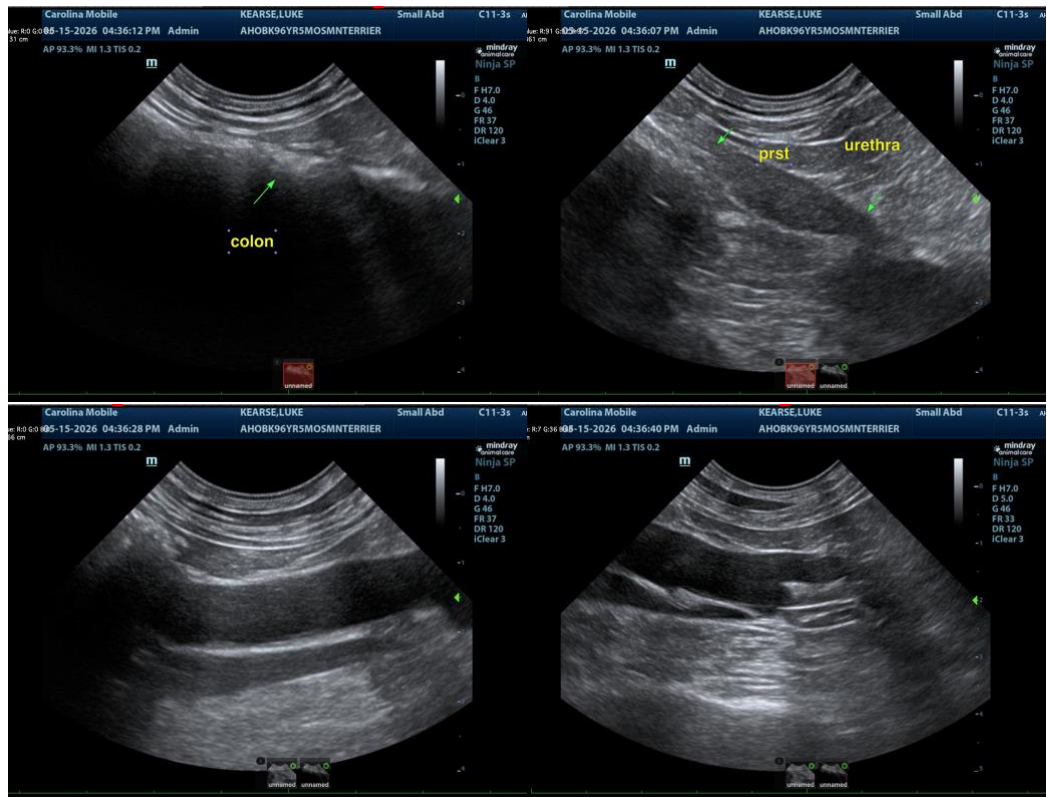
Dr. Watson

INVOICE

16255

DATE

05/15/26



The information and recommendations provided are based on the images presented by the referring veterinarian/sonographer. No evaluation can be communicated regarding pathology that was not visible in the image/video clips provided.

Thank you for this referral. If the clinical or image interpretation does not parallel your findings or if I can be of any further assistance, please contact me.

Eric Lindquist, DMV, DABVP(CFM), Cert. IVUSS,

CEO, Owner, Founder -- SonoPath.com

info@SonoPath.com