

## PATIENT

Buddy Turner

## SPECIES

Canine

## BREED

Maltese

## SEX

Neutered Male

## AGE

12 Years

## WEIGHT

14.3 lbs

## INTERPRETED BY

Eric Lindquist, DMV,  
DABVP(CFM), Cert.  
IVUSS

## IMAGING PERFORMED BY

Janel Schietzelt, DVM

## HOSPITAL NAME

Dreaming Summit  
Animal Hospital

## REFERRING VET

Janel Schietzelt, DVM

## INVOICE

16296

## DATE

05/15/26

## PRESENTING CLINICAL SIGNS

Patient presents for hematuria. Have seen in the home for sometime but though it was their other dog. No witnessed straining, otherwise doing well at home. Has always had a picky appetite per owner. Normal vitals on exam, BCS 6/9. Grade 3/4 PDD. Found mass-like structure on ultrasound attempting us-guided cystocentesis, owner approved localized focal ultrasound only. Concern for neoplasia vs bladder stone vs other

Small CBC/Chem10/Urinalysis with urine culture/sensitivity pending -Recommended BRAF urine test as next step -No previous lab work in the past to compare to

## LIMITED ULTRASONOGRAPHIC EXAMINATION

### Urinary System

The **urinary bladder** revealed an apical dorsal mass deriving from the mucosal layer. Some invasion into the submucosal layer and muscularis was noted. The mass does appear potentially resectable. The cystourethral junction and urethra appeared free of evident pathology.

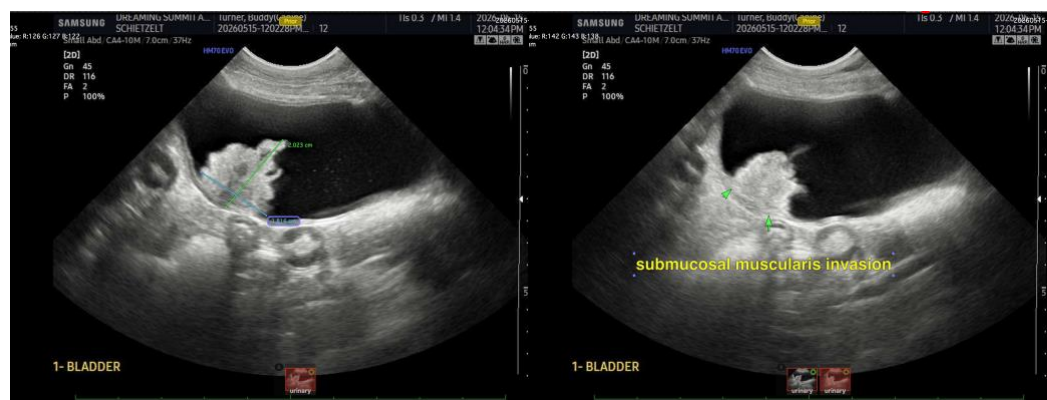
The **residual prostate** was uniform measuring 0.77cm.

## ULTRASONOGRAPHIC FINDINGS

- Apical dorsal bladder mass- appears resectable. Strong concern for carcinoma, polyploid hyperplasia possible, fibroma or stromal tumor possible, yet less likely.

## INTERPRETATION OF THE FINDINGS & FURTHER RECOMMENDATIONS

BRAF testing is indicated and/or direct surgical removal. Chest radiographs are warranted to assess for metastatic disease.





## PATIENT

Buddy Turner

## SPECIES

Canine

## BREED

Maltese

## SEX

Neutered Male

## AGE

12 Years

## WEIGHT

14.3 lbs

## INTERPRETED BY

Eric Lindquist, DMV,  
DABVP(CFM), Cert.  
IVUSS

## IMAGING PERFORMED BY

Janel Schietzelt, DVM

## HOSPITAL NAME

Dreaming Summit  
Animal Hospital

## REFERRING VET

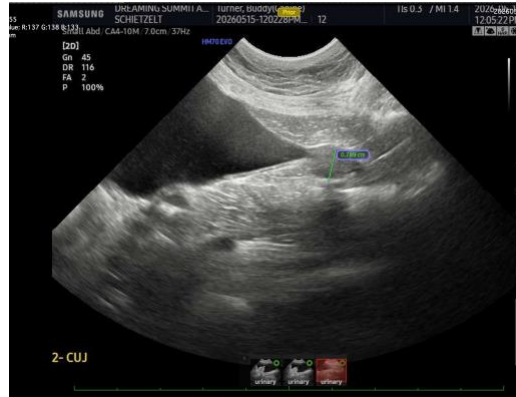
Janel Schietzelt, DVM

## INVOICE

16296

## DATE

05/15/26



The information and recommendations provided are based on the images presented by the referring veterinarian/sonographer. No evaluation can be communicated regarding pathology that was not visible in the image/video clips provided.

Thank you for this referral. If the clinical or image interpretation does not parallel your findings or if I can be of any further assistance, please contact me.

**Eric Lindquist, DMV, DABVP(CFM), Cert. IVUSS,**

CEO, Owner, Founder -- SonoPath.com

[info@SonoPath.com](mailto:info@SonoPath.com)