



**PATIENT PRESENTING CLINICAL SIGNS**

Poppy Batsides History: Grade2-3 heart murmur

**SPECIES ULTRASONOGRAPHIC EXAMINATION OF THE HEART**

Canine

**BREED**

Cavachon

**SEX**

Spayed Female

**AGE**

12 Years 2 Months

**WEIGHT**

28 Pounds

**INTERPRETED BY**

Eric Lindquist, DMV,  
DABVP (Canine &  
Feline), Cert. IVUSS

**IMAGING PERFORMED BY**

Rebecca Hamilton

**HOSPITAL NAME**

Wyckoff VH

**REFERRING VET**

Dr. Eisenberg

**INVOICE**

37118

**DATE**

5/14/26

CANINE CARDIAC PARAMETERS	MR VMAX (m/s)	TR VMAX (m/s)	LA/AO (M-Mode)	LA/AO (Heart Base; Swe)	FS (%)	EF (%)	EPSS (cm)
NORMAL PARAMETER	4.5-5.5	<2.7	1.3	Up to 1.6	28-40	40-100	<0.6
PATIENT	6.03		NM	1.6	42	74	0.2
CANINE CARDIAC PARAMETERS	HR (BPM)	AV VMAX (m/s)	PV MAX (m/s)	BODY WEIGHT (lbs)	LAD LA MAX 4 Chamber	LVIDd Avg; 2D and m-mode short axis (cm)	LVIDs Avg; 2D and m-mode short axis (cm)
NORMAL PARAMETER	50-100	0.7-1.7	0.7-1.6				
PATIENT	142	2.10	.96	28	3.6	3.46	--

**Cardiac Presentation**

The left atrium was borderline in this patient, as far as upper limits of normal, yet the other atrial measurement parameters were normal. Prolapse of the anterior mitral valve leaflet was noted. Doppler indicated moderate eccentric mitral insufficiency. The **left ventricle** presented thicknesses with linear contour and was not dilated nor restricted. The **myocardium** presented normal echogenicity without subjective evidence of significant fibrotic or ischemic disease. **Contractility** of the ventricular walls was adequate and in normal range for this patient evidenced by the fractional shortening measurement and subjective evaluation of the different regions of the myocardium. Aortic insufficiency (4.5 m/s) was noted. The **right atrium** and auricle revealed normal size, structure and content. No evidence of masses was noted or chamber overload. **Tricuspid** valvular assessment demonstrated adequate linear morphology. The **right ventricle** was of normal size (1/3 diameter of LV), chordae structure, myocardial echogenicity and thickness. **Pulmonic** tract assessment revealed normal valve structure, laminar flow, and diameter (approx.1:1 pa/ao ratio). No visible **pericardial** or free pleura fluid was noted. No echographically detectable evidence of infiltrative disease was visible. The cranial **mediastinum and pericardial regions** were free of masses in the visible window. The hepatic veins were not dilated in this patient.

**ULTRASONOGRAPHIC FINDINGS**

- Stage B-1 valvular disease
- Mitral valve prolapse
- Aortic insufficiency



**PATIENT**

Poppy Batsides

**SPECIES**

Canine

**BREED**

Cavachon

**SEX**

Spayed Female

**AGE**

12 Years 2 Months

**WEIGHT**

28 Pounds

**INTERPRETED BY**

Eric Lindquist, DMV,  
 DABVP (Canine & Feline), Cert. IVUSS

**IMAGING PERFORMED BY**

Rebecca Hamilton

**HOSPITAL NAME**

Wyckoff VH

**REFERRING VET**

Dr. Eisenberg

**INVOICE**

37118

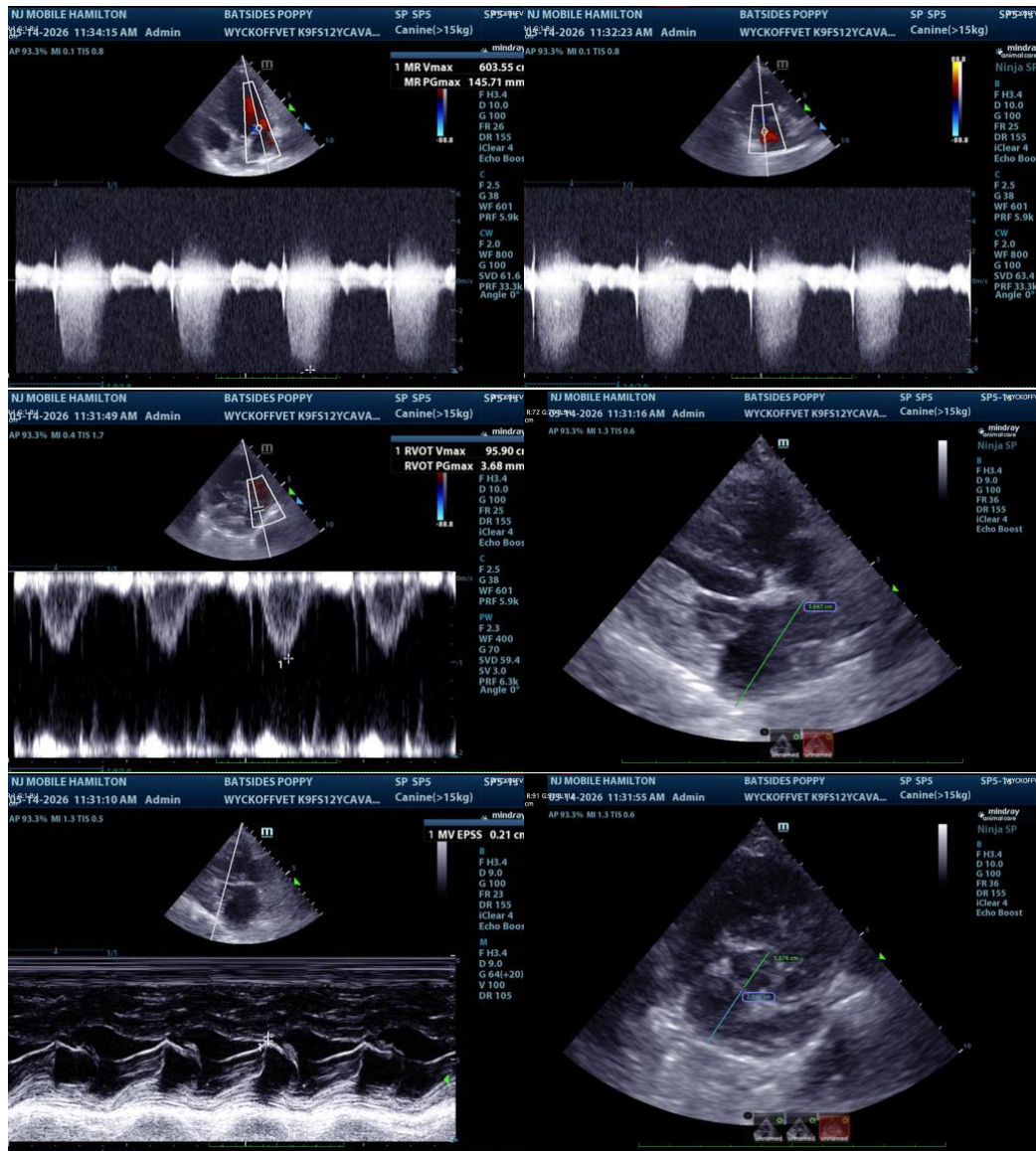
**DATE**

5/14/26

**INTERPRETATION OF THE FINDINGS & FURTHER RECOMMENDATIONS**

No therapy is recommended. Recommend ensuring that systemic hypertension is not present in this patient.

The heart is stable without clinical disease. No overt contraindication for anesthesia of brief to moderate duration. I suggest Torbutrol premed, Propofol induction, Isoflor maintenance or similar protocol if anesthesia is desired. Blood pressure recommended if not already performed and target white coat negative systolic pressure of < 160 mmHg. If higher than this ACE-inhibitor is suggested to reach this level. Recheck echocardiogram is recommended in 6 months, earlier if murmur grade increases or clinical signs initiate.





**PATIENT**

Poppy Batsides

**SPECIES**

Canine

**BREED**

Cavachon

**SEX**

Spayed Female

**AGE**

12 Years 2 Months

**WEIGHT**

28 Pounds

**INTERPRETED BY**

Eric Lindquist, DMV,  
 DABVP (Canine & Feline), Cert. IVUSS

**IMAGING PERFORMED BY**

Rebecca Hamilton

**HOSPITAL NAME**

Wyckoff VH

**REFERRING VET**

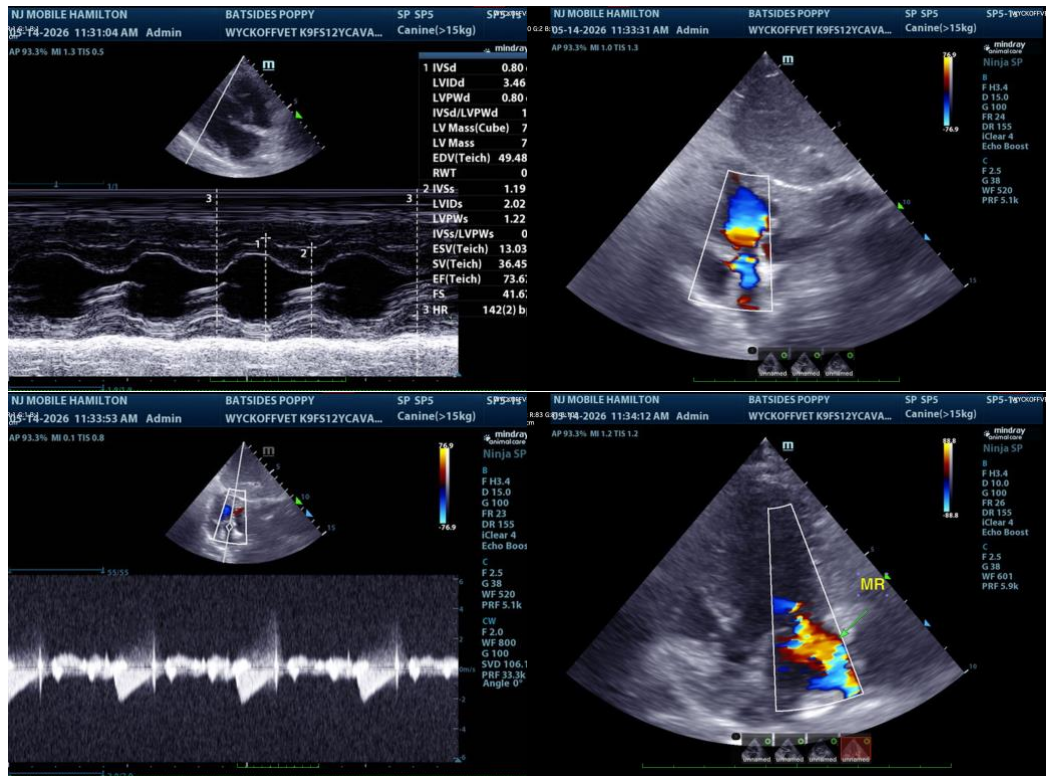
Dr. Eisenberg

**INVOICE**

37118

**DATE**

5/14/26



The information and recommendations provided are based on the images presented by the referring veterinarian/sonographer. No evaluation can be communicated regarding pathology that was not visible in the image/video clips provided.

Thank you for this referral. If the clinical or image interpretation does not parallel your findings or if I can be of any further assistance please contact me.

**Eric Lindquist, DMV, DABVP(CFM), Cert. IVUSS,**  
 CEO, Owner, Founder -- SonoPath.com  
[info@SonoPath.com](mailto:info@SonoPath.com)