



PATIENT

Pepper Daranciang

SPECIES

Canine

BREED

Schnauzer Mix

SEX

Neutered Male

AGE

13

WEIGHT

11.8

INTERPRETED BY

Eric Lindquist, DMV,
DABVP (Canine &
Feline), Cert. IVUSS

IMAGING PERFORMED BY

Jenn

HOSPITAL NAME

Rockaway AH

REFERRING VET

Dr. Maniar

INVOICE

37110

DATE

5/14/26

PRESENTING CLINICAL SIGNS

History: re check MMVD prev u/s 11/12/25 Owner reports doing well , no increased coughing , gained some weight Current meds Pimobendan 1.9mg 1 BID Cough tabs 1/2 tab BID

ULTRASONOGRAPHIC EXAMINATION OF THE HEART

CANINE CARDIAC PARAMETERS	MR VMAX (m/s)	TR VMAX (m/s)	LA/AO (M-Mode)	LA/AO (Heart Base; Swe)	FS (%)	EF (%)	EPSS (cm)
NORMAL PARAMETER	4.5-5.5	<2.7	1.3	Up to 1.6	28-40	40-100	<0.6
PATIENT	6.0	--	1.14	--	--		0.1
CANINE CARDIAC PARAMETERS	HR (BPM)	AV VMAX (m/s)	PV MAX (m/s)	BODY WEIGHT	LAD LA MAX 4 Chamber	LVIDd Avg; 2D and m-mode short axis (cm)	LVIDs Avg; 2D and m-mode short axis (cm)
NORMAL PARAMETER	50-100	0.7-1.7	0.7-1.6				
PATIENT	--	1.30	--	11.8	3.22	2.4	--

Cardiac Presentation

The cardiac presentation presented minimal volume overload in the left heart with prolapse of the anterior mitral valve leaflet and moderate filling of the left atrium. Minor tricuspid insufficiency was noted. The right atrium and right ventricle were unremarkable. Pulmonary and aortic outflows were unremarkable. No evidence of hepatic vein congestion was noted.

ULTRASONOGRAPHIC FINDINGS

- Compensated mitral insufficiency on the current dosing protocol

INTERPRETATION OF THE FINDINGS & FURTHER RECOMMENDATIONS

Recheck echo is recommended in 6 months. Recommend ensuring systemic hypertension is not an issue in this patient.



PATIENT

Pepper Daranciang

SPECIES

Canine

BREED

Schnauzer Mix

SEX

Neutered Male

AGE

13

WEIGHT

11.8

INTERPRETED BY

Eric Lindquist, DMV,
DABVP (Canine &
Feline), Cert. IVUSS

**IMAGING
PERFORMED BY**

Jenn

HOSPITAL NAME

Rockaway AH

REFERRING VET

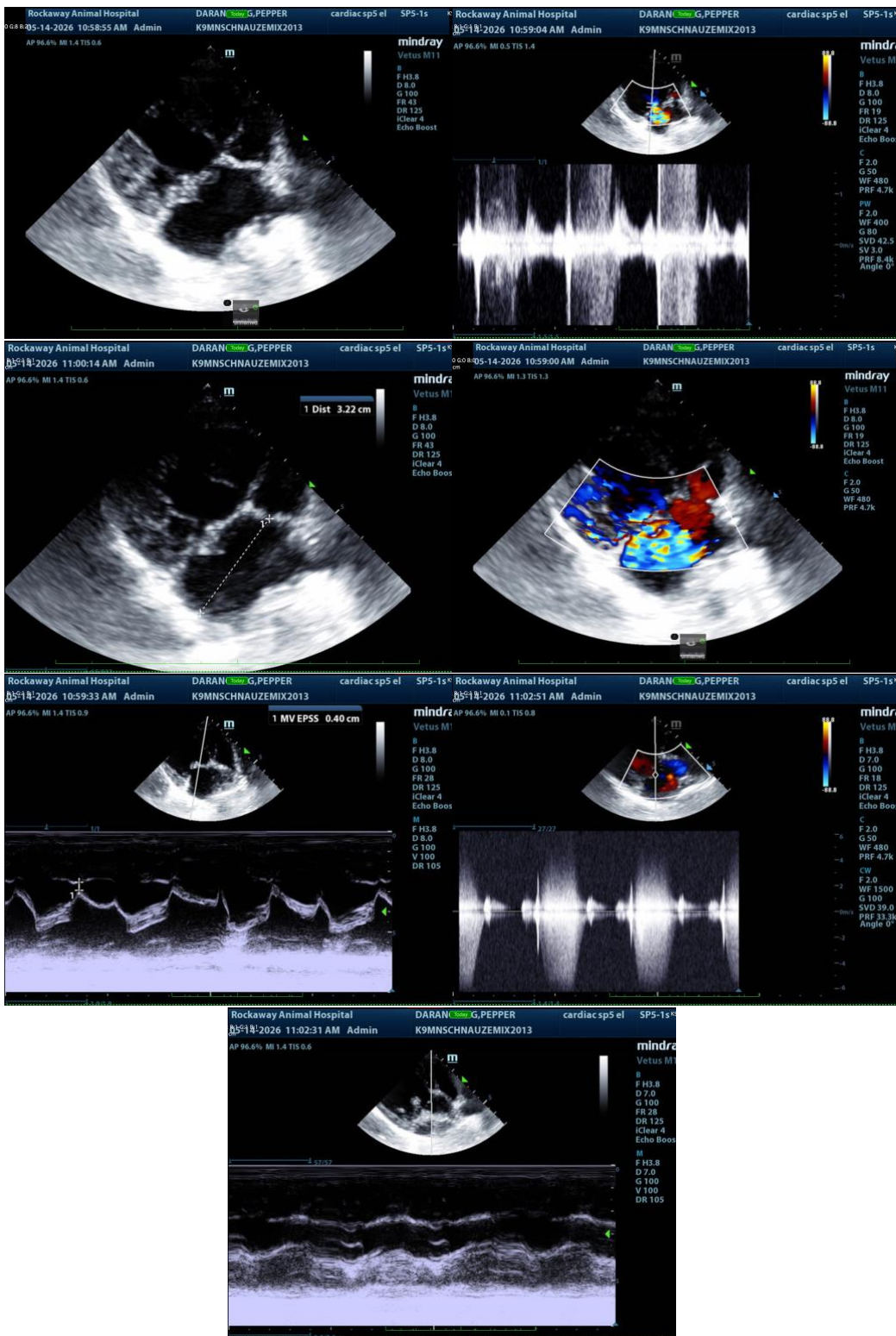
Dr. Maniar

INVOICE

37110

DATE

5/14/26





PATIENT

Pepper Daranciang

SPECIES

Canine

BREED

Schnauzer Mix

SEX

Neutered Male

AGE

13

WEIGHT

11.8

INTERPRETED BY

Eric Lindquist, DMV,
DABVP (Canine &
Feline), Cert. IVUSS

IMAGING PERFORMED BY

Jenn

HOSPITAL NAME

Rockaway AH

REFERRING VET

Dr. Maniar

INVOICE

37110

DATE

5/14/26

The information and recommendations provided are based on the images presented by the referring veterinarian/sonographer. No evaluation can be communicated regarding pathology that was not visible in the image/video clips provided.

Thank you for this referral. If the clinical or image interpretation does not parallel your findings or if I can be of any further assistance please contact me.

Eric Lindquist, DMV, DABVP(CFM), Cert. IVUSS,
CEO, Owner, Founder -- SonoPath.com
info@SonoPath.com