



PATIENT

Nameless Menace
Arachtingi

SPECIES

Feline

BREED

Himalayan Mix

SEX

Neutered male

AGE

12.5 years

WEIGHT

5.1 lbs

INTERPRETED BY

Eric Lindquist, DMV
DABVP, Cert. IVUSS

IMAGING PERFORMED BY

Leah Richter

HOSPITAL NAME

Allied Veterinary
Emergency & Referral

REFERRING VET

Dr. Richter

INVOICE

75537

DATE

5/14/26

PRESENTING CLINICAL SIGNS

History: History of GI issues -- vomiting/diarrhea on and off.

Hx heart murmur (III/VI), FIC, and suspect IVDD.

Abnormal PE/Chem/CBC/JA Results: Grade III/VI heart murmur, otherwise NSF

ULTRASONOGRAPHIC EXAMINATION OF THE ABDOMEN

Urinary System

The **urinary bladder**, trigone, and pelvic urethra presented normal thicknesses and normal tone. The ureters were not visible which is normal. No uroliths or sediment were visualized and anechoic urine was present. No evidence of inflammatory or neoplastic changes was noted. Ureteral papillae were normal.

The **kidneys** revealed largely normal size and structure, corticomedullary definition and ratio (cortex 1/3 of medulla) were essentially maintained with some age-related loss of curvilinear patterns regarding the capsule and C/M junction. The cortices presented largely uniform texture with some increased echogenicity expected for this age patient. Medullary structure differed distinctly from that of the cortex. Slight pyelectasia was noted. The left kidney measured 4.0 cm. The right kidney revealed a cortical infarct at the caudal pole. The infarct is stable and there is no evidence of active inflammation. The right kidney measured 4.0 cm.

Adrenal Glands

Both **adrenal glands** were visualized and recognized as having normal shape, size, position and echogenicity for this breed. The phrenic vasculature, glandular echogenicity and detail were unremarkable. Capsule, cortex, and medullary definition were normal for this age patient. The left and right adrenal gland measured 0.4 cm each.

Spleen

The **spleen** presented a smooth homogeneous parenchyma hyperechoic to liver and renal cortical parenchyma. The capsule was smooth without noticeable expansion or deviation from within the spleen or adjacent pathology. The splenic vasculature demonstrated normal volume without signs of congestion or thrombosis. No sonographic evidence of acute or chronic inflammatory, neoplastic, or infarctual changes was noted.

Liver

The **liver** images submitted revealed subjectively normal liver size, contour, and structure. Parenchymal echogenicity was naturally coarse and hypoechoic to the spleen. Vascular and biliary tracts were of normal volume with no evidence of congestion. The gallbladder presented acceptably thin walls with primarily anechoic content. The cystic and common bile ducts were normal. No pathological hepatic



PATIENT

Nameless Menace
Arachtingi

SPECIES

Feline

BREED

Himalayan Mix

SEX

Neutered male

AGE

12.5 years

WEIGHT

5.1 lbs

INTERPRETED BY

Eric Lindquist, DMV
DABVP, Cert. IVUSS

IMAGING PERFORMED BY

Leah Richter

HOSPITAL NAME

Allied Veterinary
Emergency & Referral

REFERRING VET

Dr. Richter

INVOICE

75537

DATE

5/14/26

lymphadenopathy was evident. No overt structural evidence of inflammatory, infiltrative or regenerative pathology was evident.

Gastrointestinal

Examination of the **gastrointestinal tract** revealed a stomach and intestine free of stasis, of normal wall thickness, acceptable curvilinear mural detail, and peristaltic activity. Small and large intestine demonstrated normal luminal chyme and stool consistency respectively. No obstructive or overt infiltrative disease was noted. No associated abnormal lymphatic activity was noted.

Pancreas

The base and limbs of the **pancreas** were observed to be largely isoechoic to surrounding omental fat. Pancreatic duct and capsular contour were acceptably normal and parenchyma respected normal curvilinear patterns. No overt evidence of active inflammatory or neoplastic disease was noted.

ULTRASONOGRAPHIC FINDINGS

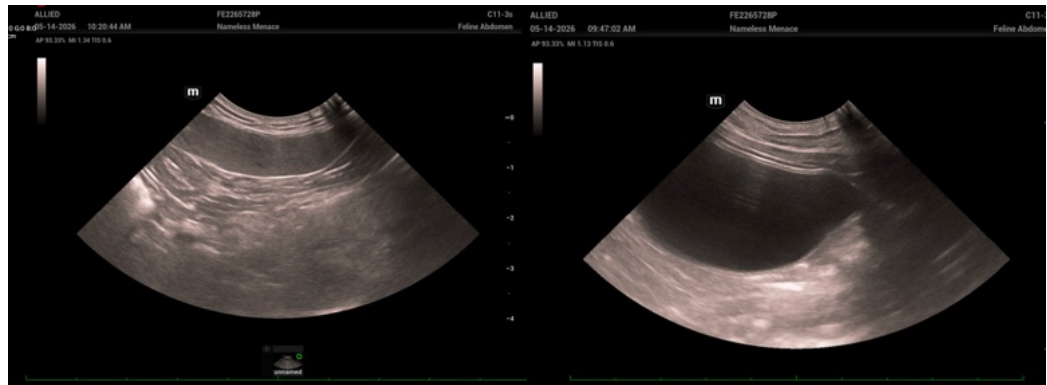
Right renal infarct.

Minor pyelectasia.

INTERPRETATION OF THE FINDINGS & FURTHER RECOMMENDATIONS

There was no evidence of gross disease; however, urinary work-up is indicated to assess for any evidence of UTI.

Dietary indiscretion, food intolerance, structurally significant inflammatory bowel or occult parasitism and occult Addison's are all potentials.





PATIENT

Nameless Menace
Arachtingi

SPECIES

Feline

BREED

Himalayan Mix

SEX

Neutered male

AGE

12.5 years

WEIGHT

5.1 lbs

INTERPRETED BY

Eric Lindquist, DMV
DABVP, Cert. IVUSS

IMAGING PERFORMED BY

Leah Richter

HOSPITAL NAME

Allied Veterinary
Emergency & Referral

REFERRING VET

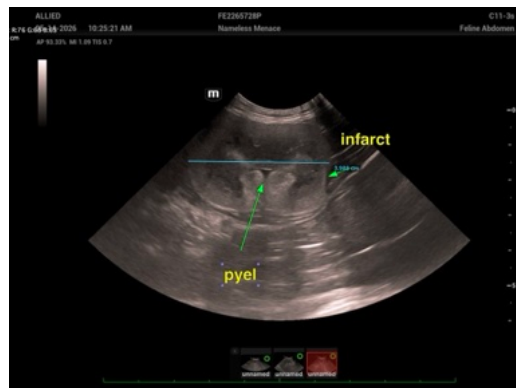
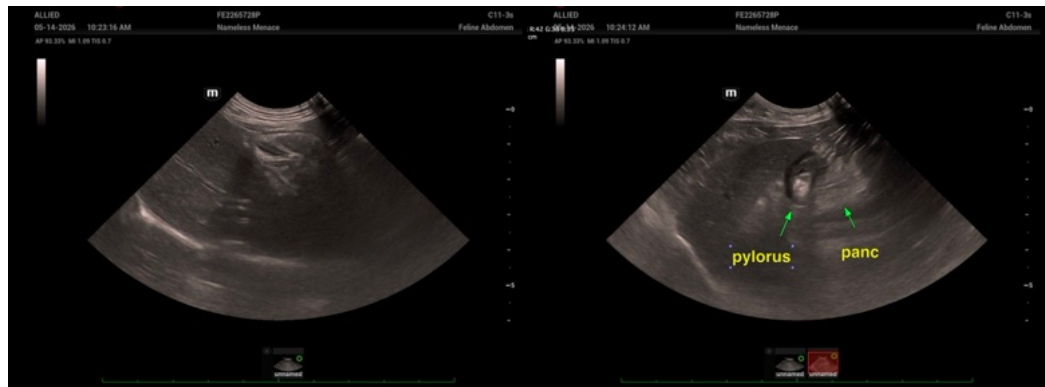
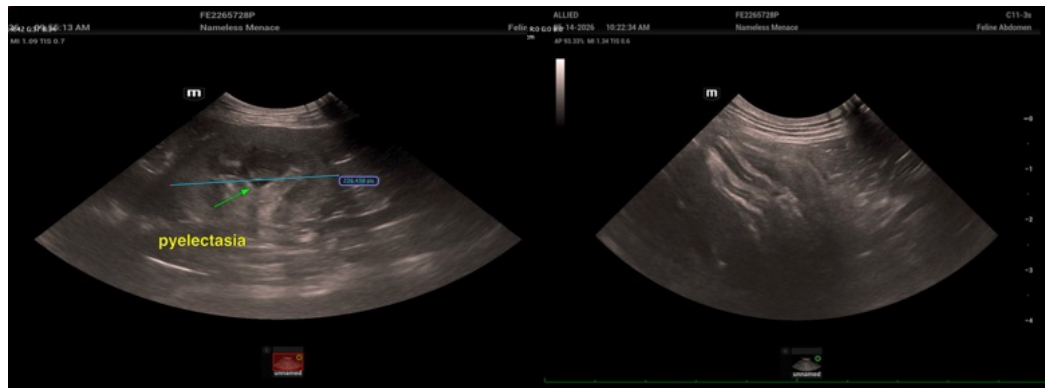
Dr. Richter

INVOICE

75537

DATE

5/14/26



The information and recommendations provided are based on the images presented by the referring veterinarian/sonographer. No evaluation can be communicated regarding pathology that was not visible in the image/video clips provided.

Thank you for this referral. If the clinical or image interpretation does not parallel your findings or if I can be of any further assistance please contact me.

Eric Lindquist, DMV, DABVP (CFM), Cert. IVUSS, CEO of SonoPath.com

info@SonoPath.com