



**PATIENT**

Meridoc Bowen

**SPECIES**

Feline

**BREED**

Persian

**SEX**

Neutered male

**AGE**

5 years

**WEIGHT**

10 lbs

**INTERPRETED BY**

Eric Lindquist, DMV  
DABVP, Cert. IVUSS

**IMAGING PERFORMED BY**

Amy Isaac

**HOSPITAL NAME**

Valley West & Elk  
Valley VH

**REFERRING VET**

Dr. Isaac

**INVOICE**

75555

**DATE**

5/14/26

**PRESENTING CLINICAL SIGNS**

History: Presented for a dental cleaning. New heart murmur ausculted, grade 2 PMI sternal contact. Pro BNP normal. Normal CBC/Chem other than mild hypokalemia and mild neutropenia. ECG normal. No symptoms or complaints at home

**ULTRASONOGRAPHIC EXAMINATION OF THE HEART**

The echocardiogram in this patient demonstrated normal **left atrial** size based on 3 separate LA measurements. The cranial and caudal **mitral** valve leaflets presented normal linear structure and kinetics.. The **left ventricle** presented normal thicknesses with linear contour and was not dilated nor restricted. The **myocardium** presented normal echogenicity without subjective evidence of significant fibrotic or ischemic disease. **Contractility** of the ventricular walls was adequate and in normal range for this patient evidenced by the fractional shortening measurement and subjective evaluation of the different regions and angles of the myocardium. The **left ventricular outflow** tract demonstrated normal laminar flow and subjective structural integrity. The **right atrium** and auricle revealed normal size, structure and content. No evidence of masses was noted or chamber overload. **Tricuspid** valvular assessment demonstrated adequate linear morphology and kinetics. The **right ventricle** was of normal size (1/3 diameter of LV), chordae structure, myocardial echogenicity and thickness. **Pulmonic** tract assessment revealed normal valve structure, laminar flow, and diameter (approx.1:1 pa/ao ratio). No visible **pericardial** or free pleura fluid was noted or extra cardiac pathology in the visible planes. The cranial **mediastinum and pericardial regions** were free of masses in the visible window.

FELINE CARDIAC PARAMETERS	BODY WEIGHT	HR (BPM)	IVSd (cm)	LVIDd (cm)	LVWd (cm)	FS (%)	EF (%)
NORMAL PARAMETER	-----	150-240	0.3-0.6	1.0-2.1	0.25-0.6	35-67	80-100
PATIENT	10 lbs	NM	0.4	1.2	0.45	50	90
FELINE CARDIAC PARAMETERS	LA/AO (M-mode)	LA/AO HEART BASE (Sisson)	LAD LA MAX 4 Chamber		LVOT VEL. (m/s)	RVOT VEL. (m/s)	IVRT (m/)
NORMAL PARAMETER	<1.5	1.6	0.7-1.7		<1.6	<1.3	40-60
PATIENT	1.0	1.3	1.2		-	0.9	NM
Adapted from June Boon, Veterinary Echocardiography, 1998 Sisson D et al. JVIM 1991; 5: 232, Jacobs et al. Am J Vet Res 1985; 46:1705							



**PATIENT**

Meridoc Bowen

**SPECIES**

Feline

**BREED**

Persian

**SEX**

Neutered male

**AGE**

5 years

**WEIGHT**

10 lbs

**INTERPRETED BY**

Eric Lindquist, DMV  
DABVP, Cert. IVUSS

**IMAGING PERFORMED BY**

Amy Isaac

**HOSPITAL NAME**

Valley West & Elk  
Valley VH

**REFERRING VET**

Dr. Isaac

**INVOICE**

75555

**DATE**

5/14/26

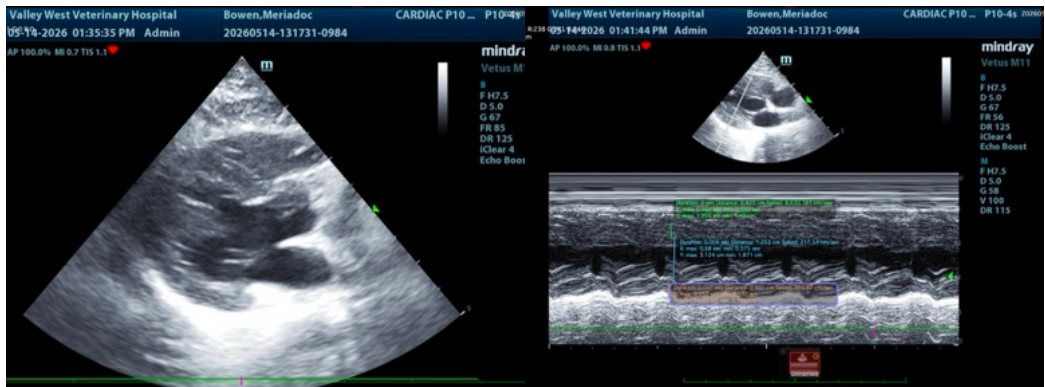
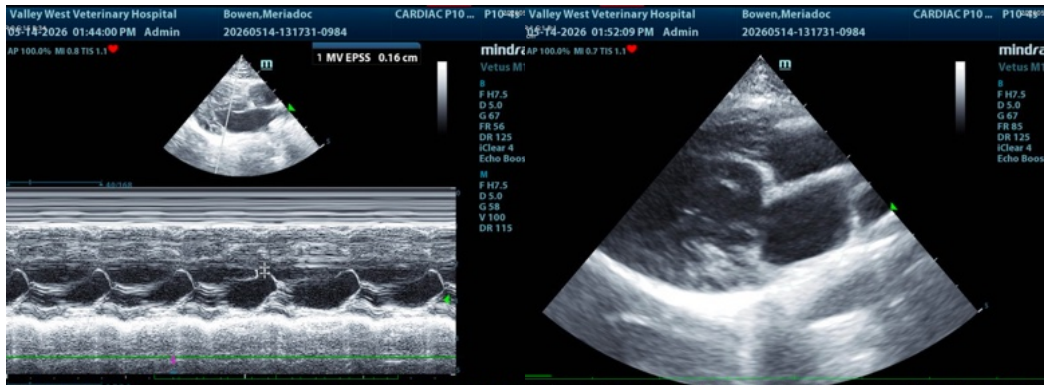
**ULTRASONOGRAPHIC FINDINGS**

Normal echocardiogram, likely flow murmur.

**INTERPRETATION OF THE FINDINGS & FURTHER RECOMMENDATIONS**

There was no evidence of structural or functional disease and no evidence of volume overload or pressure overload.

Benign flow murmurs are common in cats. This may be owing to volume shifts, tachycardia, benign (DRVOTO) right ventricular outflow changes, trivial turbulence in any of the valvular apparatuses, or possibly excessive stethoscope pressure against the chest according to a recent study These are physiologically benign and unrelated to specific pathology.





**PATIENT**

Meridoc Bowen

**SPECIES**

Feline

**BREED**

Persian

**SEX**

Neutered male

**AGE**

5 years

**WEIGHT**

10 lbs

**INTERPRETED BY**

Eric Lindquist, DMV  
DABVP, Cert. IVUSS

**IMAGING PERFORMED BY**

Amy Isaac

**HOSPITAL NAME**

Valley West & Elk  
Valley VH

**REFERRING VET**

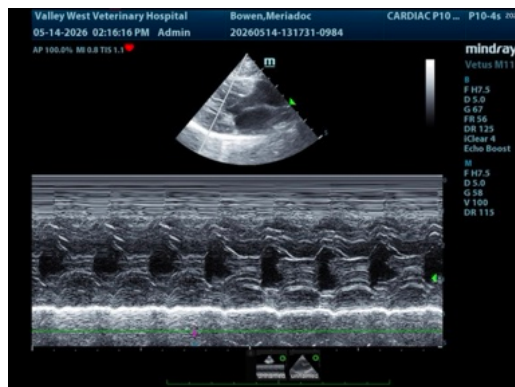
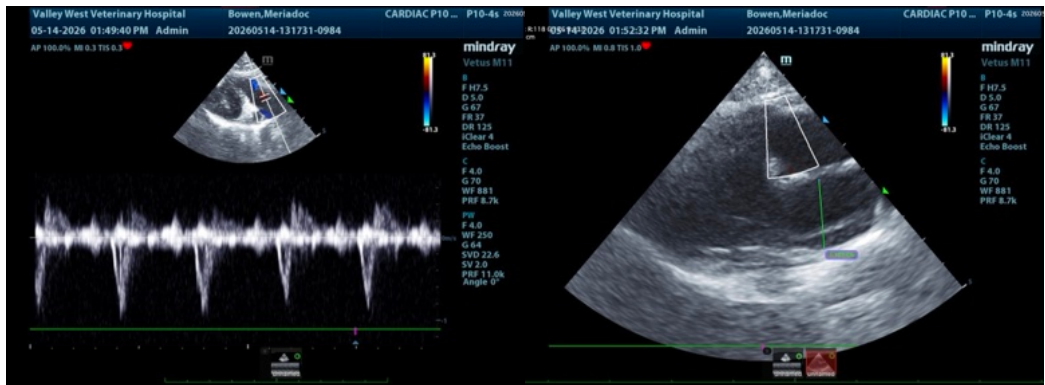
Dr. Isaac

**INVOICE**

75555

**DATE**

5/14/26



The information and recommendations provided are based on the images presented by the referring veterinarian/sonographer. No evaluation can be communicated regarding pathology that was not visible in the image/video clips provided.

Thank you for this referral. If the clinical or image interpretation does not parallel your findings or if I can be of any further assistance please contact me.

Eric Lindquist, DMV, DABVP (CFM), Cert. IVUSS, CEO of SonoPath.com

[info@SonoPath.com](mailto:info@SonoPath.com)