



PATIENT

Emerson Gagne

SPECIES

Canine

BREED

Labrador x

SEX

Castrated

AGE

10

WEIGHT

92

INTERPRETED BY

Eric Lindquist, DMV,
DABVP (CFM), Cert.
IVUSS

IMAGING PERFORMED BY

Dr. Andrew Keller

HOSPITAL NAME

Birch Bark Veterinary
Clinic

REFERRING VET

Dr. Andrew Keller

INVOICE

75141

DATE

5/14/26

PRESENTING CLINICAL SIGNS

Patient presented for left sided abdominal pain, bloated abdomen. Radiographs showed possible mass effect in cranial abdomen, but not definitive.

Abnormal PE/Chem/CBC/UA Results: Overweight, moderately uncomfortable on abdominal palpation

ULTRASONOGRAPHIC EXAMINATION OF THE ABDOMEN

Urinary System

The **urinary bladder**, trigone, and pelvic urethra presented normal thicknesses and normal tone. The ureters were not visible which is normal. No uroliths or sediment were visualized and anechoic urine was present. No evidence of inflammatory or neoplastic changes were noted. Ureteral papillae were normal. The pelvic urethra was imaged 2.0 cm beyond the cystourethral junction.

The **kidneys** revealed largely normal size and structure, corticomedullary definition and ratio (cortex 1/3 of medulla) were essentially maintained with some age-related loss of curvilinear patterns regarding the capsule and C/M junction. The cortices presented largely uniform texture with some increased echogenicity expected for his age patient. Medullary structure differed distinctly from that of the cortex and no evidence of pelvic dilation was present. Right kidney measured 6.0 cm. Left kidney measured 7.0 cm.

Adrenal Glands

The regions of the **adrenal glands** were imaged, no evident pathology.

Spleen

The **spleen** presented a smooth homogeneous parenchyma hyperechoic to liver and renal cortical parenchyma. The capsule was smooth without noticeable expansion or deviation from within the spleen or adjacent pathology. The splenic vasculature demonstrated normal volume without signs of congestion or thrombosis. No sonographic evidence of acute or chronic inflammatory, neoplastic, or infarctual changes were noted.

The cranial pole of the spleen is superimposed upon the liver and may be creating a mass effect. No overt masses noted.

Liver

The **liver** images from right and left intercostal as well as subcostal views revealed subjectively normal liver size, contour, and structure. Some age-related parenchymal remodeling was noted but likely not clinically significant at this time. Vascular and biliary tracts were of normal volume and no evidence of congestion was noted. The gallbladder presented some dependent debris with essentially normal contour. The cystic and common bile ducts were normal. No overt evidence of active inflammatory, infiltrative or regenerative pathology was noted but should be paired with current or past LE elevations regarding any clinical significance to this presentation. The hepatic lymph nodes were unremarkable.

Gastrointestinal

Examination of the **gastrointestinal tract** revealed a stomach and intestine free of stasis, of normal wall thickness, acceptable curvilinear mural detail, and peristaltic activity. Small and large intestine



PATIENT

Emerson Gagne

SPECIES

Canine

BREED

Labrador x

SEX

Castrated

AGE

10

WEIGHT

92

INTERPRETED BY

Eric Lindquist, DMV,
DABVP (CFM), Cert.
IVUS

IMAGING PERFORMED BY

Dr. Andrew Keller

HOSPITAL NAME

Birch Bark Veterinary
Clinic

REFERRING VET

Dr. Andrew Keller

INVOICE

75141

DATE

5/14/26

demonstrated normal luminal chyme and stool consistency respectively. No obstructive or overt infiltrative disease was noted. No associated abnormal lymphatic activity was noted.

Pancreas

The base and limbs of the **pancreas** were observed to be largely isoechoic to surrounding omental fat. Pancreatic duct and capsular contour were acceptably normal and parenchyma respected normal curvilinear patterns. No overt evidence of active inflammatory or neoplastic disease was noted.

Free Abdomen

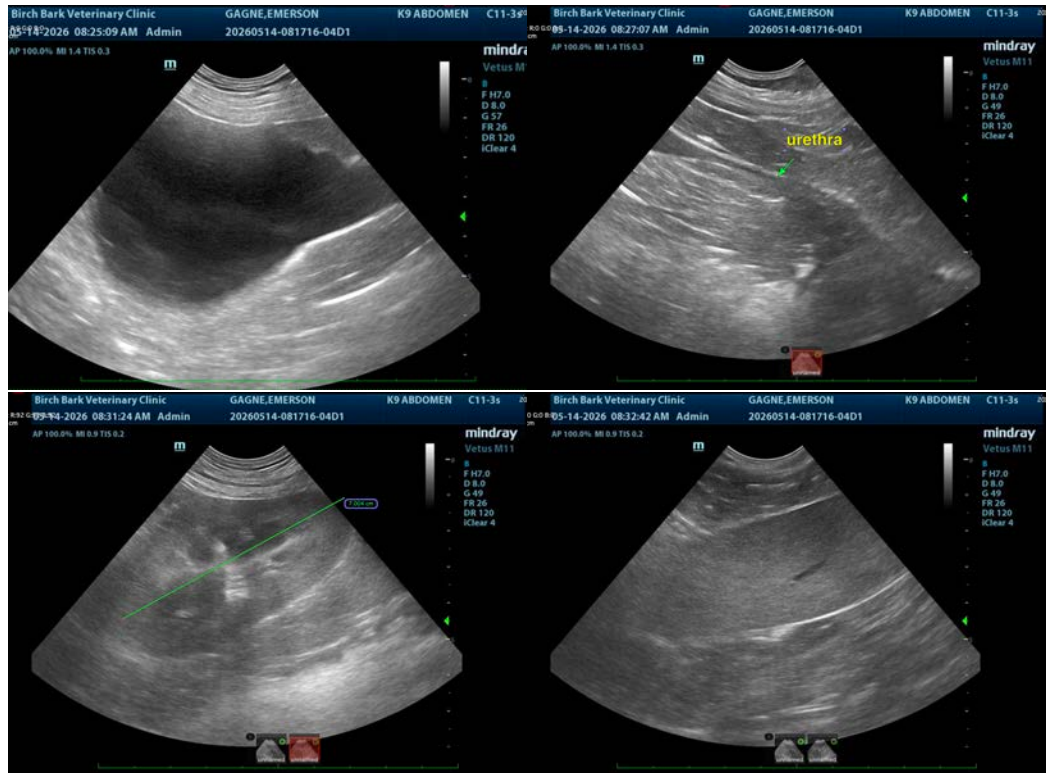
Large amount of abdominal fat noted in this patient.

ULTRASONOGRAPHIC FINDINGS

- Age related abdominal changes with large amount of abdominal fat.

INTERPRETATION OF THE FINDINGS & FURTHER RECOMMENDATIONS

No evidence of neoplasia. Weight loss protocol recommended.





PATIENT

Emerson Gagne

SPECIES

Canine

BREED

Labrador x

SEX

Castrated

AGE

10

WEIGHT

92

INTERPRETED BY

Eric Lindquist, DMV,
DABVP (CFM), Cert.
IVUSS

IMAGING PERFORMED BY

Dr. Andrew Keller

HOSPITAL NAME

Birch Bark Veterinary
Clinic

REFERRING VET

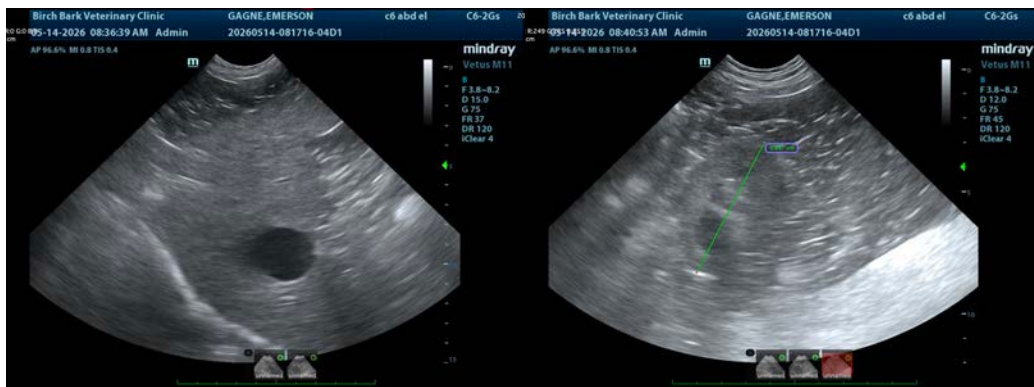
Dr. Andrew Keller

INVOICE

75141

DATE

5/14/26



The information and recommendations provided are based on the images presented by the referring veterinarian/sonographer. No evaluation can be communicated regarding pathology that was not visible in the image/video clips provided.

Thank you for this referral. If the clinical or image interpretation does not parallel your findings or if I can be of any further assistance please contact me.

Eric Lindquist, DMV, DABVP(CFM), Cert. IVUSS,
CEO, Owner, Founder -- SonoPath.com
info@SonoPath.com