

PATIENT

Cooper Dubbs-Corbin

SPECIES

Canine

BREED

Havanese

SEX

Spayed Female

AGE

13 Years 4 Months

WEIGHT

15 Pounds

INTERPRETED BY

Eric Lindquist, DMV,
DABVP (Canine &
Feline), Cert. IVUSS

IMAGING PERFORMED BY

Chloe Lowe, CVT

HOSPITAL NAME

William Penn VH

REFERRING VET

Dr. Bouzaout

INVOICE

37112

DATE

5/14/26

PRESENTING CLINICAL SIGNS

History: Cardiomegaly. Phenobarbital, thyro tabs 0.2
Abnormal PE/Chem/CBC/UA Results: Total T4 0.6, Free T4 0.4, Free T4 5.1, Alp 963, Alb 4.0, Total Protein 7.7, Chlor 107, Plt 685, RDW 19.2

ULTRASONOGRAPHIC EXAMINATION OF THE HEART

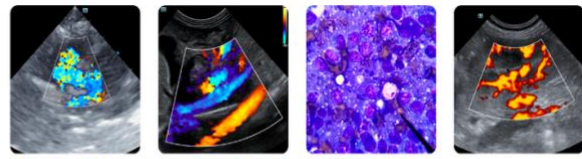
CANINE CARDIAC PARAMETERS	MR VMAX (m/s)	TR VMAX (m/s)	LA/AO (M-Mode)	LA/AO (Heart Base; Swe)	FS (%)	EF (%)	EPSS (cm)
NORMAL PARAMETER	4.5-5.5	<2.7	1.3	Up to 1.6	28-40	40-100	<0.6
PATIENT	--	--	1.1	1.1	25	52	0.1
CANINE CARDIAC PARAMETERS	HR (BPM)	AV VMAX (m/s)	PV MAX (m/s)	BODY WEIGHT	LAD LA MAX 4 Chamber	LVIDd Avg; 2D and m-mode short axis (cm)	LVIDs Avg; 2D and m-mode short axis (cm)
NORMAL PARAMETER	50-100	0.7-1.7	0.7-1.6				
PATIENT	149	1.30	.77	15	2.78	1.78	--

E-wave velocity: 0.7, La/Ra ratio: approximately 1:1

Cardiac Presentation

The **echocardiogram** presented a prominent **right heart** with mild **right ventricular** hypertrophy, without significant **tricuspid** regurgitation (tricuspid doppler was unremarkable), and normal **right atrial** size. No evidence of neoplasia was noted in the right auricle, or elsewhere in the heart. The **pulmonary artery** was uniformly prominent with mildly depressed pulmonic velocity measured on PW Doppler. No overt heartworms were noted in the main or visible deep pulmonary arteries. Yet theoretically heartworms could be present in the deep pulmonary vasculature out of visible sonographic range. More likely, however, this prominent right heart is due to excessive intra-thoracic pressures caused by chronic respiratory disease or potentially excessive intra-thoracic fat (Pickwickian syndrome). The **left heart** demonstrated a linear **ventricular septum**. Contractility was functionally adequate demonstrated by the FS% measurement. Minor centralized **mitral** insufficiency was noted. No significant **left atrial** dilation was noted. The **left ventricular outflow** demonstrated normal flow patterns and velocities through the aortic valve. No evidence of tumor, pericardial or pleural effusion was noted. The visible **extra-cardiac** tissues were uniformly linear without evidence of masses, infiltrative or inflammatory mediastinal tissue. No evident arrhythmic activity was noted during the exam. The hepatic veins were not dilated.

ULTRASONOGRAPHIC FINDINGS



PATIENT

Cooper Dubbs-Corbin

SPECIES

Canine

BREED

Havanese

SEX

Spayed Female

AGE

13 Years 4 Months

WEIGHT

15 Pounds

INTERPRETED BY

Eric Lindquist, DMV,
 DABVP (Canine &
 Feline), Cert. IVUSS

IMAGING PERFORMED BY

Chloe Lowe, CVT

HOSPITAL NAME

William Penn VH

REFERRING VET

Dr. Bouzaout

INVOICE

37112

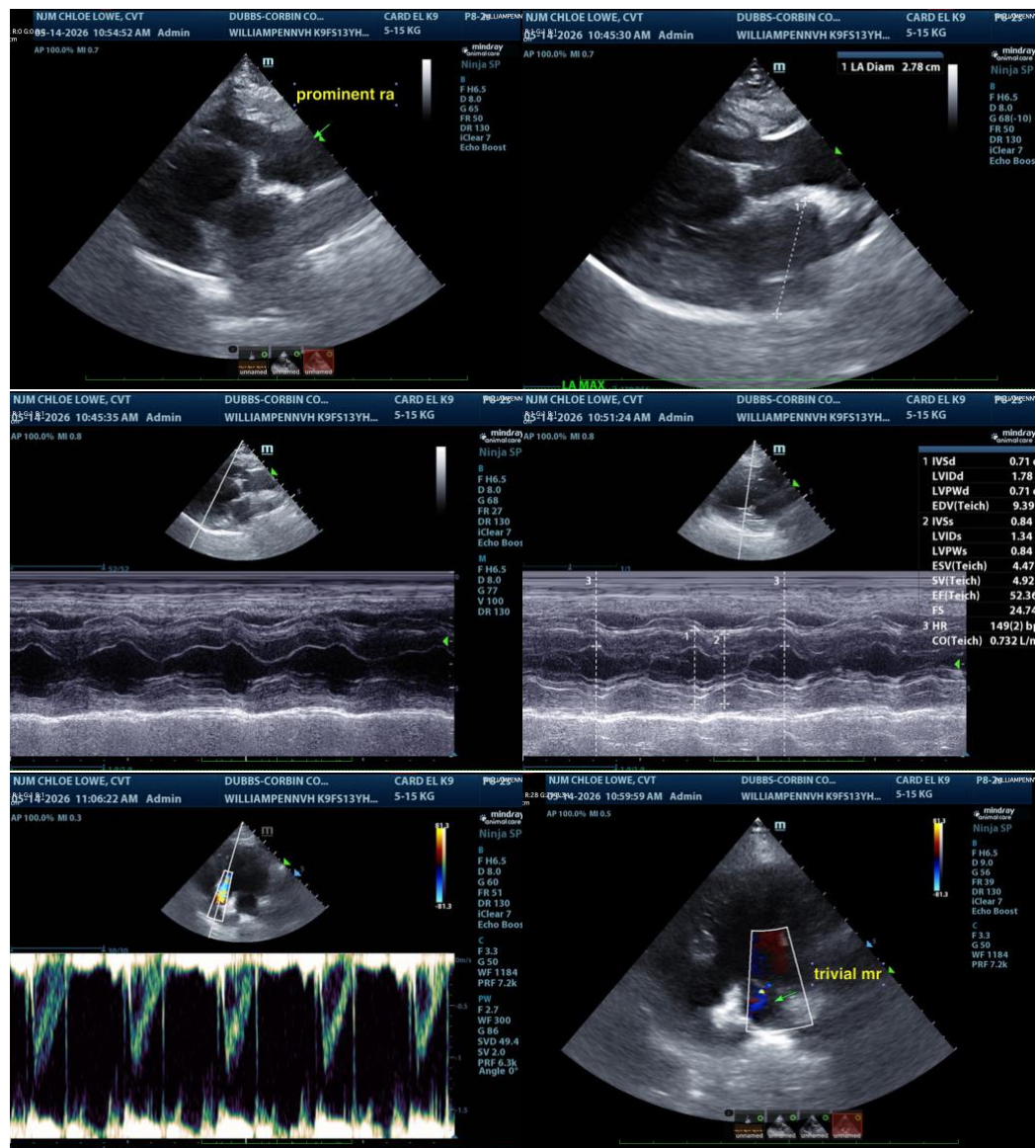
DATE

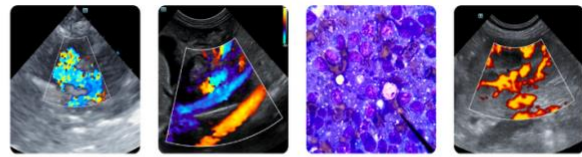
5/14/26

- Mild cor pulmonale pattern with normal left sided cardiac presentation
- Conformational right sided enlargement or potentially owing to increased thoracic pressures, yet no evidence of clinical pulmonary hypertension at this time.
- Trivial mitral insufficiency, not clinically significant
- No volume overload of the left heart

INTERPRETATION OF THE FINDINGS & FURTHER RECOMMENDATIONS

No evidence of clinical disease. No therapy is recommended at this time. Given the hepatomegaly and liver enzyme elevation, abdominal sonogram is recommended if not already performed.





Clinical Sonography & Teletcytology
 Educational Teleconsultation Services™

SonoPath www.SonoPath.com
 info@sonopath.com 800.838.4268

PATIENT

Cooper Dubbs-Corbin

SPECIES

Canine

BREED

Havanese

SEX

Spayed Female

AGE

13 Years 4 Months

WEIGHT

15 Pounds

INTERPRETED BY

Eric Lindquist, DMV,
 DABVP (Canine &
 Feline), Cert. IVUSS

IMAGING PERFORMED BY

Chloe Lowe, CVT

HOSPITAL NAME

William Penn VH

REFERRING VET

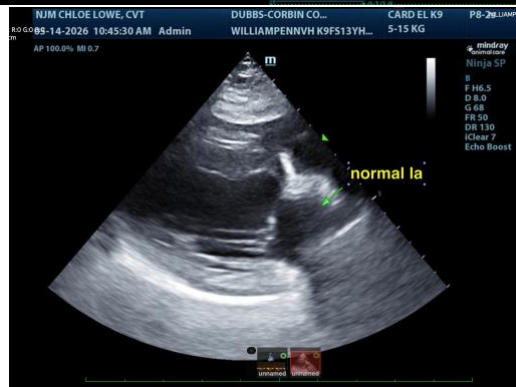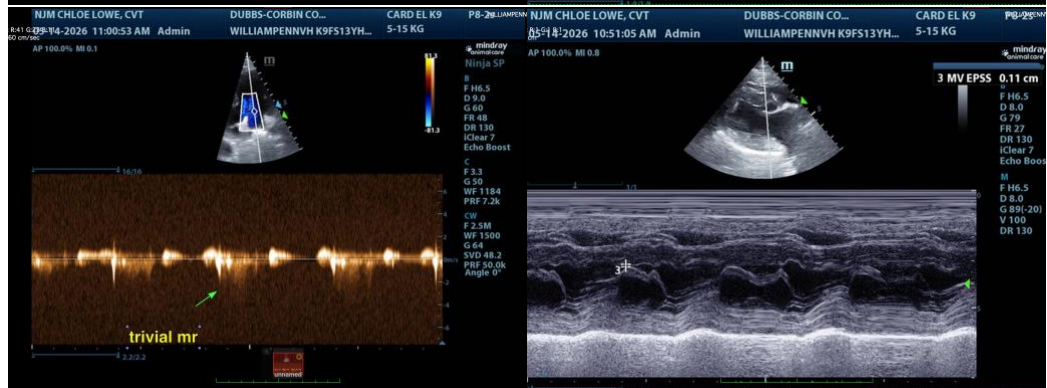
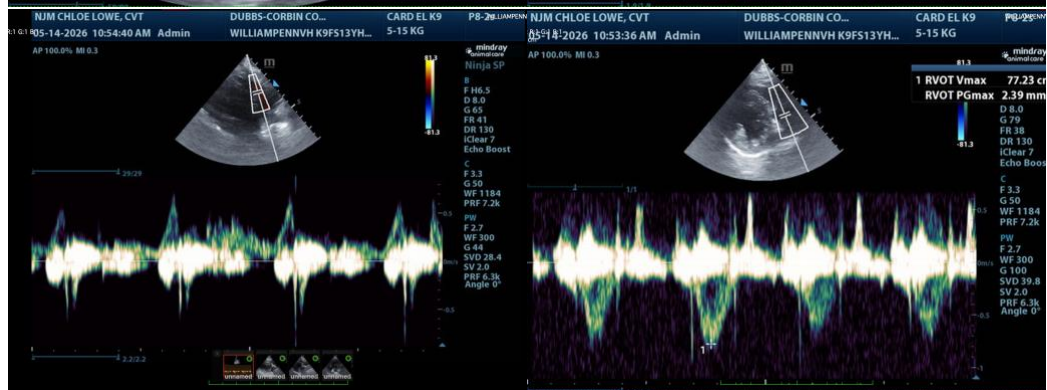
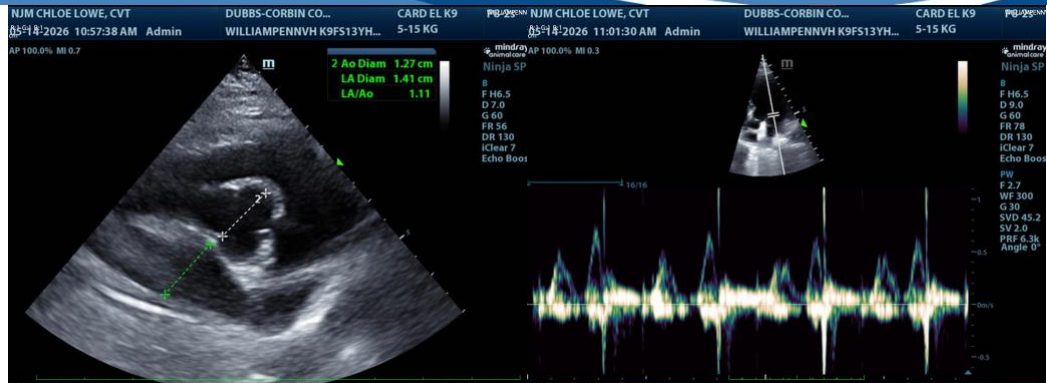
Dr. Bouzaout

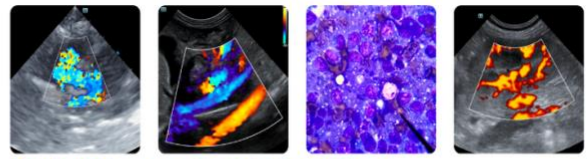
INVOICE

37112

DATE

5/14/26





PATIENT

Cooper Dubbs-Corbin

SPECIES

Canine

BREED

Havanese

SEX

Spayed Female

AGE

13 Years 4 Months

WEIGHT

15 Pounds

INTERPRETED BY

Eric Lindquist, DMV,
DABVP (Canine &
Feline), Cert. IVUSS

**IMAGING
PERFORMED BY**

Chloe Lowe, CVT

HOSPITAL NAME

William Penn VH

REFERRING VET

Dr. Bouzaout

INVOICE

37112

DATE

5/14/26

The information and recommendations provided are based on the images presented by the referring veterinarian/sonographer. No evaluation can be communicated regarding pathology that was not visible in the image/video clips provided.

Thank you for this referral. If the clinical or image interpretation does not parallel your findings or if I can be of any further assistance please contact me.

Eric Lindquist, DMV, DABVP(CFM), Cert. IVUSS,
CEO, Owner, Founder -- SonoPath.com
info@SonoPath.com