



**PATIENT**

Mia Rosario

**PRESENTING CLINICAL SIGNS**

History: CHF. Current medications - Vetmedin 1.25mg 1/2 BID, Furosemide 7mg q12hr

**SPECIES**

Canine

**ULTRASONOGRAPHIC EXAMINATION OF THE HEART**

**BREED**

Yorkie Poo

**SEX**

Spayed Female

**AGE**

9 Years 9 Months

**WEIGHT**

6.9

CANINE CARDIAC PARAMETERS	MR VMAX (m/s)	TR VMAX (m/s)	LA/AO (M-Mode)	LA/AO (Heart Base; Swe)	FS (%)	EF (%)	EPSS (cm)
NORMAL PARAMETER	4.5-5.5	<2.7	1.3	Up to 1.6	28-40	40-100	<0.6
PATIENT	5.0	2.8	1.5	1.7	56	88	0.1
CANINE CARDIAC PARAMETERS	HR (BPM)	AV VMAX (m/s)	PV MAX (m/s)	BODY WEIGHT	LAD LA MAX 4 Chamber	LVIDd Avg; 2D and m-mode short axis (cm)	LVIDs Avg; 2D and m-mode short axis (cm)
NORMAL PARAMETER	50-100	0.7-1.7	0.7-1.6				
PATIENT	202	4.0	1.50	6.9	2.8	2.78	--

**INTERPRETED BY**

Eric Lindquist, DMV, DABVP (Canine & Feline), Cert. IVUSS

**Cardiac Presentation**

Mild volume overload was noted in the left atrium. Left ventricular hypertrophy was noted. Centralized mitral insufficiency was noted. EPSS was normal. Contractility was adequate. Aortic velocity was excessive at 3.5 m/s. The right heart revealed a prominent pulmonary artery, and the deep pulmonary artery revealed a holosystolic flow (holosystolic jet confirmed by spectral doppler) at the level of the pulmonary bifurcation, strong concern for PDA. Tricuspid insufficiency was noted.

**IMAGING PERFORMED BY**

Vincent Ravancho, CVT

**HOSPITAL NAME**

Ridge Road AH

**ULTRASONOGRAPHIC FINDINGS**

- Compensatory or pseudo stenosis of the left ventricular outflow tract is likely, with the excessive velocity, however, structurally the aortic valve appeared unremarkable. The excessive LVOT velocity is likely owing to PDA status.

**REFERRING VET**

Dr. Pathak

**INTERPRETATION OF THE FINDINGS & FURTHER RECOMMENDATIONS**

Recommend reassessment of the clinical status with a left cranial auscultation for holosystolic jet and referral to interventional cardiologist for further definition.

**INVOICE**

37108

**DATE**

5/13/26



**PATIENT**

Mia Rosario

**SPECIES**

Canine

**BREED**

Yorkie Poo

**SEX**

Spayed Female

**AGE**

9 Years 9 Months

**WEIGHT**

6.9

**INTERPRETED BY**

Eric Lindquist, DMV,  
 DABVP (Canine &  
 Feline), Cert. IVUSS

**IMAGING  
 PERFORMED BY**

Vincent Ravancho,  
 CVT

**HOSPITAL NAME**

Ridge Road AH

**REFERRING VET**

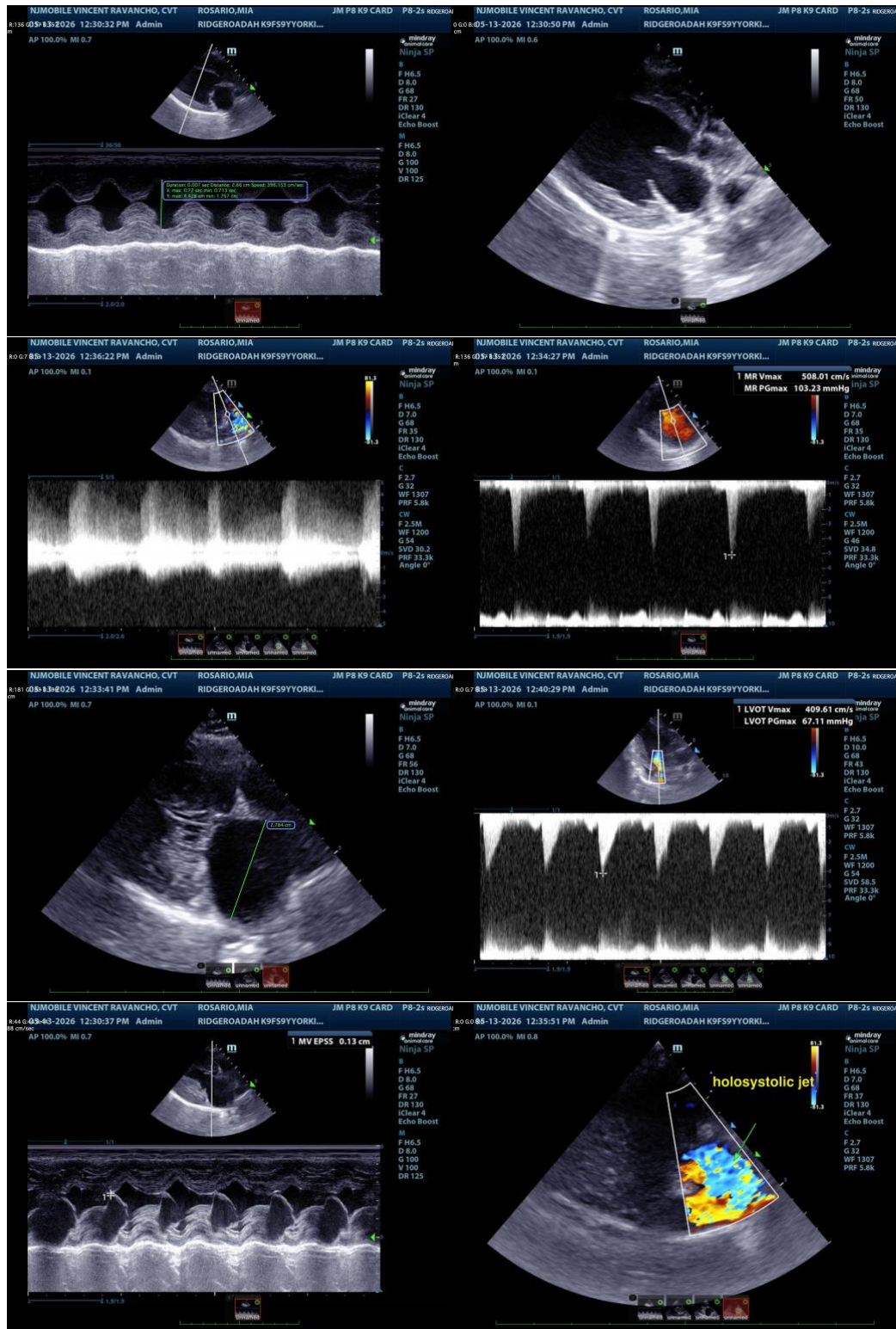
Dr. Pathak

**INVOICE**

37108

**DATE**

5/13/26





**PATIENT**

Mia Rosario

**SPECIES**

Canine

**BREED**

Yorkie Poo

**SEX**

Spayed Female

**AGE**

9 Years 9 Months

**WEIGHT**

6.9

**INTERPRETED BY**

Eric Lindquist, DMV,  
 DABVP (Canine & Feline), Cert. IVUSS

**IMAGING PERFORMED BY**

Vincent Ravancho,  
 CVT

**HOSPITAL NAME**

Ridge Road AH

**REFERRING VET**

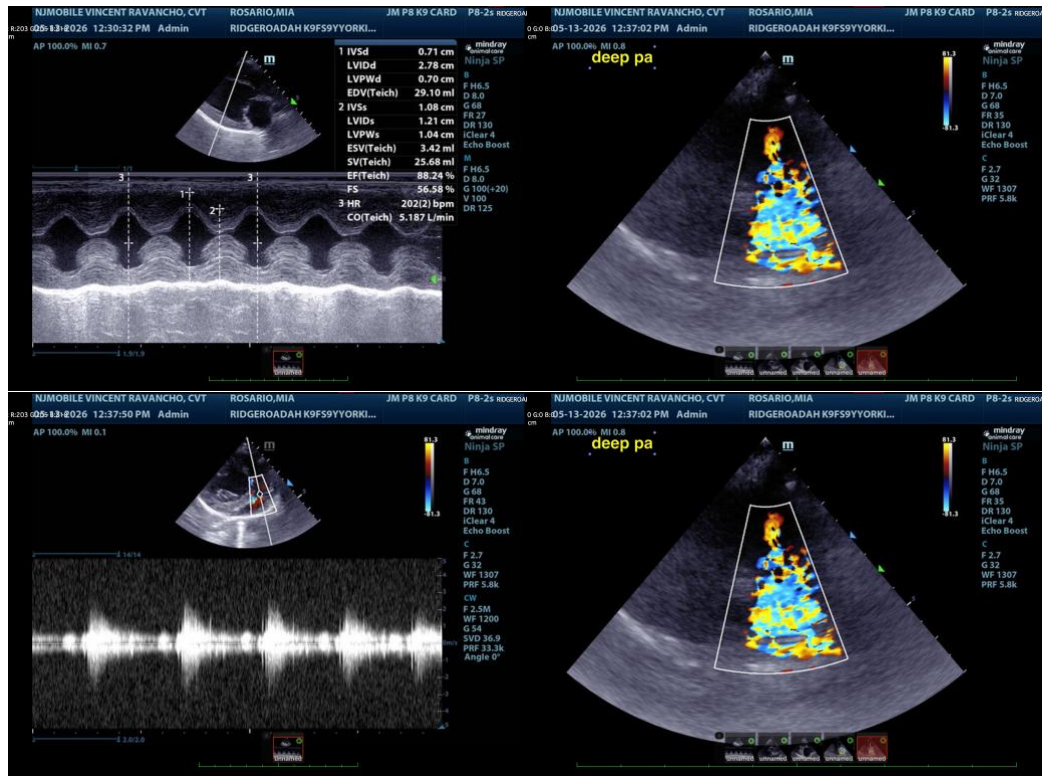Dr. Pathak

**INVOICE**

37108

**DATE**

5/13/26



The information and recommendations provided are based on the images presented by the referring veterinarian/sonographer. No evaluation can be communicated regarding pathology that was not visible in the image/video clips provided.

Thank you for this referral. If the clinical or image interpretation does not parallel your findings or if I can be of any further assistance please contact me.

**Eric Lindquist, DMV, DABVP(CFM), Cert. IVUSS,**  
 CEO, Owner, Founder -- SonoPath.com  
[info@SonoPath.com](mailto:info@SonoPath.com)