

PATIENT

Chicory Brailsford

SPECIES

Feline

BREED

DSH

SEX

Spayed Female

AGE

13 Years

WEIGHT

7.15 lbs

INTERPRETED BY

Eric Lindquist, DMV,
DABVP(CFM), Cert.
IVUSS

IMAGING PERFORMED BY

Dr. Renee Ziegler-Post

HOSPITAL NAME

For Cats Only
Veterinary Clinic

REFERRING VET

Dr. Renee Ziegler-Post

INVOICE

16174

DATE

05/13/26

PRESENTING CLINICAL SIGNS

Current meds: phosphate binder, potassium supplement, B12, anti-nausea med, Mirataz (some specific names/doses not provided). Current bloodwork: 5/13 electrolytes Na 167, K 5.8, Cl 127 ; T4 1.1

5/5 BUN 114, Crea 6.1. Current blood pressure: 139/103, 141/102, 140/101, 139/105, 142/97. Current CXR: pleural effusion, cranioventral concentration, appears predom right side. US guided thoracocentesis - draw small amount turbid/~opaque white fluid

ULTRASONOGRAPHIC EXAMINATION OF THE HEART

FELINE CARDIAC PARAMETERS	BODY WEIGHT (lbs)	HR (BPM)	IVSd (cm)	LVIDd (cm)	LVWd (cm)	FS (%)	EF (%)
NORMAL PARAMETER	-----	150-240	0.3-0.6	1.0-2.1	0.25-0.6	35-67	80-100
PATIENT	7.15	NM	0.51	1.46	0.6	57	90
FELINE CARDIAC PARAMETERS	LA/AO (M-mode)	LA/AO HEART BASE (Sisson)	LAD LA MAX 4 Chamber	LVOT VEL. (m/s)	RVOT VEL. (m/s)	IVRT (m/)	
NORMAL PARAMETER	<1.5	1.6	0.7-1.7	<1.6	<1.3	40-60	
PATIENT	1.4	--	1.3	--	--	NM	
Adapted from June Boon, Veterinary Echocardiography, 1998 Sisson D et al. JVIM 1991; 5: 232, Jacobs et al. Am J Vet Res 1985; 46:1705							

Cardiac Presentation

The echocardiogram in this patient demonstrated normal **left atrial** size based on 3 separate LA measurements. The cranial and caudal **mitral** valve leaflets presented normal linear structure and kinetics.. The **left ventricle** presented normal thicknesses with linear contour and was not dilated nor restricted. The **myocardium** presented normal echogenicity without subjective evidence of significant fibrotic or ischemic disease. **Contractility** of the ventricular walls was adequate and in normal range for this patient evidenced by the fractional shortening measurement and subjective evaluation of the different regions and angles of the myocardium. The **left ventricular outflow** tract demonstrated normal laminar flow and subjective structural integrity. The **right atrium** and auricle were mildly enlarged yet this is likely owing to excessive extra cardiac thoracic pressures. **Tricuspid** valvular assessment demonstrated adequate linear morphology and kinetics. The **right ventricle** was of normal size (1/3 diameter of LV), chordae structure, myocardial echogenicity and thickness. **Pulmonic** tract assessment revealed normal valve structure, laminar flow, and diameter (approx.1:1 pa/ao ratio). No visible **pericardial** fluid was noted or extra cardiac pathology in the visible planes. The cranial **mediastinum and pericardial regions** were free of masses in the visible window. Noncardiogenic pleural effusion was noted in this patient.

ULTRASONOGRAPHIC FINDINGS



PATIENT

Chicory Brailsford

SPECIES

Feline

BREED

DSH

SEX

Spayed Female

AGE

13 Years

WEIGHT

7.15 lbs

INTERPRETED BY

Eric Lindquist, DMV,
DABVP(CFM), Cert.
IVUSS

IMAGING PERFORMED BY

Dr. Renee Ziegler-Post

HOSPITAL NAME

For Cats Only
Veterinary Clinic

REFERRING VET

Dr. Renee Ziegler-Post

INVOICE

16174

DATE

05/13/26

- Noncardiogenic pleural effusion.
- Prominent right heart owing to noncardiac thoracic disease.

INTERPRETATION OF THE FINDINGS & FURTHER RECOMMENDATIONS

Differentials include occult neoplasia such as lymphomatosis, especially given the chyle formation. Abdominal sonogram is recommended if not already performed to assess for primary disease that may be metastatic to the chest. Idiopathic chylothorax is also possible. Chest CT, cytospin of a fresh pleurocentesis sample with immediate slide preparation is warranted to assess for exfoliating neoplasia. I do not believe that there is a primary cardiac component in this patient.



PATIENT

Chicory Brailsford

SPECIES

Feline

BREED

DSH

SEX

Spayed Female

AGE

13 Years

WEIGHT

7.15 lbs

INTERPRETED BY

Eric Lindquist, DMV,
DABVP(CFM), Cert.
IVUSS

**IMAGING
PERFORMED BY**

Dr. Renee Ziegler-Post

HOSPITAL NAME

For Cats Only
Veterinary Clinic

REFERRING VET

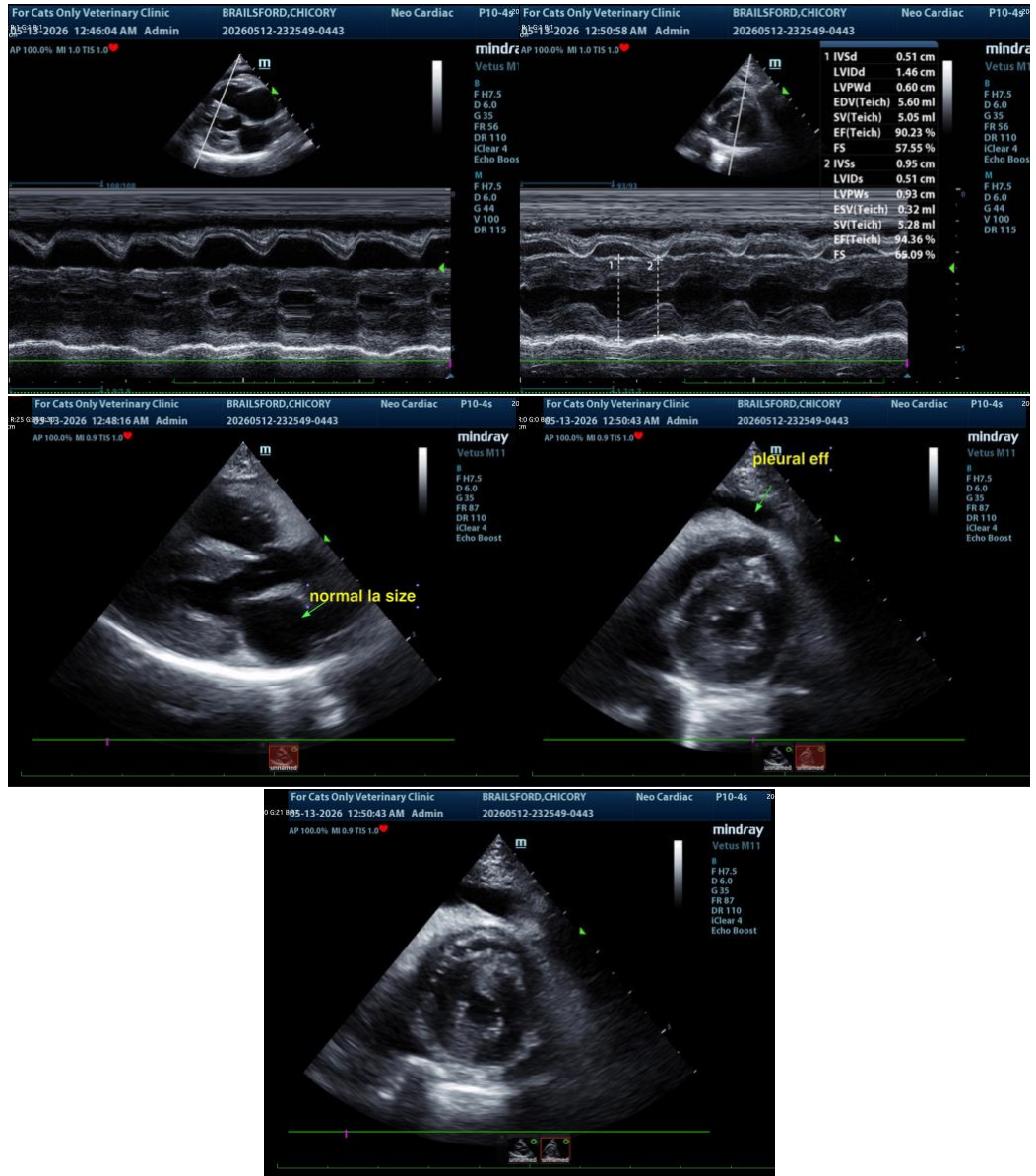
Dr. Renee Ziegler-Post

INVOICE

16174

DATE

05/13/26



The information and recommendations provided are based on the images presented by the referring veterinarian/sonographer. No evaluation can be communicated regarding pathology that was not visible in the image/video clips provided.

Thank you for this referral. If the clinical or image interpretation does not parallel your findings or if I can be of any further assistance, please contact me.

Eric Lindquist, DMV, DABVP(CFM), Cert. IVUSS,

CEO, Owner, Founder -- SonoPath.com

info@SonoPath.com



PATIENT

Chicory Brailsford

SPECIES

Feline

BREED

DSH

SEX

Spayed Female

AGE

13 Years

WEIGHT

7.15 lbs

INTERPRETED BY

Eric Lindquist, DMV,
DABVP(CFM), Cert.
IVUSS

IMAGING PERFORMED BY

Dr. Renee Ziegler-Post

HOSPITAL NAME

For Cats Only
Veterinary Clinic

REFERRING VET

Dr. Renee Ziegler-Post

INVOICE

16174

DATE

05/13/26