

PATIENT

Charlie Ellis

SPECIES

Canine

BREED

Standard Poodle

SEX

Neutered Male

AGE

11 Years

WEIGHT

58.6

INTERPRETED BY

Eric Lindquist, DMV,
DABVP (CFM), Cert.
IVUSS

IMAGING PERFORMED BY

SonoPath Imaging
Center

HOSPITAL NAME

Black River Vet

REFERRING VET

Dr. Hewitt

INVOICE

75104

DATE

5/13/26

PRESENTING CLINICAL SIGNS

Persistent mild ALT elevation. History from 5/6/26- Charlie has a history of ALT elevation of 190 on 2/25/26. Currently receiving Denamarin for liver support. Owner reports her daughter was watching Charlie while owners were away and she noted he appeared more tired than usual during walks. Owner reports occasional coughing today and that he is slower getting up after lying down. He has been gaining weight back (previously 56 pounds). Current Medications: Denamarin

ULTRASONOGRAPHIC EXAMINATION OF THE ABDOMEN

Urinary System

The **urinary bladder**, trigone, and pelvic urethra presented normal thicknesses and normal tone. The ureters were not visible which is normal. No uroliths or sediment were visualized and anechoic urine was present. No evidence of inflammatory or neoplastic changes were noted. Ureteral papillae were normal. The pelvic urethra was imaged 2.0 cm beyond the cystourethral junction.

The residual prostate was uniform measuring 1.33 cm.

The **kidneys** revealed normal size and structure, corticomedullary definition and ratio for this age. The cortices presented largely uniform texture with normal echogenic relationship to liver and spleen. Medullary structure differed distinctly from the cortex and no evidence of pelvic dilation was present. The capsules were acceptably uniform without significant irregularities. Left kidney measured 6.6 cm. Right kidney measured 6.68 cm.

Adrenal Glands

Both **adrenal glands** were visualized and recognized as having normal shape, size, position and echogenicity for this breed. The phrenic vasculature, glandular echogenicity and detail were unremarkable. Capsule, cortex, and medullary definition were normal for this age patient. Left measured 2.37 cm x 0.68 cm at the caudal pole and 0.68 cm at the cranial pole. Right measures 2.5 cm in length x 1.6 cm at the cranial pole and 0.75 cm at the caudal pole.

Spleen

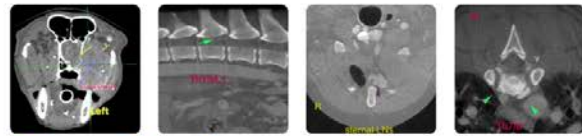
The **spleen** presented a smooth homogeneous parenchyma hyperechoic to liver and renal cortical parenchyma. The capsule was smooth without noticeable expansion or deviation from within the spleen or adjacent pathology. The splenic vasculature demonstrated normal volume without signs of congestion or thrombosis. No sonographic evidence of acute or chronic inflammatory, neoplastic, or infarctual changes were noted.

Liver

The **liver** presented slight coarse architecture and uniform parenchyma. The gallbladder and common bile duct were unremarkable. Slight increased portal markings noted. Given the ALT elevations, this is consistent with very minor low-grade inflammatory hepatopathy.

Gastrointestinal

Examination of the **gastrointestinal tract** revealed a stomach and intestine free of stasis, of normal wall thickness, acceptable curvilinear mural detail, and peristaltic activity. Small and large intestine demonstrated normal luminal chyme and stool consistency respectively. No obstructive or overt infiltrative disease was noted. No associated abnormal lymphatic activity was noted.



PATIENT

Charlie Ellis

SPECIES

Canine

BREED

Standard Poodle

SEX

Neutered Male

AGE

11 Years

WEIGHT

58.6

INTERPRETED BY

Eric Lindquist, DMV,
DABVP (CFM), Cert.
IVUSS

IMAGING PERFORMED BY

SonoPath Imaging
Center

HOSPITAL NAME

Black River Vet

REFERRING VET

Dr. Hewitt

INVOICE

75104

DATE

5/13/26

Pancreas

The base and limbs of the **pancreas** were observed to be largely isoechoic to surrounding omental fat. Pancreatic duct and capsular contour were acceptably normal and parenchyma respected normal curvilinear patterns. No overt evidence of active inflammatory or neoplastic disease was noted.

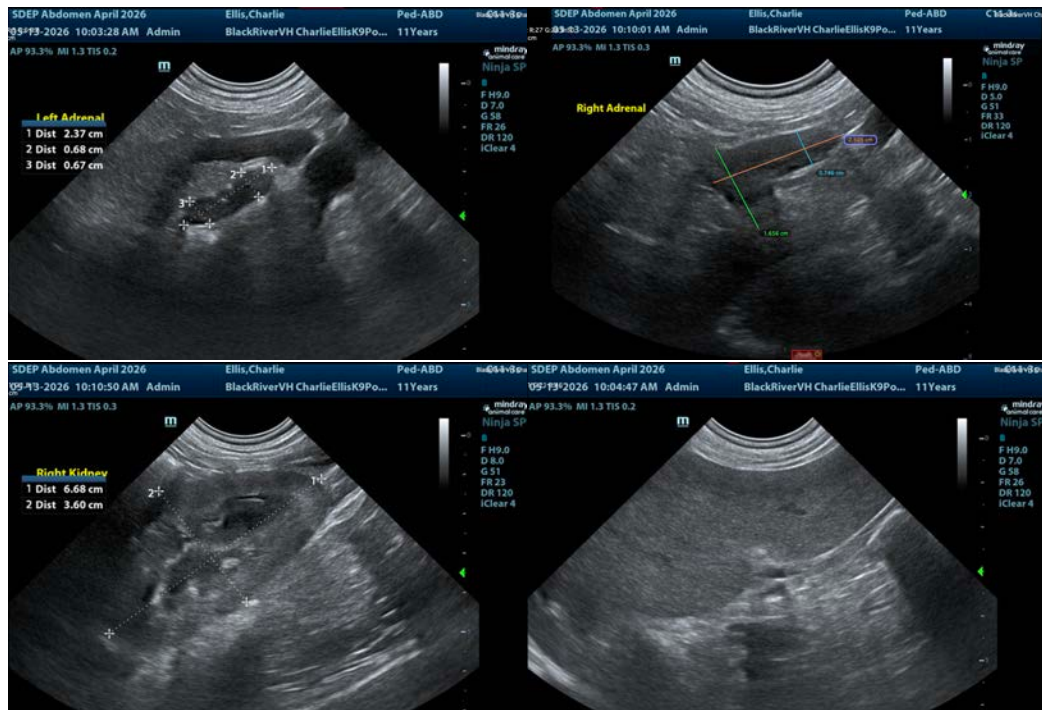
ULTRASONOGRAPHIC FINDINGS

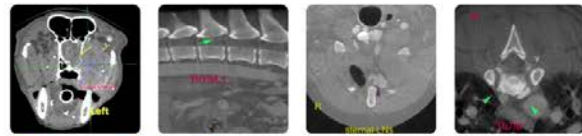
- Structurally unremarkable abdomen with low-grade inflammatory hepatopathy or reactive hepatopathy.

INTERPRETATION OF THE FINDINGS & FURTHER RECOMMENDATIONS

FNA of the liver could be considered for further definition yet subjectively appears benign.

The hepatic clinical sonographic presentation is most consistent with Reactive Hepatopathy which is the most common cause of liver enzyme elevation in dogs and cats. The presumption is that gut and other organ antigen stimuli may be causing a low-grade immune response through portal system with which the liver is reacting to causing low-grade enzyme elevations. US-guided FNA could be performed to assess if low grade lymphoplasmacytic inflammation is present that would support this theory. If FNA is performed, please ask the cytologist to emphasize the primary inflammatory cell type. Empirical treatment measures to address this issue can include diet change to hydrolyzed diet, probiotics, deworming, nutraceuticals (SAME, Actigall...), dental exam and cleaning, and potentially antibiotics such as Clavamox. Metronidazole and Tylosin have traditionally been utilized for this purpose but new studies show that both these antibiotics can disrupt the normal intestinal bacterial flora (intestinal dysbiosis) for weeks and up to 4-6 months. Therefore, Metronidazole and Tylosin should be utilized as a last resort if other efforts have not been effective and sonographic organ appearance remains benign.





PATIENT

Charlie Ellis

SPECIES

Canine

BREED

Standard Poodle

SEX

Neutered Male

AGE

11 Years

WEIGHT

58.6

INTERPRETED BY

Eric Lindquist, DMV,
DABVP (CFM), Cert.
IVUSS

IMAGING PERFORMED BY

SonoPath Imaging
Center

HOSPITAL NAME

Black River Vet

REFERRING VET

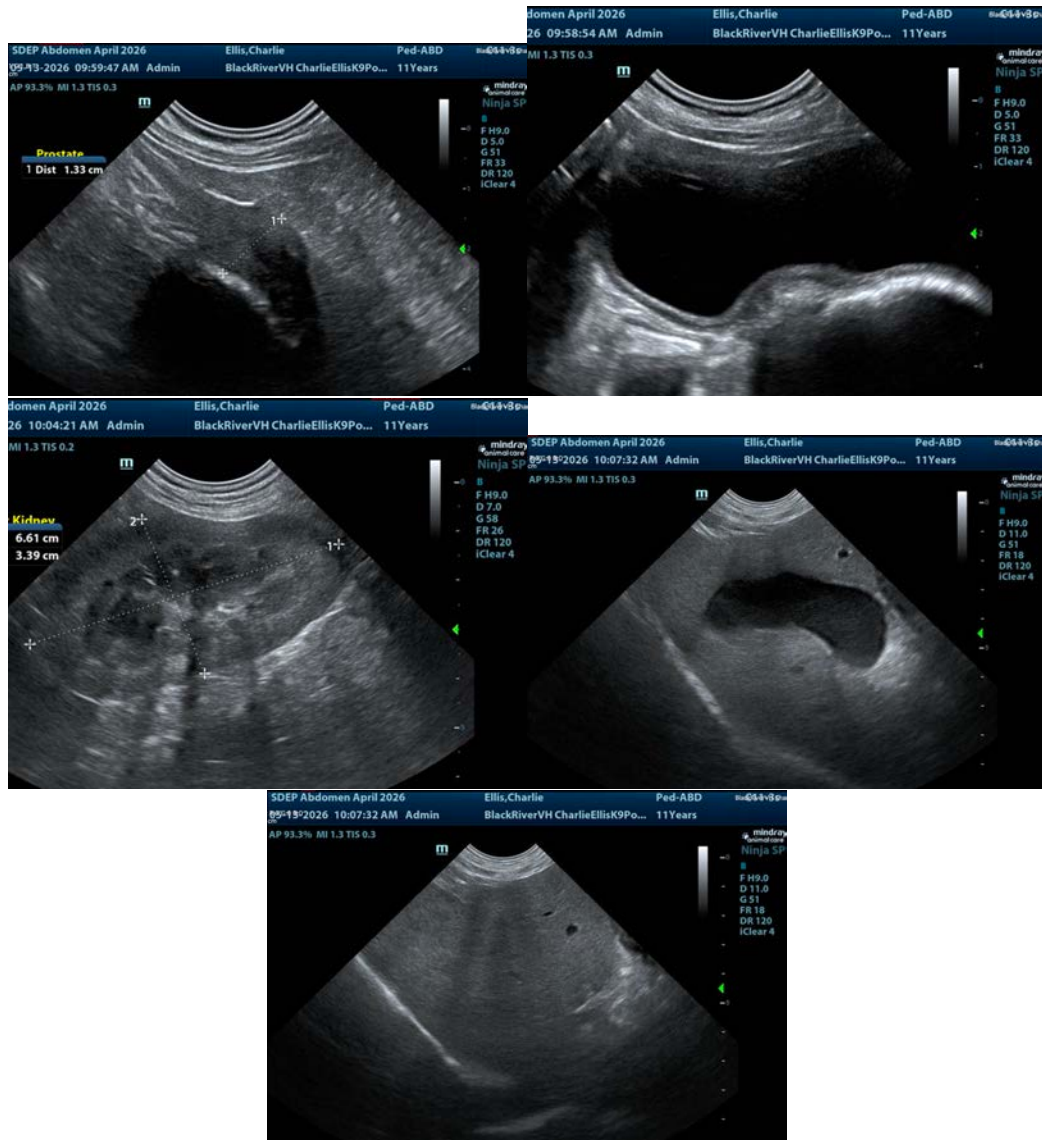Dr. Hewitt

INVOICE

75104

DATE

5/13/26



The information and recommendations provided are based on the images presented by the referring veterinarian/sonographer. No evaluation can be communicated regarding pathology that was not visible in the image/video clips provided.

Thank you for this referral. If the clinical or image interpretation does not parallel your findings or if I can be of any further assistance please contact me.

Eric Lindquist, DMV, DABVP(CFM), Cert. IVUSS,
CEO, Owner, Founder -- SonoPath.com
info@SonoPath.com