



## PATIENT

Banjo Swift

## SPECIES

Canine

## BREED

Mixed

## SEX

Neutered male

## AGE

12 years

## WEIGHT

42 lbs

## INTERPRETED BY

Eric Lindquist, DMV  
DABVP, Cert. IVUSS

## IMAGING PERFORMED BY

Dr. Coe

## HOSPITAL NAME

Riverside Animal Clinic

## REFERRING VET

Dr. Coe

## INVOICE

75476

## DATE

5/13/26

## PRESENTING CLINICAL SIGNS

History: Adopted approximately 10 years prior. Not sure age - owner thinks more likely closer to 15 yrs old. No significant health issues since owned. Recent history of appetite change - wants to eat human foods/fruits/veggies/etc that he had no interest in prior. Still eats normal dog food, as long as topped with a treat. No V/D. Still active, no lameness, but difficulty/hesitates going up stairs/up into car/etc. On Nexgard/Sentinel/Joint supplement. No other meds.  
PE 5/8/26: Nuclear sclerosis OU. Moderate periodontal disease with no halitosis. TNTC soft SQ lumps trunk/forelimbs/shoulders. H/L OK. Abdominal palpation "full" cranially, pot-bellied slightly, non-painful. BCS 5/9, with mild muscle loss capulae/pelvis/hindlimbs. Mini Chem 5/8/26: ALT 288, ALKP 381. No azotemia. GGT/TBili WRI. PCV 47%.

## ULTRASONOGRAPHIC EXAMINATION OF THE ABDOMEN

### Urinary System

The **urinary bladder**, trigone, and pelvic urethra presented normal thicknesses and normal tone. The pelvic urethra was imaged 2.0 cm beyond the cystourethral junction and appeared normal. The ureters were not visible which is normal. No uroliths or sediment were visualized and anechoic urine was present. No evidence of inflammatory or neoplastic changes was noted. Ureteral papillae were normal.

The **kidneys** revealed largely normal size and structure, corticomedullary definition and ratio (cortex 1/3 of medulla) were essentially maintained with some age-related loss of curvilinear patterns regarding the capsule and C/M junction. The cortices presented largely uniform texture with some increased echogenicity expected for this age patient. Medullary structure differed distinctly from that of the cortex. The left kidney measured 5.0 cm. The right kidney measured 5.15 cm with slight pyelectasia. Blood flow of the kidneys appeared to be adequate.

### Adrenal Glands

The left **adrenal gland** was enlarged, heterogenous and measured 0.92 cm at the cranial pole and 0.81 cm at the caudal pole. The left adrenal gland was imaged from the left and right approaches. The right adrenal gland was enlarged and measured 1.2 cm at the cranial pole and 0.74 cm at the caudal pole.

### Spleen

The **spleen** revealed multi-focal, hyperechogenic lipid plaques with mild heterogenous parenchymal changes. This is most consistent with hyperplasia.

### Liver

There was swelling noted at the caudate lobe of the liver. Multi-focal, hypoechoic nodular changes were noted in the midst of hyperechoic parenchymal changes. Gallbladder sand and accumulation of coalesced bile and polypoid changes were noted.



**PATIENT**

Banjo Swift

**SPECIES**

Canine

**BREED**

Mixed

**SEX**

Neutered male

**AGE**

12 years

**WEIGHT**

42 lbs

**INTERPRETED BY**

Eric Lindquist, DMV  
DABVP, Cert. IVUSS

**IMAGING PERFORMED BY**

Dr. Coe

**HOSPITAL NAME**

Riverside Animal Clinic

**REFERRING VET**

Dr. Coe

**INVOICE**

75476

**DATE**

5/13/26

**Gastrointestinal**

There was some residual chyme and gas was noted in the **stomach**, yet not pathological. This is consistent with post prandial presentation. Transit of chyme into the small intestine was normal. Curvilinear patterns were maintained throughout the GI tract. No evidence of pathology. Small and large intestine demonstrated normal luminal chyme and stool consistency respectively. No obstructive or overt infiltrative disease was noted. No associated abnormal lymphatic activity was noted.

**Pancreas**

The base and limbs of the **pancreas** were observed to be largely isoechoic to surrounding omental fat. Pancreatic duct and capsular contour were acceptably normal and parenchyma respected normal curvilinear patterns. No overt evidence of active inflammatory or neoplastic disease was noted.

**ULTRASONOGRAPHIC FINDINGS**

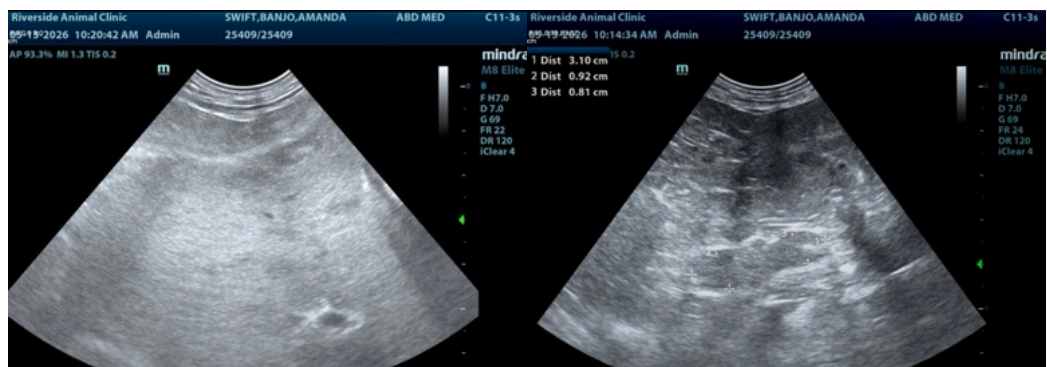Age related abdominal changes with minor renal pyelectasia. Minor nephrolithiasis  
Prominent adrenal glands.

Hepatic swelling at the caudate lobe with nodular hyperplasia liver pattern.

Gallbladder sand without mucocele formation.

**INTERPRETATION OF THE FINDINGS & FURTHER RECOMMENDATIONS**

Bile acid profile is indicated. Ursodiol and liver support is recommended. The caudate swelling is likely related to metabolic hepatopathy/vacuolar hepatopathy with potential for adenoma. Carcinoma is unlikely. FNA is recommended for further definition. Recheck sonogram in 8 weeks to assess any changes.





**PATIENT**

Banjo Swift

**SPECIES**

Canine

**BREED**

Mixed

**SEX**

Neutered male

**AGE**

12 years

**WEIGHT**

42 lbs

**INTERPRETED BY**

Eric Lindquist, DMV  
DABVP, Cert. IVUSS

**IMAGING  
PERFORMED BY**

Dr. Coe

**HOSPITAL NAME**

Riverside Animal Clinic

**REFERRING VET**

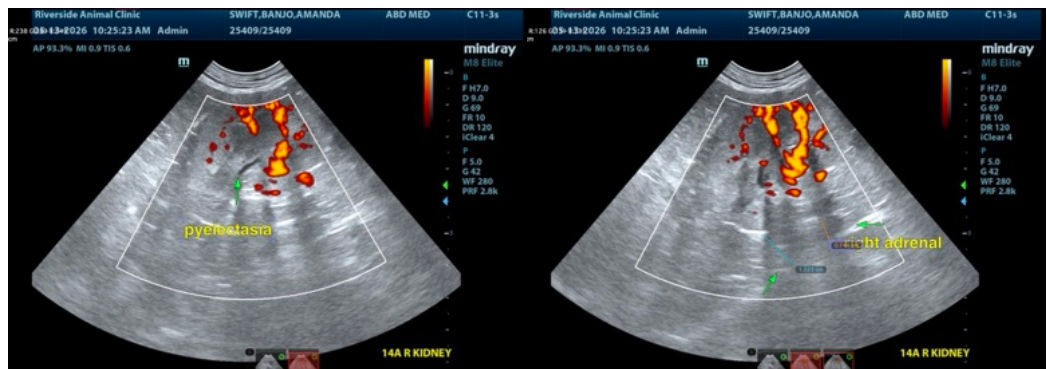
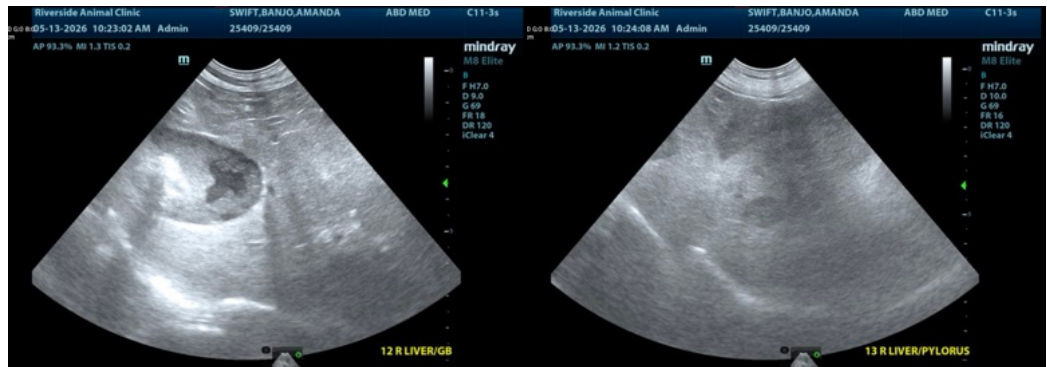
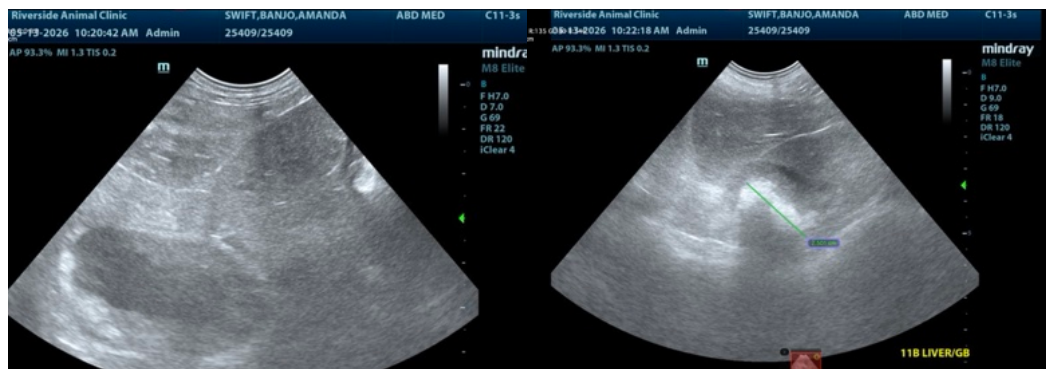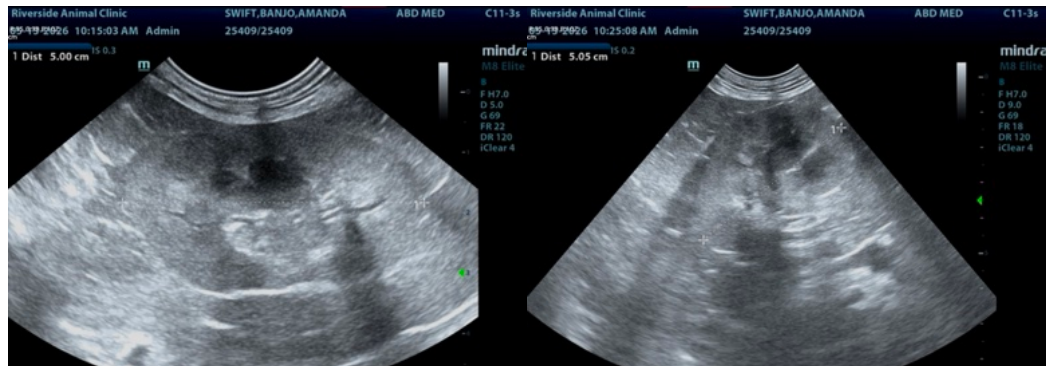
Dr. Coe

**INVOICE**

75476

**DATE**

5/13/26





## PATIENT

Banjo Swift

## SPECIES

Canine

## BREED

Mixed

## SEX

Neutered male

## AGE

12 years

## WEIGHT

42 lbs

## INTERPRETED BY

Eric Lindquist, DMV  
DABVP, Cert. IVUSS

## IMAGING PERFORMED BY

Dr. Coe

## HOSPITAL NAME

Riverside Animal Clinic

## REFERRING VET

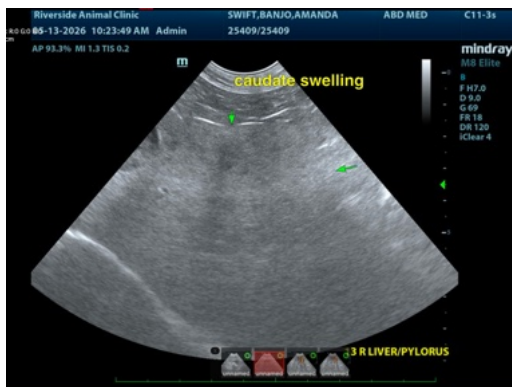Dr. Coe

## INVOICE

75476

## DATE

5/13/26



The information and recommendations provided are based on the images presented by the referring veterinarian/sonographer. No evaluation can be communicated regarding pathology that was not visible in the image/video clips provided.

Thank you for this referral. If the clinical or image interpretation does not parallel your findings or if I can be of any further assistance please contact me.

Eric Lindquist, DMV, DABVP (CFM), Cert. IVUSS, CEO of SonoPath.com

[info@SonoPath.com](mailto:info@SonoPath.com)