**DATE**

5/13/22

**PRESENTING CLINICAL SIGNS**

History: Owner got pet when he was 4 months old and was told was intact, has not had any testicles drop since got him in July 2021.

**PATIENT**

Sam Ballard

Date of Previous IntraPet Ultrasound: No previous.

Sedation: Not required to complete full diagnostic ultrasound.

Stat Report: Not requested.

Imaging Performed By: Rachel Brillhart, RDMS.

**SPECIES**

Canine

**LIMITED ULTRASONOGRAPHIC EXAMINATION****BREED**

Boxer

The **kidneys** revealed normal size and structure, corticomedullary definition and ratio for this age. The cortices presented largely uniform texture with normal echogenic relationship to liver and spleen. Medullary structure differed distinctly from the cortex and no evidence of pelvic dilation was present. The capsules were acceptably uniform without significant irregularities. The left kidney measured 6.86 cm. The right kidney measured 5.41 cm.

**SEX**

Intact Male

The **prostate** was uniform, measuring 2.0 cm. No evident pathology.

**AGE**

3/2/21

The left **testicle** was cranial to the urinary bladder and adjacent to the body wall, measuring 2.5 cm. The right testicle measured 2.0 cm. The right testicle was just cranial to the urinary bladder, adjacent to the body wall.

**WEIGHT**

70 Pounds

**ULTRASONOGRAPHIC FINDINGS**

- Bilateral intraabdominal cryptorchids, cranial lateral to the urinary bladder apex, adjacent to the body wall

**INTERPRETED BY**

Eric Lindquist, DMV  
DABVP, Cert. IVUSS

**INTERPRETATION OF THE FINDINGS & FURTHER RECOMMENDATIONS**

The testicles should be easily found upon laparotomy.

**HOSPITAL NAME**

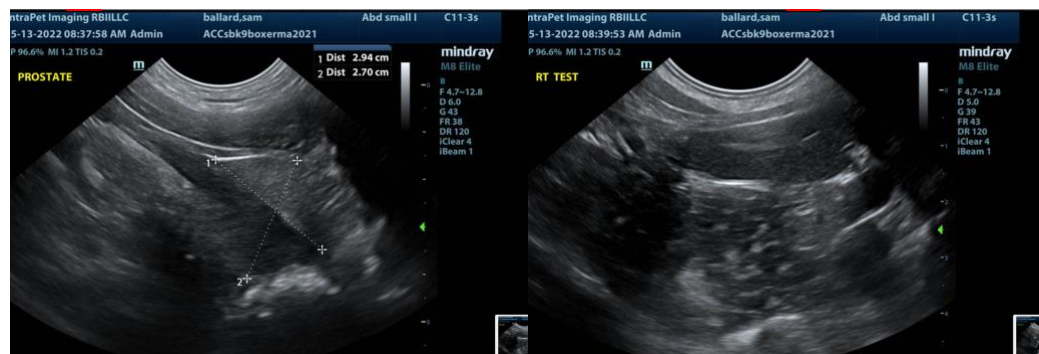
Animal Care Center

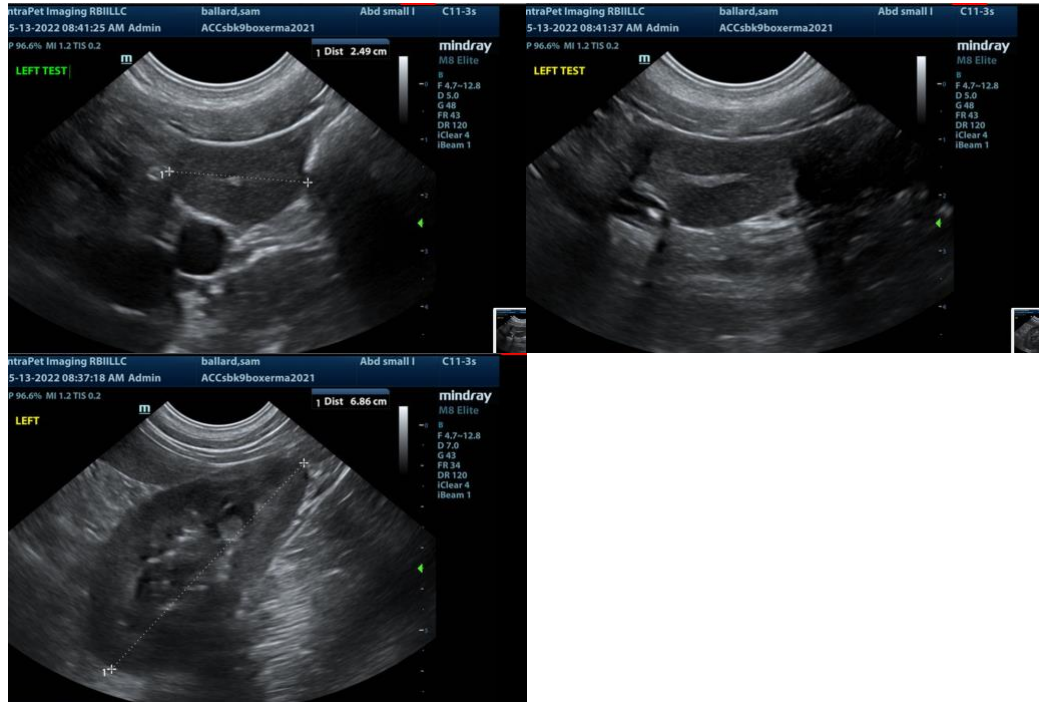
**REFERRING VET**

Dr. Muedeking

**INVOICE**

15180





**The information and recommendations provided are based on the images presented by the referring veterinarian. No evaluation can be communicated regarding pathology that was not visible in the image/video clips provided.**

Thank you for this referral. If the clinical or image interpretation does not parallel your findings or if I can be of any further assistance please contact me.

**Eric Lindquist**, DMV, DABVP, Cert. IVUSS, CEO of SonoPath.com  
Eric.Lindquist@SonoPath.com