

## PATIENT PRESENTING CLINICAL SIGNS

Reiku Rauch History: Owner just noticed mass ventral neck on 5/6/22

## SPECIES LIMITED ULTRASONOGRAPHIC EXAMINATION

Canine The left thyroid lobe was uniform, measuring 2.6 cm x 0.6 cm. The right thyroid lobe was uniform, measuring 3.0 cm x 0.5 cm. No evidence of pathology.

BREED The esophagus, trachea, carotid and regional tissues were all normal.

Mix The parathyroids were imaged on both thyroid lobes and measured from 0.15 cm – 0.3 cm.

## SEX

Neutered Male

The right cranial subcutaneous tissue revealed regional mixed hyperechoic cellulitis pattern with regional lymphadenopathy. Retropharyngeal lymph nodes were slightly enlarged. Length to width ratio was maintained. The largest lymph node measured 8.0 mm. The mass appears to have a granulation bed and a focal hyperechoic structure. It is adjacent to the trachea but separated from it. Foreign body, granuloma or abscess likely. Exploratory surgery or CT evaluation indicated. The suspected linear foreign body noted in the middle of the granuloma is surrounded by cellulitis with reactive lymph nodes. The structure appears to be approximately 1.5 cm in length at a depth of approximately 1.7 cm from the skin. The granulomatous structure initiates approximately 1.0 cm from the skin and continues to approximately 2.5 cm of depth.

## AGE

3 Years

## WEIGHT

78.9 Pounds

## ULTRASONOGRAPHIC FINDINGS

- Granulomatous type structure with suspicion of linear foreign body
- Reactive lymphadenopathy and regional cellulitis

## INTERPRETED BY

Eric Lindquist, DMV  
DABVP, Cert. IVUSS

## INTERPRETATION OF THE FINDINGS & FURTHER RECOMMENDATIONS

Minimal suspicion for neoplasia. It appears to be separate from the trachea and related structures. Exploratory surgery or CT evaluation indicated.

## IMAGING PERFORMED BY

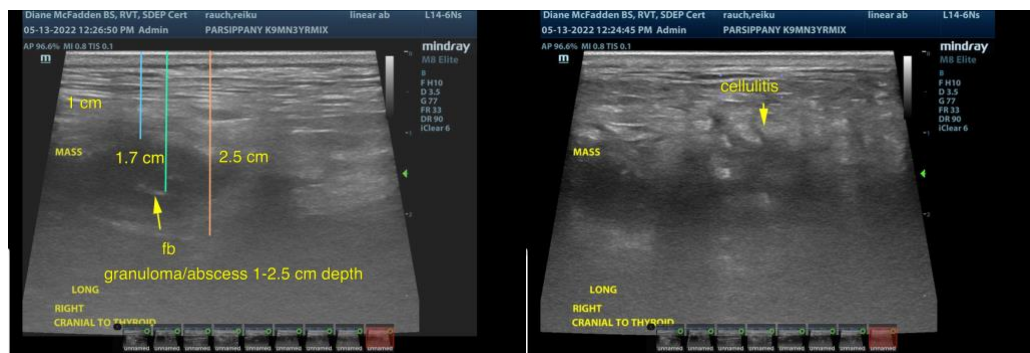Diane McFadden

## HOSPITAL NAME

Parsippany Troy Hills  
AH

## REFERRING VET

Dr. Dulude



## INVOICE

15205

## DATE

5/13/22



**PATIENT**

Reiku Rauch

**SPECIES**

Canine

**BREED**

Mix

**SEX**

Neutered Male

**AGE**

3 Years

**WEIGHT**

78.9 Pounds

**INTERPRETED BY**

Eric Lindquist, DMV  
DABVP, Cert. IVUSS

**IMAGING PERFORMED BY**

Diane McFadden

**HOSPITAL NAME**

Parsippany Troy Hills  
AH

**REFERRING VET**

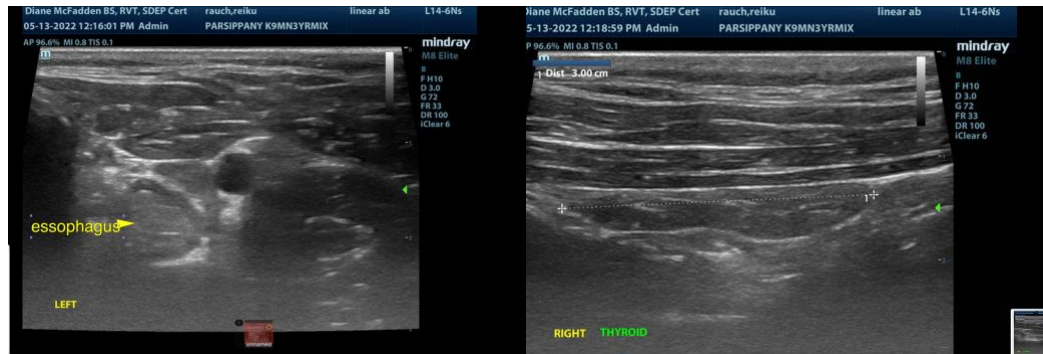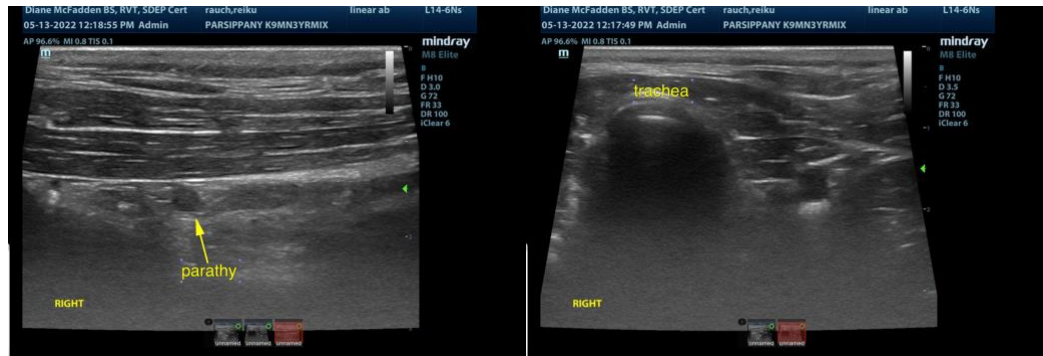
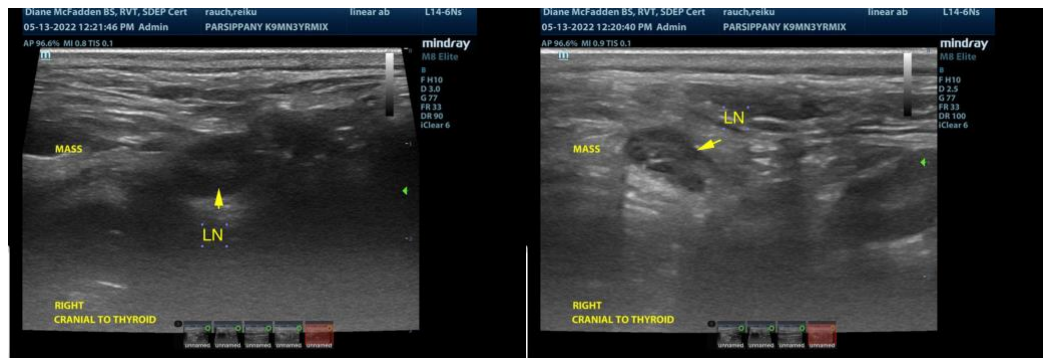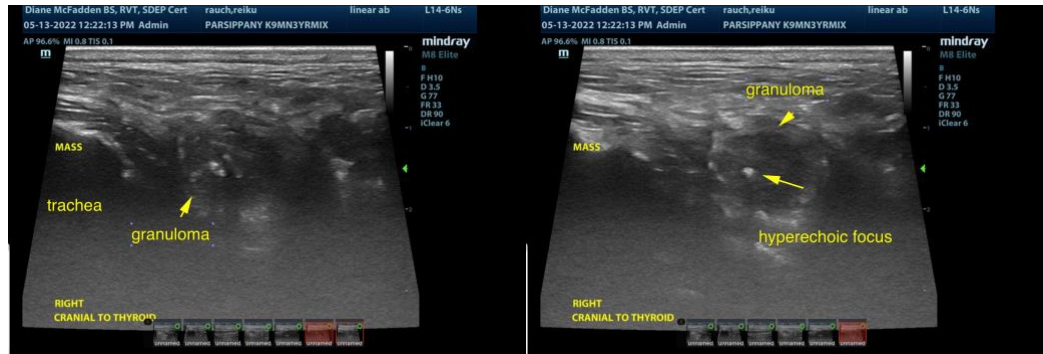Dr. Dulude

**INVOICE**

15205

**DATE**

5/13/22





**PATIENT**

Reiku Rauch

**SPECIES**

Canine

**BREED**

Mix

**SEX**

Neutered Male

**AGE**

3 Years

**WEIGHT**

78.9 Pounds

**INTERPRETED BY**

Eric Lindquist, DMV  
DABVP, Cert. IVUSS

**IMAGING PERFORMED BY**

Diane McFadden

**HOSPITAL NAME**

Parsippany Troy Hills  
AH

**REFERRING VET**

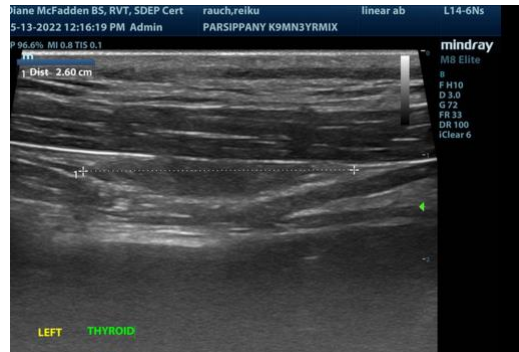Dr. Dulude

**INVOICE**

15205

**DATE**

5/13/22



The information and recommendations provided are based on the images presented by the referring veterinarian. No evaluation can be communicated regarding pathology that was not visible in the image/video clips provided.

Thank you for this referral. If the clinical or image interpretation does not parallel your findings or if I can be of any further assistance please contact me.

**Eric Lindquist**, DMV, DABVP, Cert. IVUSS, CEO of SonoPath.com  
info@SonoPath.com