



PATIENT PRESENTING CLINICAL SIGNS

Oreo Watt History: patient urinating blood hematuria

SPECIES ULTRASONOGRAPHIC EXAMINATION OF THE ABDOMEN

Feline **Urinary System**

BREED

Domestic Medium Hair

The **urinary bladder** comprised of a concentric mass. That measured 4.0 cm and occupied the entire bladder except for a portion of the cystourethral junction. This is strongly consistent with transitional cell carcinoma. There was a minor potential for bladder lymphoma. The urethra was mildly thickened as well. Some of the luminal material in the bladder may be a blood clot, however, the majority appears to be proliferative tissue. There was thickening at the cystourethral junction up to 0.7 cm. This is suggestive for mass invasion into the cystourethral junction and urethra.

SEX

Neutered male

ULTRASONOGRAPHIC FINDINGS

AGE

17 years

Concentric and multi-focal bladder mass involving the body of the bladder and cystourethral junction and proximal urethra.

WEIGHT

12 lbs

INTERPRETATION OF THE FINDINGS & FURTHER RECOMMENDATIONS

INTERPRETED BY

Eric Lindquist, DMV
DABVP, Cert. IVUSS

This is strongly consistent with transitional cell carcinoma. FNA can be considered; however, high risk of trailing is possible. Given that this is a male traumatic catheterization with ultrasound guidance would be ideal for cytology to differentiated bladder lymphoma from transitional cell carcinoma. If bladder is the underlying diagnosis then chemotherapy may prove effective. Otherwise, urethral stent placement could be considered. The ureters were not obstructive at this time as the ureteral papilla is one of the few portions of the bladder that does not appear to be involved with the neoplastic process.

IMAGING PERFORMED BY

Dr. Smatt

HOSPITAL NAME

The Pets I Love

REFERRING VET

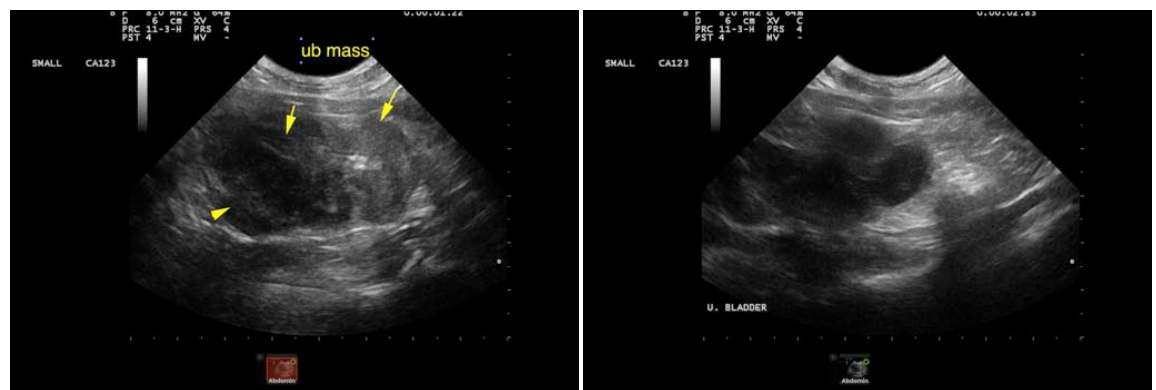
Dr. Smatt

INVOICE

30399

DATE

5/13/22





PATIENT

Oreo Watt

SPECIES

Feline

BREED

Domestic Medium Hair

SEX

Neutered male

AGE

17 years

WEIGHT

12 lbs

INTERPRETED BY

Eric Lindquist, DMV
DABVP, Cert. IVUSS

IMAGING PERFORMED BY

Dr. Smatt

HOSPITAL NAME

The Pets I Love

REFERRING VET

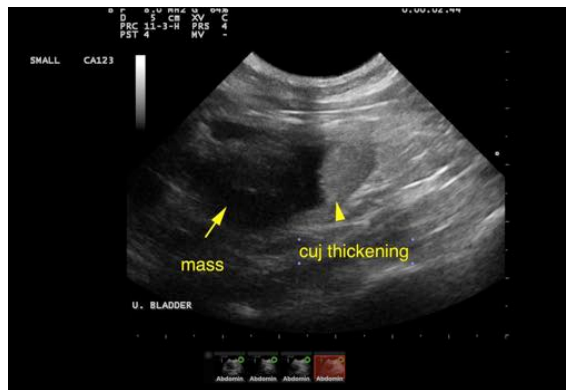
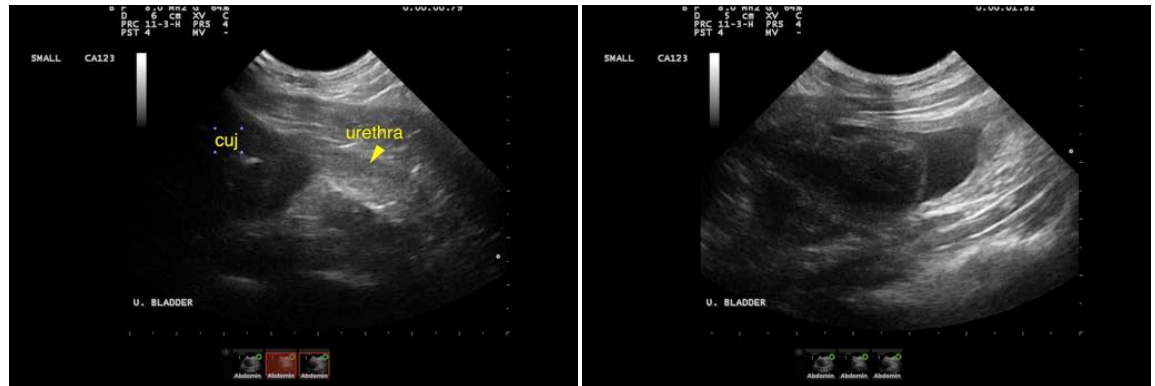
Dr. Smatt

INVOICE

30399

DATE

5/13/22



The information and recommendations provided are based on the images presented by the referring veterinarian/sonographer. No evaluation can be communicated regarding pathology that was not visible in the image/video clips provided.

Thank you for this referral. If the clinical or image interpretation does not parallel your findings or if I can be of any further assistance please contact me.

Eric Lindquist, DMV, DABVP, Cert. IVUSS, CEO of SonoPath.com
info@SonoPath.com