



PATIENT

Norah Ferrante

SPECIES

Feline

BREED

Domestic Shorthair

SEX

Spayed Female

AGE

16 months

WEIGHT

7.8 lbs

INTERPRETED BY

Eric Lindquist, DMV
DABVP, Cert. IVUSS

IMAGING PERFORMED BY

Dr. Abdul Chani

HOSPITAL NAME

Byram AH

REFERRING VET

Dr. Cruz

INVOICE

30337

DATE

5/12/22

PRESENTING CLINICAL SIGNS

History: R/O Intestinal obstruction ; 1 week history of decreased appetite; on/off vomiting and diarrhea Current meds: Metronidazole/ Cerenia / Convenia injection
Abnormal PE/Chem/CBC/UA Results: CBC: EOS = 3520/22% ; SuperChem: all WNL / T4 = normal / SDMA = normal Urinalysis : Not done Urine S.G. = not done

ULTRASONOGRAPHIC EXAMINATION OF THE ABDOMEN

Urinary System

The **urinary bladder**, trigone, and pelvic urethra presented normal thicknesses and normal tone. The ureters were not visible which is normal. No uroliths or sediment were visualized and anechoic urine was present. No evidence of inflammatory or neoplastic changes was noted. Ureteral papillae were normal.

The **kidneys** revealed normal size and structure, corticomedullary definition and ratio for this age. The cortices presented largely uniform texture with normal echogenic relationship to liver and spleen. Medullary structure differed distinctly from the cortex and no evidence of pelvic dilation was present. The capsules were acceptably uniform without significant irregularities. The left kidney measured 4.14 cm. The right kidney measured 3.77 cm.

Adrenal Glands

Both **adrenal glands** were visualized and recognized as having normal shape, size, position and echogenicity for this breed. The phrenic vasculature, glandular echogenicity and detail were unremarkable. Capsule, cortex, and medullary definition were normal for this age patient. The left adrenal gland measured 0.4 cm. The right adrenal gland measured 0.5 cm.

Spleen

The **spleen** presented a smooth homogeneous parenchyma hyperechoic to liver and renal cortical parenchyma. The capsule was smooth without noticeable expansion or deviation from within the spleen or adjacent pathology. The splenic vasculature demonstrated normal volume without signs of congestion or thrombosis. No sonographic evidence of acute or chronic inflammatory, neoplastic, or infarctual changes was noted.

Liver

The **liver** images submitted revealed subjectively normal liver size, contour, and structure. Parenchymal echogenicity was naturally coarse and hypoechoic to the spleen. Vascular and biliary tracts were of normal volume with no evidence of congestion. The gallbladder presented acceptably thin walls with primarily anechoic content. The cystic and common bile ducts were normal. No pathological hepatic lymphadenopathy was evident. No overt structural evidence of inflammatory, infiltrative or regenerative pathology was evident.



PATIENT

Gastrointestinal

Norah Ferrante

The **gastrointestinal** presentation revealed mild uniform prominence of the gastric mucosa as well as areas of "ropey" small intestinal wall. The muscularis layer was hypertrophied inverting the normal ratio (1:3). The intestinal submucosa was slightly irregular, thickened and hyperechoic suggestive of low grade, chronic inflammation. No evidence of obstruction was present. Chronic inflammatory bowel disease is probable with a low possibility of an early neoplastic event such as lymphoma or, less likely, dry form FIP can at times be found on biopsy of these presentations. Full thickness tissue biopsies via open laparotomy, ideally guided by intraoperative ultrasound in order to obtain the most representative mural sample, would be necessary to rule more significant disease than IBD.

SPECIES

Feline

BREED

Domestic Shorthair

SEX

Spayed Female

Pancreas

The base and limbs of the **pancreas** were observed to be largely isoechoic to surrounding omental fat. Pancreatic duct and capsular contour were acceptably normal and parenchyma respected normal curvilinear patterns. No overt evidence of active inflammatory or neoplastic disease was noted.

AGE

16 months

ULTRASONOGRAPHIC FINDINGS

Diffuse intestinal thickening with hypertrophied muscularis.

WEIGHT

7.8 lbs

INTERPRETATION OF THE FINDINGS & FURTHER RECOMMENDATIONS

Full thickness intestinal biopsies are necessary for a definitive diagnosis. No overt neoplastic criteria was present. There is no evidence of intestinal obstruction. Supportive care should prove effective.

INTERPRETED BY

Eric Lindquist, DMV
DABVP, Cert. IVUSS

IMAGING PERFORMED BY

Dr. Abdul Chani

HOSPITAL NAME

Byram AH

REFERRING VET

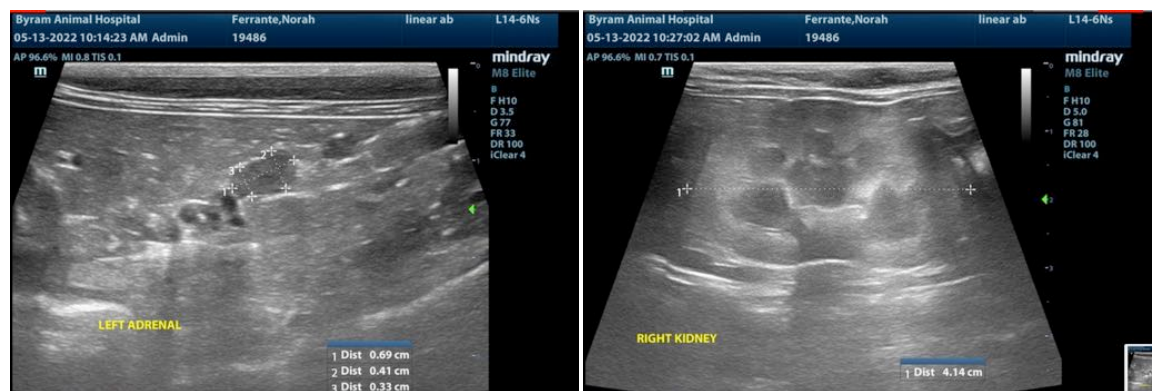
Dr. Cruz

INVOICE

30337

DATE

5/12/22





PATIENT

Norah Ferrante

SPECIES

Feline

BREED

Domestic Shorthair

SEX

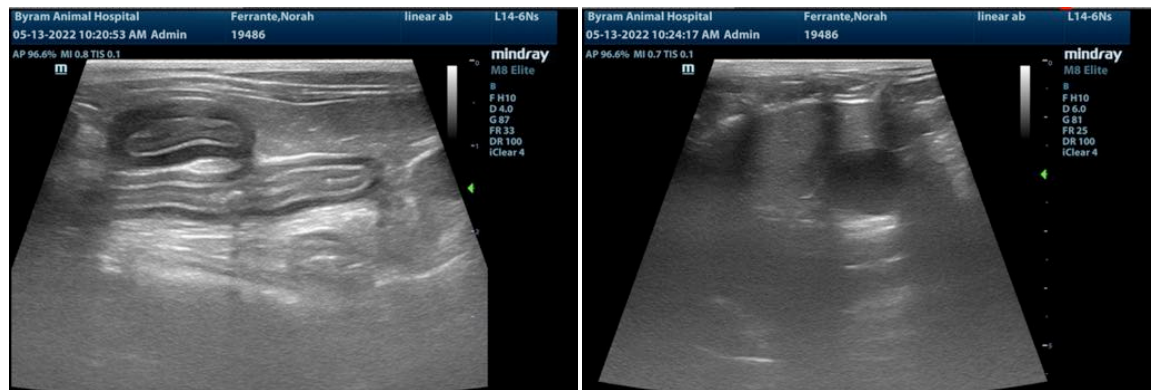
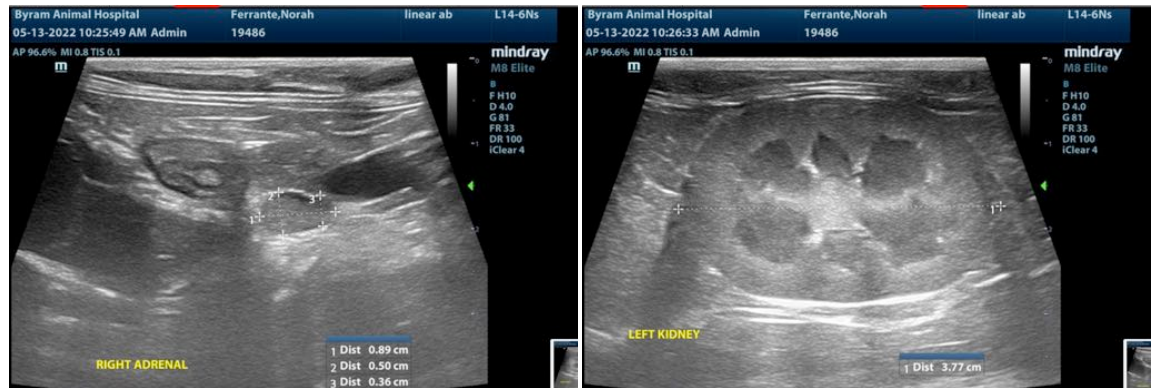
Spayed Female

AGE

16 months

WEIGHT

7.8 lbs



INTERPRETED BY

Eric Lindquist, DMV
DABVP, Cert. IVUSS

IMAGING PERFORMED BY

Dr. Abdul Chani

HOSPITAL NAME

Byram AH

REFERRING VET

Dr. Cruz

INVOICE

30337

DATE

5/12/22

The information and recommendations provided are based on the images presented by the referring veterinarian/sonographer. No evaluation can be communicated regarding pathology that was not visible in the image/video clips provided.

Thank you for this referral. If the clinical or image interpretation does not parallel your findings or if I can be of any further assistance please contact me.

Eric Lindquist, DMV, DABVP, Cert. IVUSS, CEO of SonoPath.com
info@SonoPath.com