



PATIENT

Nixxie Yannette

SPECIES

Feline

BREED

Domestic Shorthair

SEX

Spayed Female

AGE

10 years

WEIGHT

7 lbs

INTERPRETED BY

Eric Lindquist, DMV,
DABVP, Cert. IVUSS,
CEO of SonoPath.com

IMAGING PERFORMED BY

Kelly Vazquez, CVT

HOSPITAL NAME

Allendale VH

REFERRING VET

Dr. Raum

INVOICE

30374

DATE

5/13/22

PRESENTING CLINICAL SIGNS

History: Vomiting/hemorrhagic diarrhea, weight loss, inappetance, lethargy, muscle fasciculations (generalized). BP 121/91 MAP 106. Current meds: Metronidazole, Cerenia, Convenia, IV LRS, Buprenex, Midazolam.

Abnormal PE/Chem/CBC/UA Results: FELV/FIV: (neg), neuts. 16.3, PLTs 1244, glucose 164, BUN 56, ALP <10, lipase 1543, Na 138, cl. 96, K+ 3.

ULTRASONOGRAPHIC EXAMINATION OF THE ABDOMEN

Urinary System

The **urinary bladder**, trigone, and pelvic urethra presented normal thicknesses and normal tone. The ureters were not visible which is normal. No uroliths or sediment were visualized and anechoic urine was present. No evidence of inflammatory or neoplastic changes was noted. Ureteral papillae were normal.

The **kidneys** revealed largely normal size and structure, corticomedullary definition and ratio (cortex 1/3 of medulla) were essentially maintained with some age-related loss of curvilinear patterns regarding the capsule and C/M junction. The cortices presented largely uniform texture with some increased echogenicity expected for this age patient. Medullary structure differed distinctly from that of the cortex and no evidence of pelvic dilation was present. The right kidney measured 3.36 cm. The left kidney measured 3.33 cm with slight, hyperechoic medullary rim sign.

Adrenal Glands

Both **adrenal glands** were visualized and recognized as having normal shape, size, position and echogenicity for this breed. The phrenic vasculature, glandular echogenicity and detail were unremarkable. Capsule, cortex, and medullary definition were normal for this age patient. The left adrenal gland measured 0.59 cm.

Spleen

The **spleen** revealed slight irregular swelling at the cranial pole. This is likely a normal variant. The spleen measured 0.8 cm.

Liver

The **liver** images submitted revealed subjectively normal liver size, contour, and structure. Parenchymal echogenicity was naturally coarse and hypoechoic to the spleen. Vascular and biliary tracts were of normal volume with no evidence of congestion. The gallbladder was mildly over distended. This is likely owing to anorexic state.

Gastrointestinal

Minor **gastric** fluid was also noted. The small intestines and colon were unremarkable.



PATIENT

Nixxie Yannette

Pancreas

SPECIES

Feline

One section of the right limb of the **pancreas** was slightly heterogenous and hypoechoic with minor duct dilation. This is most consistent with focal pancreatitis especially if subxiphoid palpation demonstrates discomfort in the right cranial abdomen.

BREED

Domestic Shorthair

ULTRASONOGRAPHIC FINDINGS

Structurally unremarkable abdomen.
Mild to moderate degenerative renal changes.

SEX

Spayed Female

GI insult and minor right limb pancreatitis.

AGE

10 years

INTERPRETATION OF THE FINDINGS & FURTHER RECOMMENDATIONS

Supportive care should prove effective. Given the patient's history CT with contrast of the CNS is indicated.

WEIGHT

7 lbs

ABOUT SONOPATH CT SERVICES:

SonoPath CT Services are offered at the [Blairstown Animal Hospital](#). Blairstown, New Jersey. More information can be found at

<https://sonopath.com/resources/sonopaths-teleconsultation-services-and-sdep-certification/sonopath-ct-services>

INTERPRETED BY

Eric Lindquist, DMV,
DABVP, Cert. IVUSS,
CEO of SonoPath.com

IMAGING PERFORMED BY

Kelly Vazquez, CVT

HOSPITAL NAME

Allendale VH

REFERRING VET

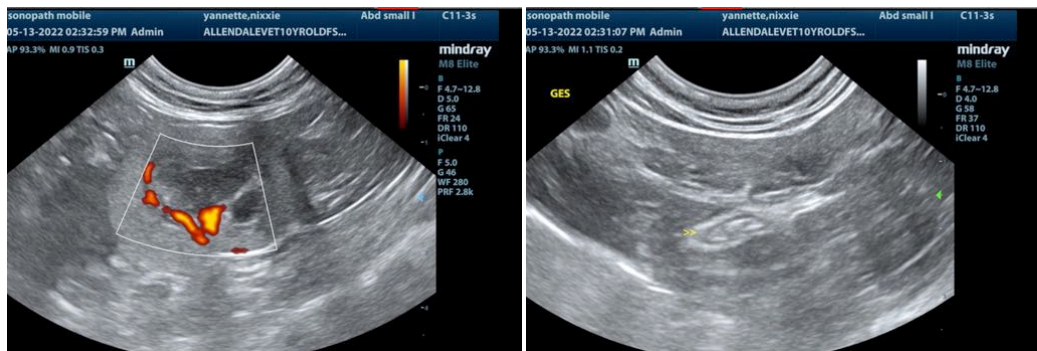
Dr. Raum

INVOICE

30374

DATE

5/13/22





PATIENT

Nixxie Yannette

SPECIES

Feline

BREED

Domestic Shorthair

SEX

Spayed Female

AGE

10 years

WEIGHT

7 lbs

INTERPRETED BY

Eric Lindquist, DMV,
DABVP, Cert. IVUSS,
CEO of SonoPath.com

IMAGING PERFORMED BY

Kelly Vazquez, CVT

HOSPITAL NAME

Allendale VH

REFERRING VET

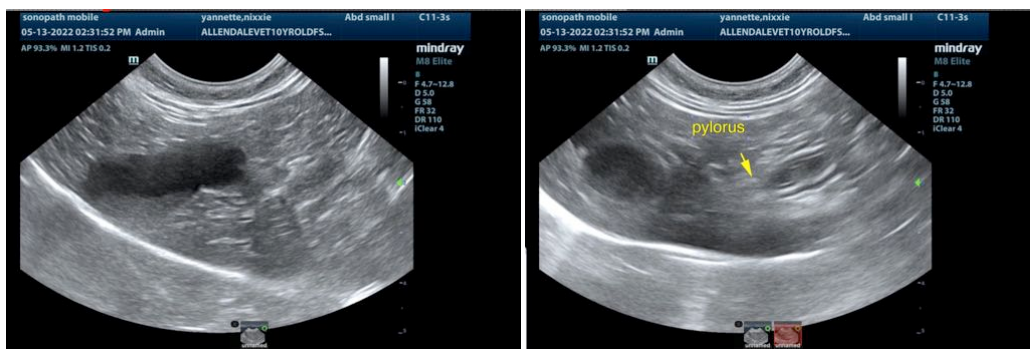
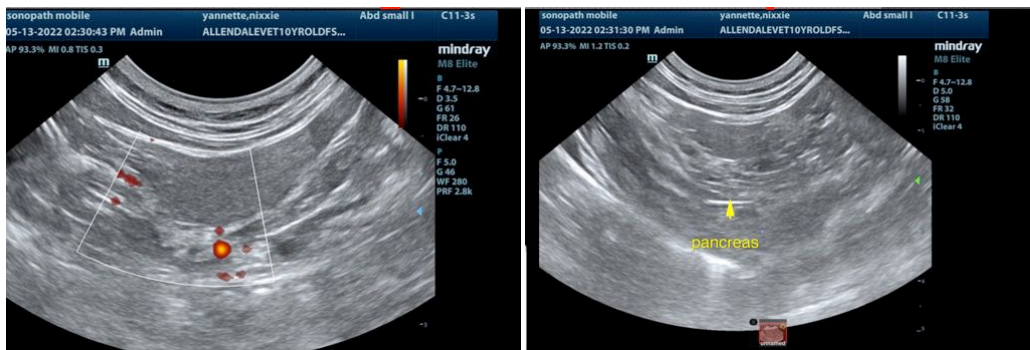
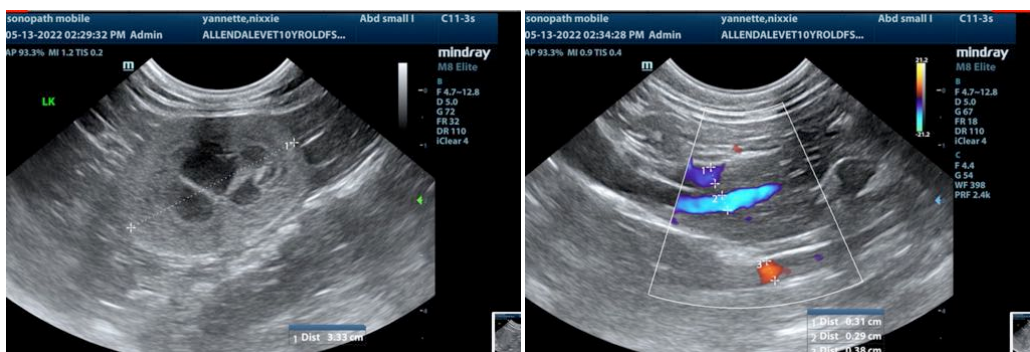
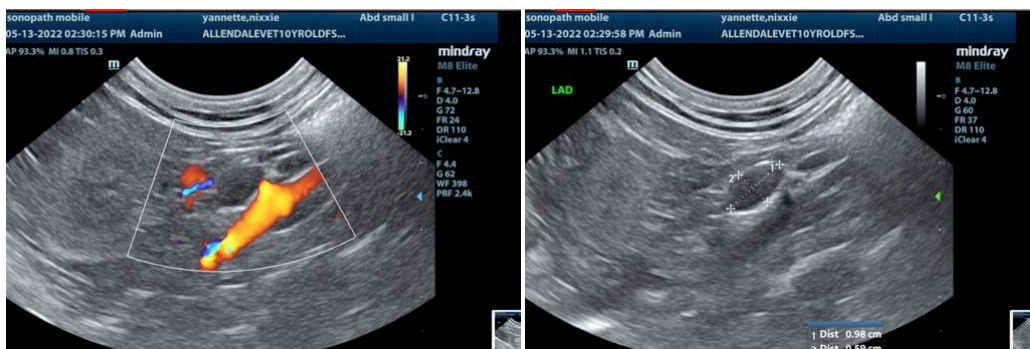
Dr. Raum

INVOICE

30374

DATE

5/13/22





PATIENT

Nixxie Yannette

SPECIES

Feline

BREED

Domestic Shorthair

SEX

Spayed Female

AGE

10 years

WEIGHT

7 lbs

INTERPRETED BY

Eric Lindquist, DMV,
DABVP, Cert. IVUSS,
CEO of SonoPath.com

**IMAGING
PERFORMED BY**

Kelly Vazquez, CVT

HOSPITAL NAME

Allendale VH

REFERRING VET

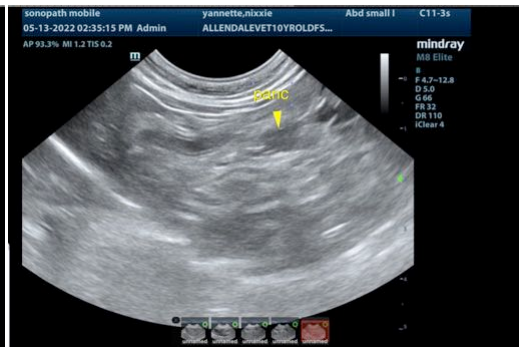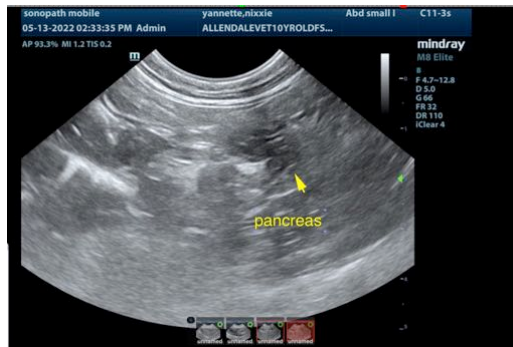Dr. Raum

INVOICE

30374

DATE

5/13/22



The information and recommendations provided are based on the images presented by the referring veterinarian/sonographer. No evaluation can be communicated regarding pathology that was not visible in the image/video clips provided.

Thank you for this referral. If the clinical or image interpretation does not parallel your findings or if I can be of any further assistance please contact me.

Eric Lindquist, DMV, DABVP, Cert. IVUSS, CEO of SonoPath.com

Info@SonoPath.com