


PATIENT PRESENTING CLINICAL SIGNS

Nate Sullivan History: recheck echo from 1/8/22

SPECIES ULTRASONOGRAPHIC EXAMINATION OF THE ABDOMEN

Feline

The echocardiogram in this patient presented persistent concentric hypertrophy of the left ventricle with mitral insufficiency and left atrial enlargement. Smoke was noted in the left atrium. Tricuspid insufficiency was noted at 2.0 m/sec. The right heart was unremarkable. Minor pericardial and pleural effusion was noted. This is consistent with decompensation of the prior presentation. Periodic arrhythmia was noted.

BREED

Domestic Shorthair

SEX

Neutered male

AGE

11 years

WEIGHT

10.7 lbs

INTERPRETED BY

 Eric Lindquist, DMV
 DABVP, Cert. IVUSS

IMAGING PERFORMED BY

Diane McFadden, RVT

HOSPITAL NAME

Sova AH

REFERRING VET

Dr. Sova

INVOICE

30380

DATE

5/13/22

ULTRASONOGRAPHIC FINDINGS

Persistent concentric hypertrophy of the left ventricle.

Mitral insufficiency and left atrial enlargement.

INTERPRETATION OF THE FINDINGS & FURTHER RECOMMENDATIONS

I recommend Pimobendan off label at 0.3 mg/kg b.i.d. and daily Lasix therapy as well as ace inhibitor at 0.5 mg/kg s.i.d. and Plavix therapy. However, this may be adjusted if some medications are currently being utilized. The prognosis is very guarded. Recheck echocardiogram is recommended in 10-14 days with baseline respiratory rate target less than 20/minute. This patient is at risk for sudden death.

FELINE CARDIAC PARAMETERS	BODY WEIGHT	HR (BPM)	IVSd (cm)	LVIDd (cm)	LVWd (cm)	FS (%)	EF (%)
NORMAL PARAMETER	-----	150-240	0.3-0.6	1.0-2.1	0.25-0.6	35-67	80-100
PATIENT	10.7 lbs	178	0.8	1.0	0.8	50	86
FELINE CARDIAC PARAMETERS	LA/AO (Boon)	LA/AO HEART BASE (Sisson)	LA 2D 4-chamber long axis AS to FW (Sisson) (cm)	LVOT VEL. (m/s)	RVOT VEL. (m/s)	IVRT (m/)	
NORMAL PARAMETER	<1.5	0.88-1.79	0.7-1.7	<1.6	<1.3	40-60	
PATIENT		1.95	2.0	2.0	0.9	NM	

Adapted from June Boon, Veterinary Echocardiography, 1998
 Sisson D et al. JVIM 1991; 5: 232, Jacobs et al. Am J Vet Res 1985; 46:1705



PATIENT

Nate Sullivan

SPECIES

Feline

BREED

Domestic Shorthair

SEX

Neutered male

AGE

11 years

WEIGHT

10.7 lbs

INTERPRETED BY

Eric Lindquist, DMV
DABVP, Cert. IVUS

IMAGING PERFORMED BY

Diane McFadden, RVT

HOSPITAL NAME

Sova AH

REFERRING VET

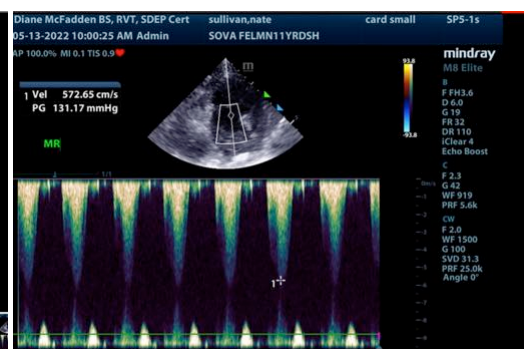
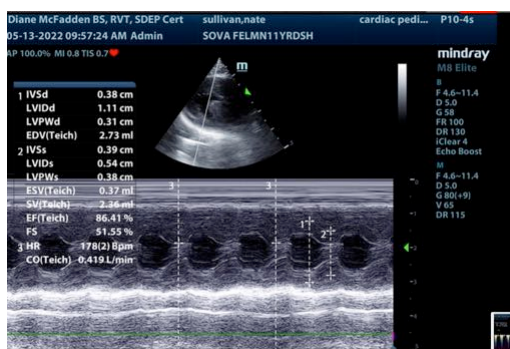
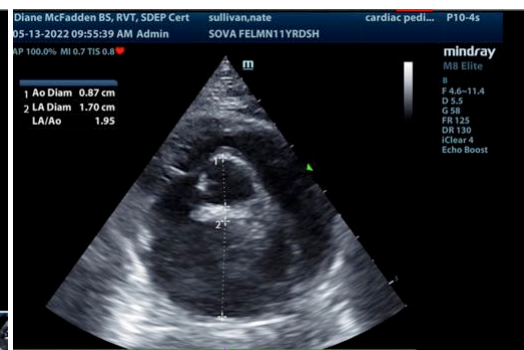
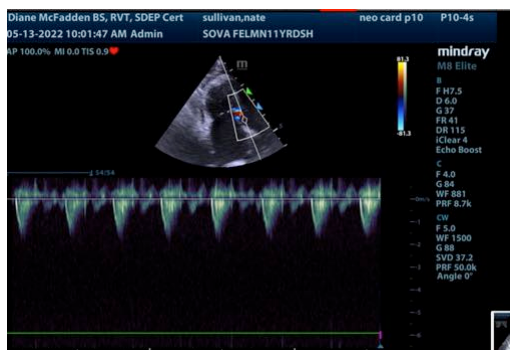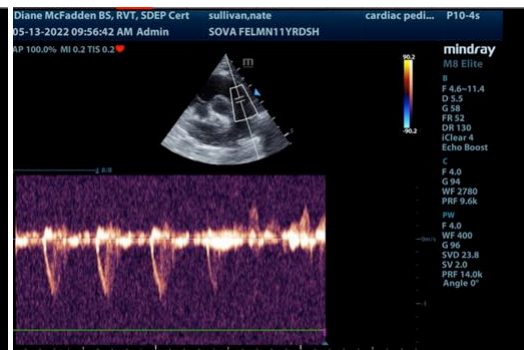
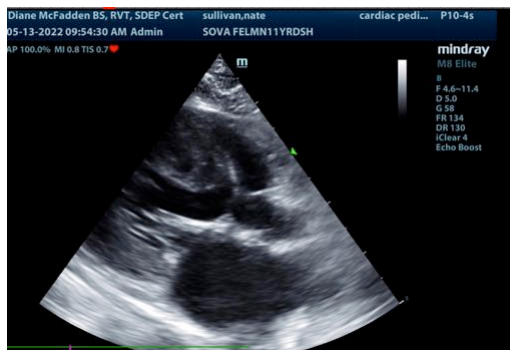
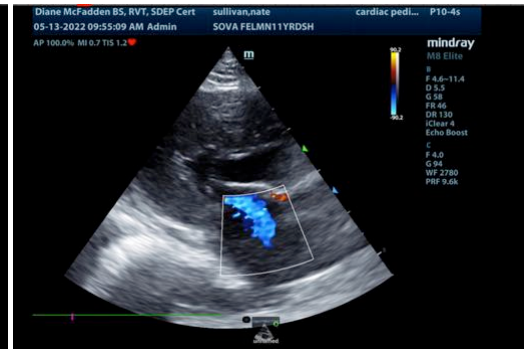
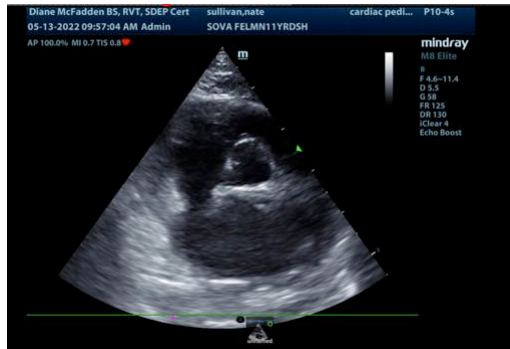
Dr. Sova

INVOICE

30380

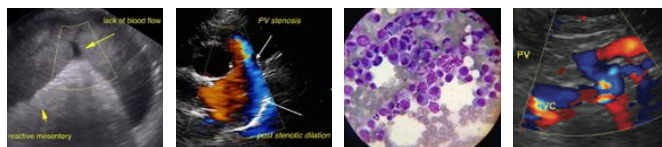
DATE

5/13/22



The information and recommendations provided are based on the images presented by the referring veterinarian/sonographer. No evaluation can be communicated regarding pathology that was not visible in the image/video clips provided.

Thank you for this referral. If the clinical or image interpretation does not parallel your findings or if I can be of any further assistance please contact me.



PATIENT

Nate Sullivan

Eric Lindquist, DMV, DABVP, Cert. IVUSS, CEO of SonoPath.com
Info@SonoPath.com

SPECIES

Feline

BREED

Domestic Shorthair

SEX

Neutered male

AGE

11 years

WEIGHT

10.7 lbs

INTERPRETED BY

Eric Lindquist, DMV
DABVP, Cert. IVUSS

**IMAGING
PERFORMED BY**

Diane McFadden, RVT

HOSPITAL NAME

Sova AH

REFERRING VET

Dr. Sova

INVOICE

30380

DATE

5/13/22