

**DATE**

5/13/22

PRESENTING CLINICAL SIGNS

History: Chronic and recurring UTI.

PATIENT

Marley Rizzo

Current Medications: Will start Abs for UTI tomorrow.

Lab Results: Renal disease.

Date of Previous IntraPet Ultrasound: No previous.

Sedation: Declined.

SPECIES

Canine

Stat Report: Not requested.

Imaging Performed By: Rachel Brillhart, RDMS.

BREED**ULTRASONOGRAPHIC EXAMINATION OF THE ABDOMEN****Urinary System**

The **urinary bladder**, trigone, and pelvic urethra presented normal thicknesses and normal tone. The ureters were not visible which is normal. A minor amount of dependent debris was noted in the bladder. No evidence of inflammatory or neoplastic changes were noted. Ureteral papillae were normal.

The residual **prostate** was uniform, measuring 1.7 cm. Pre- and post-prostatic urethra was unremarkable.

The **kidneys** revealed normal size and structure, corticomedullary definition and ratio for this age. The cortices presented largely uniform texture with normal echogenic relationship to liver and spleen. Medullary structure differed distinctly from the cortex and no evidence of pelvic dilation was present. The capsules were acceptably uniform without significant irregularities. The right kidney measured 7.02 cm. The left kidney measured 6.32 cm.

Adrenal Glands

The **right adrenal gland** was visualized and recognized as having normal shape, size, position and echogenicity for this breed. The phrenic vasculature, glandular echogenicity and detail were unremarkable. Capsule, cortex, and medullary definition were normal for this age patient. The right adrenal gland measured 3.23 cm x 0.88 cm at the cranial pole and 0.82 cm at the caudal pole.

The **left adrenal gland** was slightly enlarged, given the persistent isosthenuria. Emerging PDH may be an issue. The left adrenal gland measured the upper limits of normal.

Spleen

The **spleen** presented a smooth homogeneous parenchyma hyperechoic to liver and renal cortical parenchyma. The capsule was smooth without noticeable expansion or deviation from within the spleen or adjacent pathology. The splenic vasculature demonstrated normal volume without signs of congestion or thrombosis. No sonographic evidence of acute or chronic inflammatory, neoplastic, or infarctual changes were noted.

Liver

The **liver** images submitted revealed subjectively normal liver size, contour, and structure. Parenchymal echogenicity was naturally coarse and hypoechoic to the spleen. Vascular and biliary tracts were of normal volume with no evidence of congestion. The gallbladder presented acceptably thin walls with primarily anechoic content. The cystic and common bile ducts were normal. No pathological hepatic

INTERPRETED BYEric Lindquist, DMV
DABVP, Cert. IVUSS**HOSPITAL NAME**

Companion ACC

REFERRING VET

Dr. Johnston

INVOICE

15182

lymphadenopathy was evident. No overt structural evidence of inflammatory, infiltrative or regenerative pathology was evident.

Gastrointestinal

Examination of the **gastrointestinal tract** revealed a stomach and intestine free of stasis, of normal wall thickness, acceptable curvilinear mural detail, and peristaltic activity. Small and large intestine demonstrated normal luminal chyme and stool consistency respectively. No obstructive or overt infiltrative disease was noted. No associated abnormal lymphatic activity was noted.

Pancreas

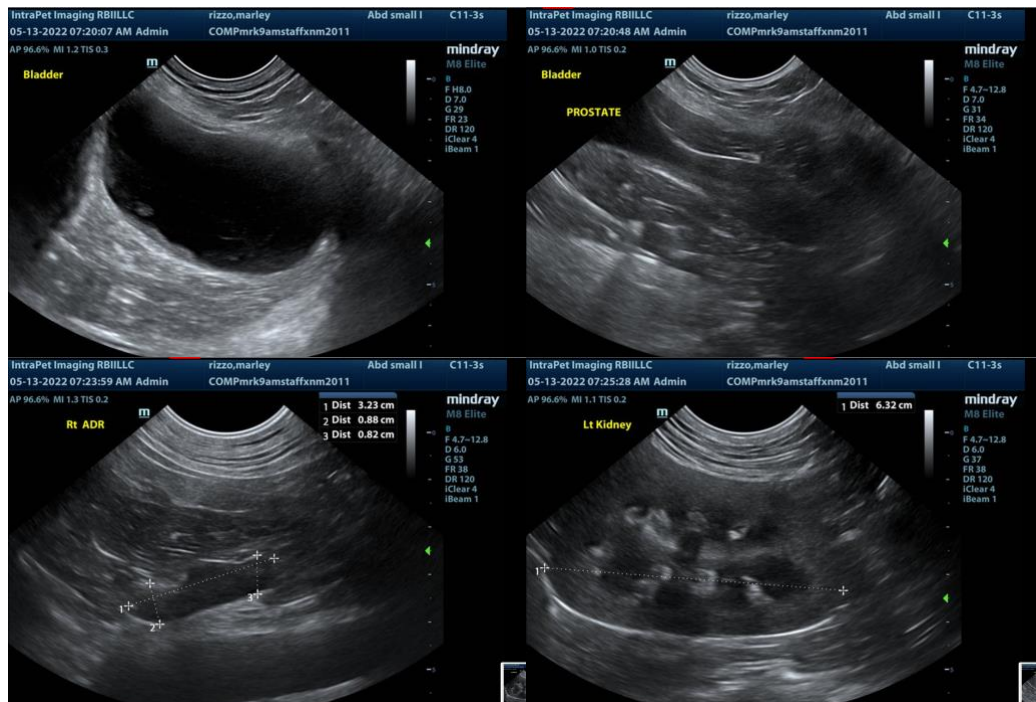
The base and limbs of the **pancreas** were observed to be largely isoechoic to surrounding omental fat. Pancreatic duct and capsular contour were acceptably normal and parenchyma respected normal curvilinear patterns. No overt evidence of active inflammatory or neoplastic disease was noted.

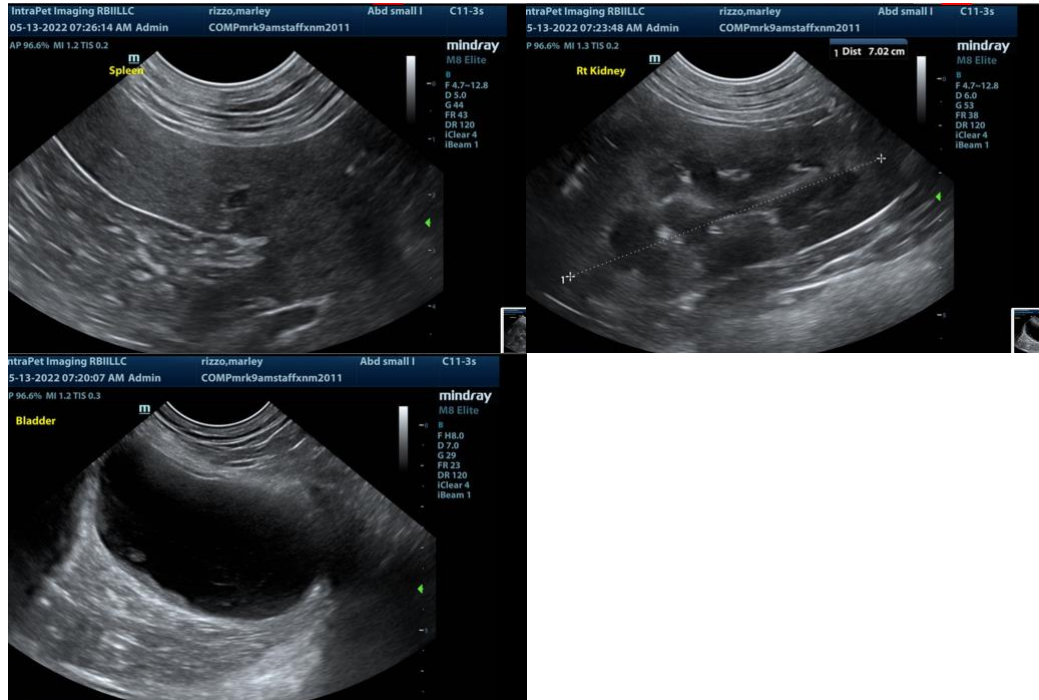
ULTRASONOGRAPHIC FINDINGS

- Minor urinary bladder debris, nonspecific presentation
- Slightly enlarged left adrenal gland, given the persistent isosthenuria

INTERPRETATION OF THE FINDINGS & FURTHER RECOMMENDATIONS

If antibiotic treatment period of 4-weeks or more has not been utilized, then this is likely what would be necessary for potential clearing.





The information and recommendations provided are based on the images presented by the referring veterinarian. No evaluation can be communicated regarding pathology that was not visible in the image/video clips provided.

Thank you for this referral. If the clinical or image interpretation does not parallel your findings or if I can be of any further assistance please contact me.

Eric Lindquist, DMV, DABVP, Cert. IVUSS, CEO of SonoPath.com
Eric.Lindquist@SonoPath.com