



**PATIENT**

Delilah Naidu

**SPECIES**

Canine

**BREED**

Mix

**SEX**

Spayed Female

**AGE**

5 years

**WEIGHT**

18.8 lbs

**INTERPRETED BY**

Eric Lindquist, DMV  
DABVP, Cert. IVUSS

**IMAGING PERFORMED BY**

Dr. Schroeder

**HOSPITAL NAME**

Animal Health  
Associates

**REFERRING VET**

Dr. Schroeder

**INVOICE**

30396

**DATE**

5/13/22

**PRESENTING CLINICAL SIGNS**

History: Vomiting with blood noted on 5/9. No known dietary indiscretion. Chem and CBC were normal. Fecal testing positive for giardia. Patient was started on bland diet, omeprazole and metronidazole. Intermittent vomiting has continued, with intermittent blood.  
Abnormal PE/Chem/CBC/UA Results: Patient is BAR, with soft yellow stool. Not tender on palpation. CHem, CBC, Spec cPL are pending.

**ULTRASONOGRAPHIC EXAMINATION OF THE ABDOMEN**

**Urinary System**

The **urinary bladder**, trigone, and pelvic urethra presented normal thicknesses and normal tone. The pelvic urethra was imaged 2.0 cm beyond the cystourethral junction. The ureters were not visible which is normal. No uroliths or sediment were visualized and anechoic urine was present. No evidence of inflammatory or neoplastic changes was noted. Ureteral papillae were normal.

The **kidneys** revealed normal size and structure, corticomedullary definition and ratio for this age. The cortices presented largely uniform texture with normal echogenic relationship to liver and spleen. Medullary structure differed distinctly from the cortex and no evidence of pelvic dilation was present. The capsules were acceptably uniform without significant irregularities. The left kidney measured 4.42 cm. The right kidney measured 4.5 cm.

**Adrenal Glands**

Both **adrenal glands** were visualized and recognized as having normal shape, size, position and echogenicity for this breed. The phrenic vasculature, glandular echogenicity and detail were unremarkable. Capsule, cortex, and medullary definition were normal for this age patient. The left adrenal gland measured 0.41 cm at the caudal pole and 0.48 cm at the cranial pole. The right adrenal gland measured 0.67 cm at the caudal pole and 0.68 cm at the cranial pole.

**Spleen**

The **spleen** presented a smooth homogeneous parenchyma hyperechoic to liver and renal cortical parenchyma. The capsule was smooth without noticeable expansion or deviation from within the spleen or adjacent pathology. The splenic vasculature demonstrated normal volume without signs of congestion or thrombosis. No sonographic evidence of acute or chronic inflammatory, neoplastic, or infarctual changes was noted.

**Liver**

The **liver** images submitted revealed subjectively normal liver size, contour, and structure. Parenchymal echogenicity was naturally coarse and hypoechoic to the spleen. Vascular and biliary tracts were of normal volume with no evidence of congestion. The gallbladder presented acceptably thin walls with primarily anechoic content. The cystic and common bile ducts were normal. No pathological hepatic lymphadenopathy was evident. No overt structural evidence of inflammatory, infiltrative or regenerative pathology was evident.



**PATIENT**

Delilah Naidu

**Gastrointestinal**

**SPECIES**

Canine

**Pancreas**

**BREED**

Mix

The base and limbs of the **pancreas** were observed to be largely isoechoic to surrounding omental fat. Pancreatic duct and capsular contour were acceptably normal and parenchyma respected normal curvilinear patterns. No overt evidence of active inflammatory or neoplastic disease was noted.

**SEX**

Spayed Female

**ULTRASONOGRAPHIC FINDINGS**

Non-specific gastritis pattern, possible microulcerative disease.

**AGE**

5 years

**INTERPRETATION OF THE FINDINGS & FURTHER RECOMMENDATIONS**

Endoscopy is warranted if clinical trial of the following does not prove effective.

**WEIGHT**

18.8 lbs

**Helicobacter/Gastritis protocol**

A clinical trial of **Zithromax** (Dogs: 5-10 mg/kg p.o. q24h. May increase dosing interval to q48h after 3-5 days of treatment), **Metronidazole** (10-20 mg/kg p.o. b.i.d.), **Sucralfate** (0.5-2 g/dog PO) and **Omeprazole** (1 mg/kg p.o. s.i.d.) over the next 3 weeks along with a **novel-protein or hydrolyzed diet** with slurry feeding b.i.d./t.i.d. over the next 2-4 days and then increase to canned diet bid. Dry food should be avoided over the next 4 weeks. A recheck sonogram to assess GI improvement or progression would be ideal in 4 weeks.

**INTERPRETED BY**

Eric Lindquist, DMV  
DABVP, Cert. IVUSS

**IMAGING PERFORMED BY**

Dr. Schroeder

**HOSPITAL NAME**

Animal Health  
Associates

**REFERRING VET**

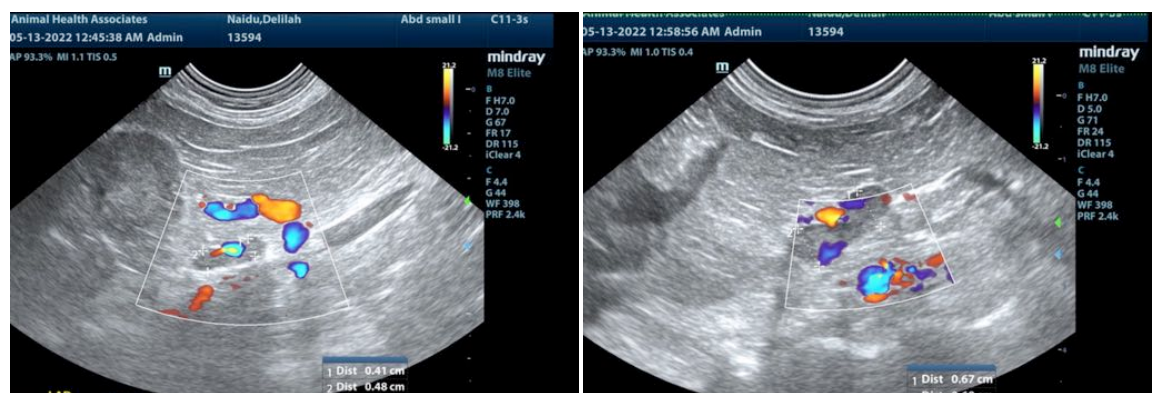
Dr. Schroeder

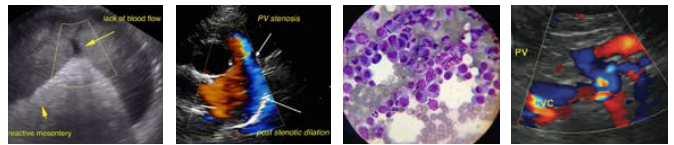
**INVOICE**

30396

**DATE**

5/13/22





**PATIENT**

Delilah Naidu

**SPECIES**

Canine

**BREED**

Mix

**SEX**

Spayed Female

**AGE**

5 years

**WEIGHT**

18.8 lbs

**INTERPRETED BY**

Eric Lindquist, DMV  
DABVP, Cert. IVUSS

**IMAGING PERFORMED BY**

Dr. Schroeder

**HOSPITAL NAME**

Animal Health  
Associates

**REFERRING VET**

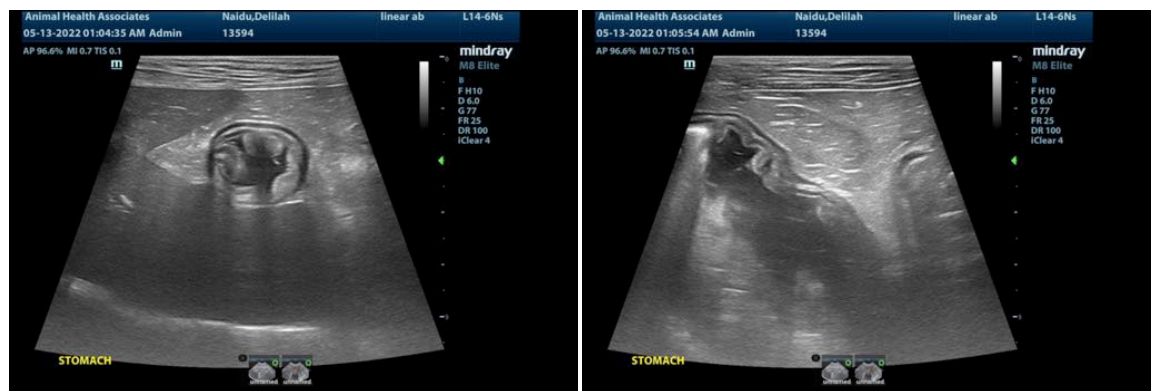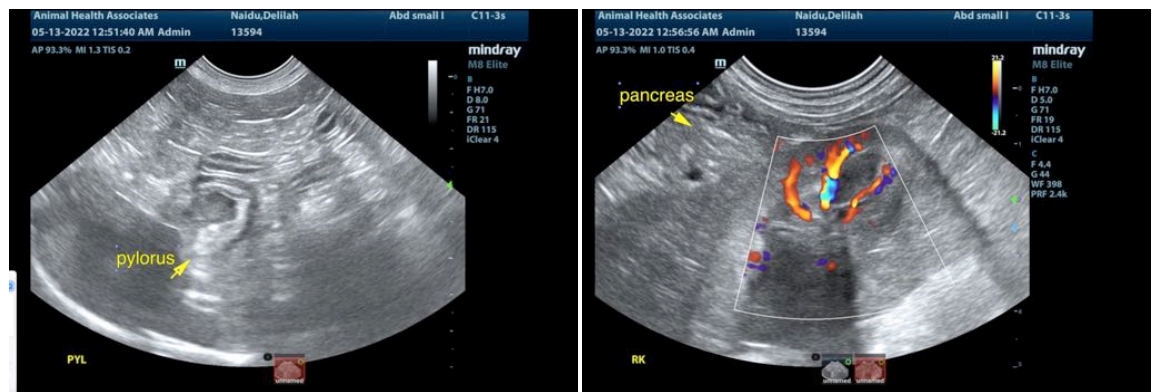
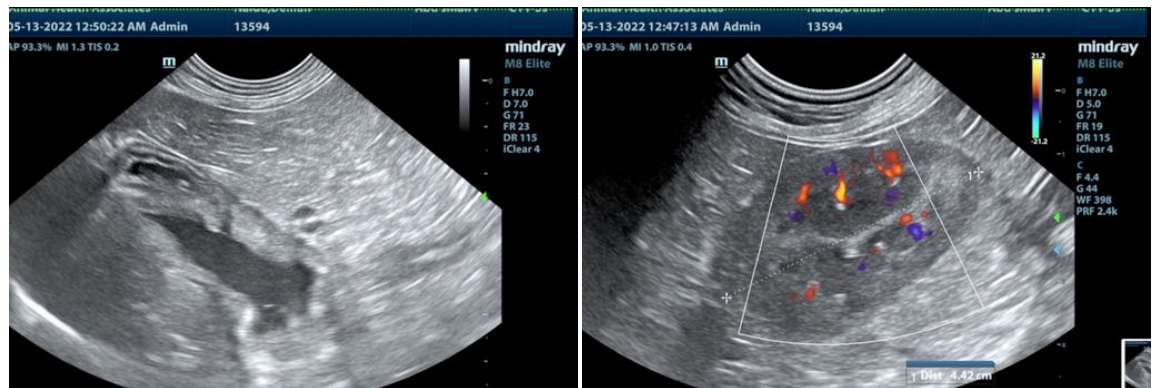
Dr. Schroeder

**INVOICE**

30396

**DATE**

5/13/22



The information and recommendations provided are based on the images presented by the referring veterinarian/sonographer. No evaluation can be communicated regarding pathology that was not visible in the image/video clips provided.

Thank you for this referral. If the clinical or image interpretation does not parallel your findings or if I can be of any further assistance please contact me.

Eric Lindquist, DMV, DABVP, Cert. IVUSS, CEO of SonoPath.com  
info@SonoPath.com