

**DATE**

5/13/22

PRESENTING CLINICAL SIGNS

History: Elevated liver enzymes 3/15/22.

PATIENT

Chi Chi Bennett

Current Medications: Denamarin started 3/17/22 for a month.

Lab Results: Elevated ALKP and ALT. Dex suppression test results were WNL.

Date of Previous IntraPet Ultrasound: No previous.

Sedation: Not required to complete full diagnostic ultrasound.

Stat Report: Not requested.

Imaging Performed By: Rachel Brillhart, RDMS.

SPECIES

Canine

BREED

Jug

SEX

Spayed Female

AGE

11/5/2008

WEIGHT

18.8 Pounds

ULTRASONOGRAPHIC EXAMINATION OF THE ABDOMEN**Urinary System**

The **urinary bladder**, trigone, and pelvic urethra presented normal thicknesses and normal tone. The ureters were not visible which is normal. No uroliths or sediment were visualized and anechoic urine was present. No evidence of inflammatory or neoplastic changes were noted. Ureteral papillae were normal.

The **kidneys** revealed largely normal size and structure, corticomedullary definition and ratio (cortex 1/3 of medulla) were essentially maintained with some minor age-related loss of curvilinear patterns regarding the capsule and C/M junction. The cortices presented largely uniform texture with some increased echogenicity expected for his age patient. Medullary structure differed distinctly from that of the cortex and no evidence of pelvic dilation was present. Mineralization was noted in the kidneys. The left kidney measured 4.5 cm. The right kidney measured 4.45 cm. Mineralization in the right kidney measured up to 0.3 cm.

INTERPRETED BYEric Lindquist, DMV
DABVP, Cert. IVUSS**Adrenal Glands**

The **left adrenal gland** was visualized and recognized as having normal shape, size, position and echogenicity for this breed. The phrenic vasculature, glandular echogenicity and detail were unremarkable. Capsule, cortex, and medullary definition were normal for this age patient. The left adrenal gland measured 1.72 cm x 0.64 cm at the caudal pole and 0.57 cm at the cranial pole.

HOSPITAL NAME

Animal Care Center

The **right adrenal gland** was slightly heterogeneous at the cranial pole, measuring 0.91 cm at the cranial pole and 0.78 cm at the caudal pole x 2.21 cm. A nodule at the cranial pole measured 1.31 cm x 0.86 cm. No evidence of vascular invasion noted from the right adrenal or capsular escape.

REFERRING VET

Dr. Beavers

Spleen

The **spleen** presented a smooth homogeneous parenchyma hyperechoic to liver and renal cortical parenchyma. The capsule was smooth without noticeable expansion or deviation from within the spleen or adjacent pathology. The splenic vasculature demonstrated normal volume without signs of congestion or thrombosis. No sonographic evidence of acute or chronic inflammatory, neoplastic, or infarctual changes were noted.

INVOICE

15179

Liver

The **liver** revealed increased portal markings and coalescing hypoechoic nodular changes. A mild to moderate amount of remodeling noted in the liver. The gallbladder and common bile duct were unremarkable.

Gastrointestinal

Examination of the **gastrointestinal tract** revealed a stomach and intestine free of stasis, of normal wall thickness, acceptable curvilinear mural detail, and peristaltic activity. Small and large intestine demonstrated normal luminal chyme and stool consistency respectively. No obstructive or overt infiltrative disease was noted. No associated abnormal lymphatic activity was noted.

Pancreas

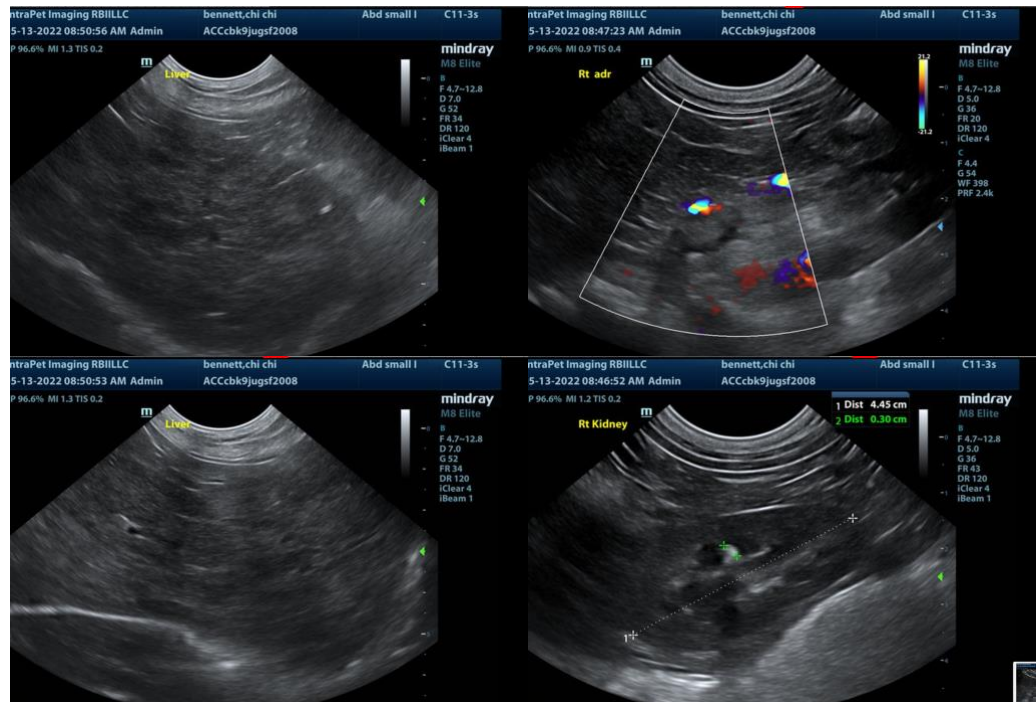
The base and limbs of the **pancreas** were observed to be largely isoechoic to surrounding omental fat. Some minor parenchymal remodeling, however, with mild deviation from curvilinear normalcy was observed. Pancreatic duct and capsular irregularities were present consistent with age related changes. If pain upon imaging (+ Murphy sign) was present or if the patient is focally painful in subxyphoid palpation then low-grade smoldering chronic pancreatitis should be suspected.

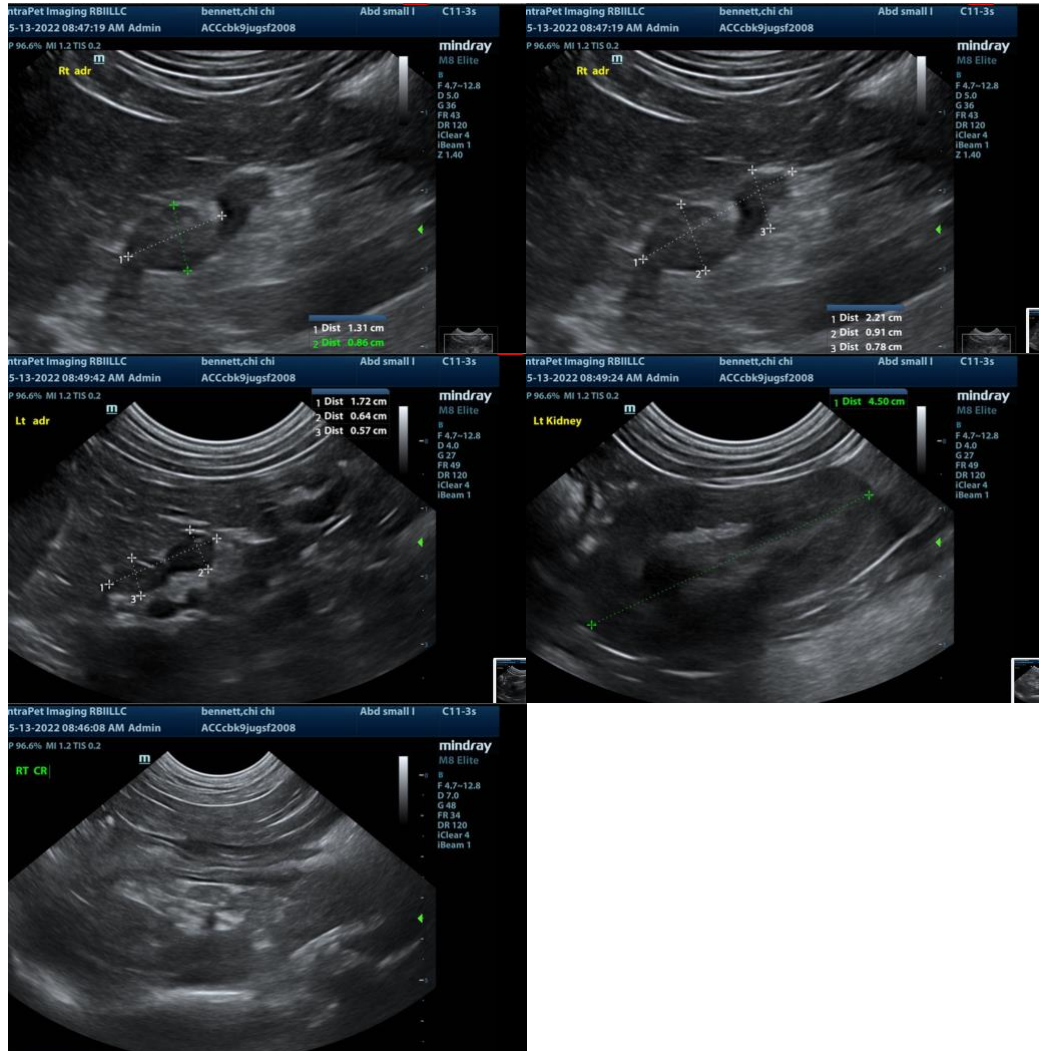
ULTRASONOGRAPHIC FINDINGS

- Hepatic remodeling, nonspecific
- Age-related pancreatic and renal changes with mineralization in the kidneys
- Right adrenal nodule, likely adenoma, mild potential for carcinoma

INTERPRETATION OF THE FINDINGS & FURTHER RECOMMENDATIONS

If hypertension is an issue, then urine catecholamine indicated. Bile acid profile would be ideal. Core liver biopsy would be ideal or FNA to assess inflammatory cell type. No suspicion of neoplasia.





The information and recommendations provided are based on the images presented by the referring veterinarian. No evaluation can be communicated regarding pathology that was not visible in the image/video clips provided.

Thank you for this referral. If the clinical or image interpretation does not parallel your findings or if I can be of any further assistance please contact me.

Eric Lindquist, DMV, DABVP, Cert. IVUSS, CEO of SonoPath.com
 Eric.Lindquist@SonoPath.com