

**PATIENT**

Tucker McKimm

**SPECIES**

Feline

**BREED**

DSH

**SEX**

Neutered Male

**AGE**

15 Years

**WEIGHT**

9.01

**INTERPRETED BY**

Eric Lindquist, DMV,  
DABVP(CFM), Cert.  
IVUSS

**IMAGING PERFORMED BY**

Heather

**HOSPITAL NAME**

Animal Care Clinic of  
Flanders

**REFERRING VET**

Dr. Turner

**INVOICE**

16155

**DATE**

05/12/26

**PRESENTING CLINICAL SIGNS**

Weight loss - at his lowest weight right now. HX of IBD, last abd u/s was 12/2025. Normal echo 10/2025

flow murmur, intermittent diarrhea. grade four murmur ausculted on 5/8, grade 2 today. diarrhea does not resolve with PREDNISOLONE; he will not eat hydrolyzed diet. considering budesonide.

Abnormal PE/Chem/CBC/UA Results: B12 inj. every other week. tapazole TD 100mg/ml - 0.075 AST (lo) 12, CK hi(518) USG - 1.026

**ULTRASONOGRAPHIC EXAMINATION OF THE HEART & ABDOMEN**

FELINE CARDIAC PARAMETERS	BODY WEIGHT	HR (BPM)	IVSd (cm)	LVIDd (cm)	LVWd (cm)	FS (%)	EF (%)
NORMAL PARAMETER	-----	150-240	0.3-0.6	1.0-2.1	0.25-0.6	35-67	80-100
PATIENT	9.01	200	0.58	1.1	0.49	--	--
FELINE CARDIAC PARAMETERS	LA/AO (M-mode)	LA/AO HEART BASE (Sisson)	LAD LA MAX 4 Chamber		LVOT VEL. (m/s)	RVOT VEL. (m/s)	IVRT (m/)
NORMAL PARAMETER	<1.5	1.6	0.7-1.7		<1.6	<1.3	40-60
PATIENT	1.3	1.5	1.5		--	0.7	NM
Adapted from June Boon, Veterinary Echocardiography, 1998 Sisson D et al. JVIM 1991; 5: 232, Jacobs et al. Am J Vet Res 1985; 46:1705							

**Cardiac Presentation**

The echocardiogram in this patient demonstrated normal **left atrial** size based on 3 separate LA measurements. The cranial and caudal **mitral** valve leaflets presented normal linear structure and kinetics. The **left ventricle** presented normal thicknesses with linear contour and was not dilated nor restricted. The **myocardium** presented normal echogenicity without subjective evidence of significant fibrotic or ischemic disease. **Contractility** of the ventricular walls was adequate and in normal range for this patient evidenced by the fractional shortening measurement and subjective evaluation of the different regions and angles of the myocardium. The **left ventricular outflow** tract demonstrated normal laminar flow and subjective structural integrity. The **right atrium** and auricle revealed normal size, structure and content. No evidence of masses was noted or chamber overload. **Tricuspid** valvular assessment demonstrated trivial insufficiency. The **right ventricle** was of normal size (1/3 diameter of LV), chordae structure, myocardial echogenicity and thickness. **Pulmonic** tract assessment revealed normal valve structure, laminar flow, and diameter (approx.1:1 pa/ao ratio). No visible **pericardial** or free pleura fluid was noted or extra cardiac pathology in the visible planes. The cranial **mediastinum** and **pericardial regions** were free of masses in the visible window.

**Urinary System**



## PATIENT

Tucker McKimm

## SPECIES

Feline

## BREED

DSH

## SEX

Neutered Male

## AGE

15 Years

## WEIGHT

9.01

## INTERPRETED BY

Eric Lindquist, DMV,  
DABVP(CFM), Cert.  
IVUSS

## IMAGING PERFORMED BY

Heather

## HOSPITAL NAME

Animal Care Clinic of  
Flanders

## REFERRING VET

Dr. Turner

## INVOICE

16155

## DATE

05/12/26

The **urinary bladder**, trigone, and pelvic urethra to a depth of 3.0 cm presented normal thicknesses and normal tone. The ureters were not visible which is normal. No uroliths or sediment were visualized, and anechoic urine was present. No evidence of inflammatory or neoplastic changes were noted. Ureteral papillae were normal.

The **kidneys** revealed largely normal size and structure, corticomedullary definition and ratio (cortex 1/3 of medulla) were essentially maintained with some mild age-related loss of curvilinear patterns regarding the capsule and C/M junction. The cortices presented largely uniform texture with some increased echogenicity expected for his age patient. Medullary structure differed distinctly from that of the cortex and no evidence of pelvic dilation was present. The left kidney measured 3.6 cm in length. The right kidney measured 4.1 cm in length.

### **Adrenal Glands**

Both **adrenal glands** were not visualized.

### **Spleen**

The **spleen** presented a smooth homogeneous parenchyma hyperechoic to liver and renal cortical parenchyma. The capsule was smooth without noticeable expansion or deviation from within the spleen or adjacent pathology. The splenic vasculature demonstrated normal volume without signs of congestion or thrombosis. No sonographic evidence of acute or chronic inflammatory, neoplastic, or infarctual changes were noted.

### **Liver**

The **liver** images from right and left intercostal as well as subcostal views revealed subjectively normal liver size, contour, and structure. Some mild age-related parenchymal remodeling was noted but likely not clinically significant at this time. Vascular and biliary tracts were of normal volume and no evidence of congestion was noted. The gallbladder presented some dependent debris with essentially normal contour. The cystic and common bile ducts were normal. No overt evidence of active inflammatory, infiltrative or regenerative pathology was noted but should be paired with current or past LE elevations regarding any clinical significance to this presentation. The hepatic lymph nodes were unremarkable.

### **Gastrointestinal**

The **gastrointestinal tract** revealed minor variable thickening and echogenic submucosal changes most consistent with low grade end result of chronic GI disease such as IBD and may be related to malassimilation of nutrients if any weight loss is present. No obvious neoplastic patterns were noted and luminal content as unremarkable.

### **Pancreas**

The base and limbs of the **pancreas** were observed to be largely isoechoic to surrounding omental fat. Pancreatic duct and capsular contour were acceptably normal and parenchyma respected normal curvilinear patterns. No overt evidence of active inflammatory or neoplastic disease was noted.

### **Free Abdomen**

The mid abdomen revealed a mesenteric cyst that may be of lymph node origin, yet does not appear overtly pathological measuring 2.5 cm.



## PATIENT

Tucker McKimm

## SPECIES

Feline

## BREED

DSH

## SEX

Neutered Male

## AGE

15 Years

## WEIGHT

9.01

## INTERPRETED BY

Eric Lindquist, DMV,  
DABVP(CFM), Cert.  
IUUSS

## IMAGING PERFORMED BY

Heather

## HOSPITAL NAME

Animal Care Clinic of  
Flanders

## REFERRING VET

Dr. Turner

## INVOICE

16155

## DATE

05/12/26

## ULTRASONOGRAPHIC FINDINGS

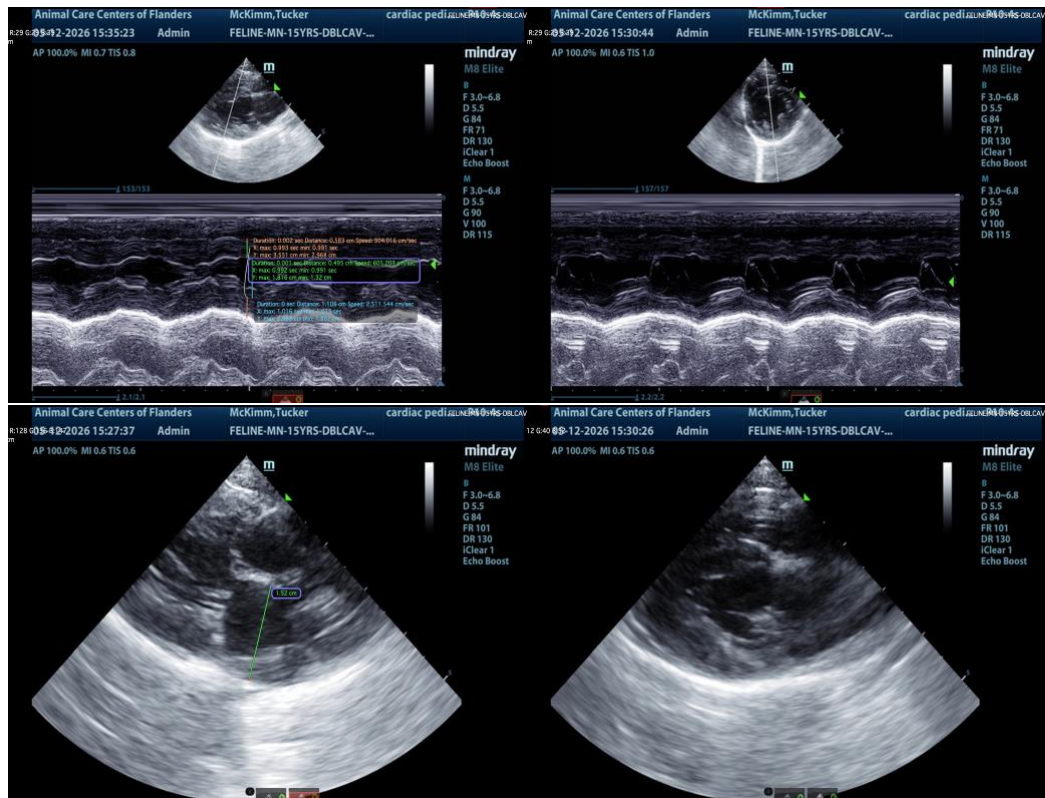
- Normal echocardiogram with trivial tricuspid insufficiency.
- Geriatric abdomen with mesenteric cyst.

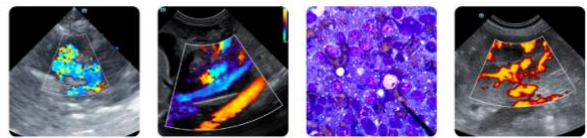
## INTERPRETATION OF THE FINDINGS & FURTHER RECOMMENDATIONS

Ultrasound guided drainage and culture cytology could be considered. Maldigestion panel, three view chest radiographs and full CNS examination is recommended to examine for occult disease that could be responsible for the weight loss. Evaluation for competitive eating environments should also be considered. The prednisone may be suppressing a more significant presentation.

Internal medicine consult can be utilized through SonoPath.com. You can select the internal medicine drop down at <http://spa.sonopath.com/>.

One of the world's top internists & SonoPath associate Dr. Remo Lobetti BVSc, MMedVet, PhD, DECVIM can evaluate your case through SonoPath. <https://sonopath.com/resources/sonopath-services/internal-medicine-teleconsultation-services>





**PATIENT**

Tucker McKimm

**SPECIES**

Feline

**BREED**

DSH

**SEX**

Neutered Male

**AGE**

15 Years

**WEIGHT**

9.01

**INTERPRETED BY**

Eric Lindquist, DMV,  
DABVP(CFM), Cert.  
IVUSS

**IMAGING PERFORMED BY**

Heather

**HOSPITAL NAME**

Animal Care Clinic of  
Flanders

**REFERRING VET**

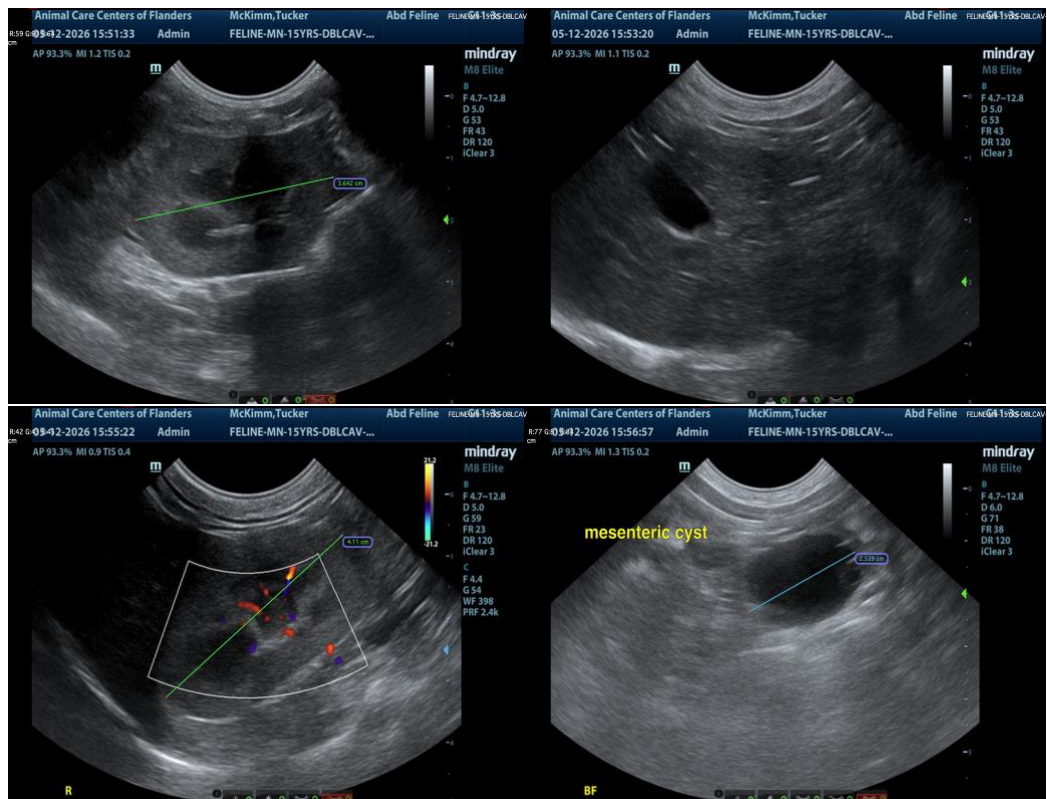
Dr. Turner

**INVOICE**

16155

**DATE**

05/12/26



The information and recommendations provided are based on the images presented by the referring veterinarian/sonographer. No evaluation can be communicated regarding pathology that was not visible in the image/video clips provided.

Thank you for this referral. If the clinical or image interpretation does not parallel your findings or if I can be of any further assistance, please contact me.

**Eric Lindquist, DMV, DABVP(CFM), Cert. IVUSS,**

CEO, Owner, Founder -- SonoPath.com

[info@SonoPath.com](mailto:info@SonoPath.com)