



PATIENT

Mia Hidalgo

SPECIES

Canine

BREED

Poodle Mix

SEX

Spayed Female

AGE

12 Years

WEIGHT

16

INTERPRETED BY

Eric Lindquist, DMV,
DABVP(CFM), Cert.
IVUSS

IMAGING PERFORMED BY

Matt Heinlein

HOSPITAL NAME

TLC Animal Hospital

REFERRING VET

Dr. Mayra Terres

INVOICE

16157

DATE

05/12/26

PRESENTING CLINICAL SIGNS

Patient presented on 05/04/26 for PU/PD & panting. On physical exam patient displayed grade 4 dental disease, grade 3 heart murmur, pendulous abdomen, & a subcutaneous mass on the left side of thorax. Hepatomegaly was appreciated on radiographs. No evidence of cardiomegaly. Blood work results showed unremarkable CBC, 3X ALP elevations, UPC of 0.2, USG 1.025, +1 protein on urinalysis with active sediment, & pH 8.5. Recommended LDDST & abdominal ultrasound. Owner elected to move forward with ACTH stim test & ultrasound today. ACTH stim test revealed pre-7.10 & post-12.77.

Would like to know if there is presence of an adrenal gland tumor or if there is bilateral enlargement of adrenals to determine the next steps for patient.

ULTRASONOGRAPHIC EXAMINATION OF THE ABDOMEN

Urinary System

The **urinary bladder**, trigone, and pelvic urethra presented normal thicknesses and normal tone. The ureters were not visible which is normal. No uroliths or sediment were visualized, and anechoic urine was present. No evidence of inflammatory or neoplastic changes were noted. Ureteral papillae were normal.

The **kidneys** revealed normal size and structure, corticomedullary definition and ratio for this age. The cortices presented largely uniform texture with normal echogenic relationship to liver and spleen. Medullary structure differed distinctly from the cortex and no evidence of pelvic dilation was present. The capsules were acceptably uniform without significant irregularities. The left kidney measured 4.08 cm in length. The right kidney measured 4.07 cm in length.

Adrenal Glands

Both **adrenal glands** were visualized and recognized as having normal shape, size, position and echogenicity for this breed. The phrenic vasculature, glandular echogenicity and detail were unremarkable. Capsule, cortex, and medullary definition were normal for this age patient. The right adrenal gland measured 0.39 cm width at the caudal pole and 0.36 cm width at the cranial pole. The left adrenal gland measured 0.45 cm width at the caudal pole and 0.4 cm width at the cranial pole.

Spleen

The **spleen** presented a smooth homogeneous parenchyma hyperechoic to liver and renal cortical parenchyma. The capsule was smooth without noticeable expansion or deviation from within the spleen or adjacent pathology. The splenic vasculature demonstrated normal volume without signs of congestion or thrombosis. No sonographic evidence of acute or chronic inflammatory, neoplastic, or infarctual changes were noted.

Liver

The **liver** presented with minor uniform swelling and slightly heterogenous parenchymal changes yet appears subjectively benign. The gallbladder and common bile duct were unremarkable.

Gastrointestinal

Examination of the **gastrointestinal tract** revealed a stomach and intestine free of stasis, of normal wall thickness, acceptable curvilinear mural detail, and peristaltic activity. Small and large intestine



PATIENT

Mia Hidalgo

SPECIES

Canine

BREED

Poodle Mix

SEX

Spayed Female

AGE

12 Years

WEIGHT

16

INTERPRETED BY

Eric Lindquist, DMV,
DABVP(CFM), Cert.
IVUSS

IMAGING PERFORMED BY

Matt Heinlein

HOSPITAL NAME

TLC Animal Hospital

REFERRING VET

Dr. Mayra Terres

INVOICE

16157

DATE

05/12/26

demonstrated normal luminal chyme and stool consistency respectively. No obstructive or overt infiltrative disease was noted. No associated abnormal lymphatic activity was noted.

Pancreas

The base and limbs of the **pancreas** were observed to be largely isoechoic to surrounding omental fat. Pancreatic duct and capsular contour were acceptably normal and parenchyma respected normal curvilinear patterns. No overt evidence of active inflammatory or neoplastic disease was noted.

ULTRASONOGRAPHIC FINDINGS

- Structurally unremarkable abdomen.
- Benign hepatomegaly with minor remodeling.
- Structurally normal adrenal glands.

INTERPRETATION OF THE FINDINGS & FURTHER RECOMMENDATIONS

If urine specific gravity continues to drop and urine cortisol/creatinine ratio is elevated, then there is a potential for emerging PDH. However, this would not be the norm. Other endocrinopathies should be considered such as hypothyroidism, if not already assessed. Yet this may be a normal variant for this patient of this age.

Internal medicine consult can be utilized through SonoPath.com. You can select the internal medicine drop down at <http://spa.sonopath.com/>.

One of the world's top internists & SonoPath associate Dr. Remo Lobetti BVSc, MMedVet, PhD, DECVIM can evaluate your case through SonoPath. <https://sonopath.com/resources/sonopath-services/internal-medicine-teleconsultation-services>



PATIENT

Mia Hidalgo

SPECIES

Canine

BREED

Poodle Mix

SEX

Spayed Female

AGE

12 Years

WEIGHT

16

INTERPRETED BY

Eric Lindquist, DMV,
DABVP(CFM), Cert.
IVUSS

IMAGING PERFORMED BY

Matt Heinlein

HOSPITAL NAME

TLC Animal Hospital

REFERRING VET

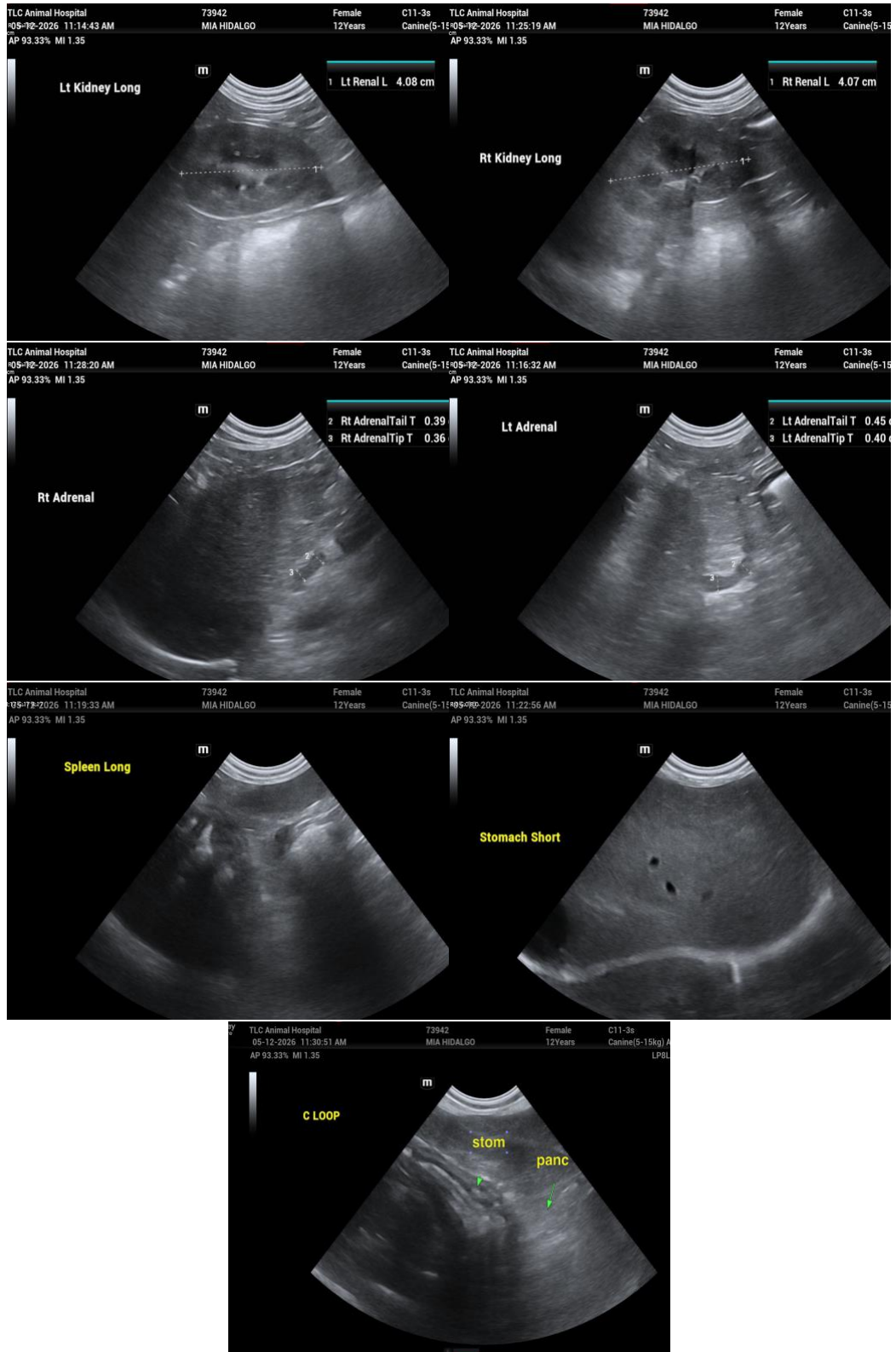
Dr. Mayra Terres

INVOICE

16157

DATE

05/12/26





PATIENT

Mia Hidalgo

SPECIES

Canine

BREED

Poodle Mix

SEX

Spayed Female

AGE

12 Years

WEIGHT

16

INTERPRETED BY

Eric Lindquist, DMV,
DABVP(CFM), Cert.
IVUSS

IMAGING PERFORMED BY

Matt Heinlein

HOSPITAL NAME

TLC Animal Hospital

REFERRING VET

Dr. Mayra Terres

INVOICE

16157

DATE

05/12/26

The information and recommendations provided are based on the images presented by the referring veterinarian/sonographer. No evaluation can be communicated regarding pathology that was not visible in the image/video clips provided.

Thank you for this referral. If the clinical or image interpretation does not parallel your findings or if I can be of any further assistance, please contact me.

Eric Lindquist, DMV, DABVP(CFM), Cert. IVUSS,

CEO, Owner, Founder -- SonoPath.com

info@SonoPath.com