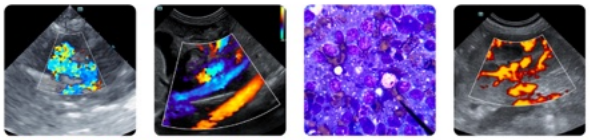

PATIENT

Carmella Sorensen

SPECIES

Canine

BREED

Labrador Mix

SEX

Spayed female

AGE

15 years

WEIGHT

67 lbs

INTERPRETED BY

Eric Lindquist, DMV DABVP, Cert. IVUSS

IMAGING PERFORMED BY

Katharine Nowland, DVM

HOSPITAL NAME

TotalBond VH

REFERRING VET

Dr. Nowland

INVOICE

75389

DATE

5/12/26

PRESENTING CLINICAL SIGNS

History: Patient presented on Saturday for weakness, lethargy, and inappetence. O noted patient has been panting more and having more difficulty walking. Bloodwork performed with mild abnormalities noted below. Large mass noted on R side of body and smaller but still large mass noted along R body wall. Appears to be under the ribs, aspirated today and looks most consistent with a lipoma. Returned today because continues to not eat, vomited once, and is lethargic and collapsing at home (not able to walk on own). Discussed QOL - O would like to proceed with ultrasound and palliative care at this time to see what's going on.
Abnormal PE/Chem/CBC/UA Results: Neutrophilia 13.1 Platlets 481 ALT 198 ALKP 1416 Lipase 357 T4 0.9

ULTRASONOGRAPHIC EXAMINATION OF THE ABDOMEN

Urinary System

The **urinary bladder**, trigone, and pelvic urethra presented normal thicknesses and normal tone. The ureters were not visible which is normal. No uroliths or sediment were visualized and anechoic urine was present. No evidence of inflammatory or neoplastic changes was noted. Ureteral papillae were normal.

The **kidneys** revealed largely normal size and structure, corticomedullary definition and ratio (cortex 1/3 of medulla) were essentially maintained with some age-related loss of curvilinear patterns regarding the capsule and C/M junction. The cortices presented largely uniform texture with some increased echogenicity expected for this age patient. Medullary structure differed distinctly from that of the cortex and no evidence of pelvic dilation was present. The left kidney measured 6.0 cm. The right kidney measured 6.9 cm.

Adrenal Glands

Both **adrenal glands** were visualized and recognized as having normal shape, size, position and echogenicity for this breed. The phrenic vasculature, glandular echogenicity and detail were unremarkable. Capsule, cortex, and medullary definition were normal for this age patient. The right adrenal gland measured 1.98 x 0.7 cm. The left adrenal gland measured 2.07 x 0.4 cm.

Spleen

The **spleen** revealed heterogenous parenchymal changes and was folded upon itself cranially.

Liver

The **liver** images from right and left intercostal as well as subcostal views revealed subjectively normal liver size, contour, and structure. Some age-related parenchymal remodeling was noted but likely not clinically significant at this time. Vascular and biliary tracts were of normal volume and no evidence of congestion was noted. Minor gallbladder sand/small choleliths was noted.

PATIENT

Carmella Sorensen

SPECIES

Canine

BREED

Labrador Mix

SEX

Spayed female

AGE

15 years

WEIGHT

67 lbs

INTERPRETED BY

Eric Lindquist, DMV
DABVP, Cert. IVUSS

IMAGING PERFORMED BY

Katharine Nowland, DVM

HOSPITAL NAME

TotalBond VH

REFERRING VET

Dr. Nowland

INVOICE

75389

DATE

5/12/26

Gastrointestinal

Examination of the **gastrointestinal tract** revealed a stomach and intestine free of stasis, of normal wall thickness, acceptable curvilinear mural detail, and peristaltic activity. Small and large intestine demonstrated normal luminal chyme and stool consistency respectively. No obstructive or overt infiltrative disease was noted. No associated abnormal lymphatic activity was noted.

Pancreas

The base and limbs of the **pancreas** were observed to be largely isoechoic to surrounding omental fat. Pancreatic duct and capsular contour were acceptably normal and parenchyma respected normal curvilinear patterns. No overt evidence of active inflammatory or neoplastic disease was noted.

ULTRASONOGRAPHIC FINDINGS

Geriatric abdomen.

Minor cholelithiasis.

Heterogenous splenic and hepatic changes, yet subjectively benign.

INTERPRETATION OF THE FINDINGS & FURTHER RECOMMENDATIONS

There was no evidence of abdominal disease directly related to the clinical signs. Orthopedic pain, CNS or thoracic disease should be considered as well as arrhythmogenic disease. No primary abdominal pathology is noted directly related to the clinical history.

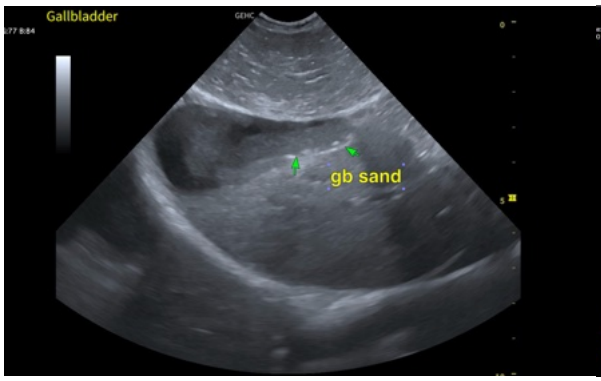

SonoPath
FOSTERING THE ART OF VETERINARY MEDICINE™

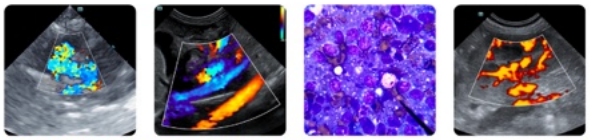

Clinical Sonography & Telecytology
Educational Teleconsultation Services™

SonoPath.com info@sonopath.com 1.800.838.4268

PATIENT

Carmella Sorensen

SPECIES

Canine

BREED

Labrador Mix

SEX

Spayed female

AGE

15 years

WEIGHT

67 lbs

INTERPRETED BY

Eric Lindquist, DMV
DABVP, Cert. IVUSS

IMAGING PERFORMED BY

Katharine Nowland, DVM

HOSPITAL NAME

TotalBond VH

REFERRING VET

Dr. Nowland

INVOICE

75389

DATE

5/12/26

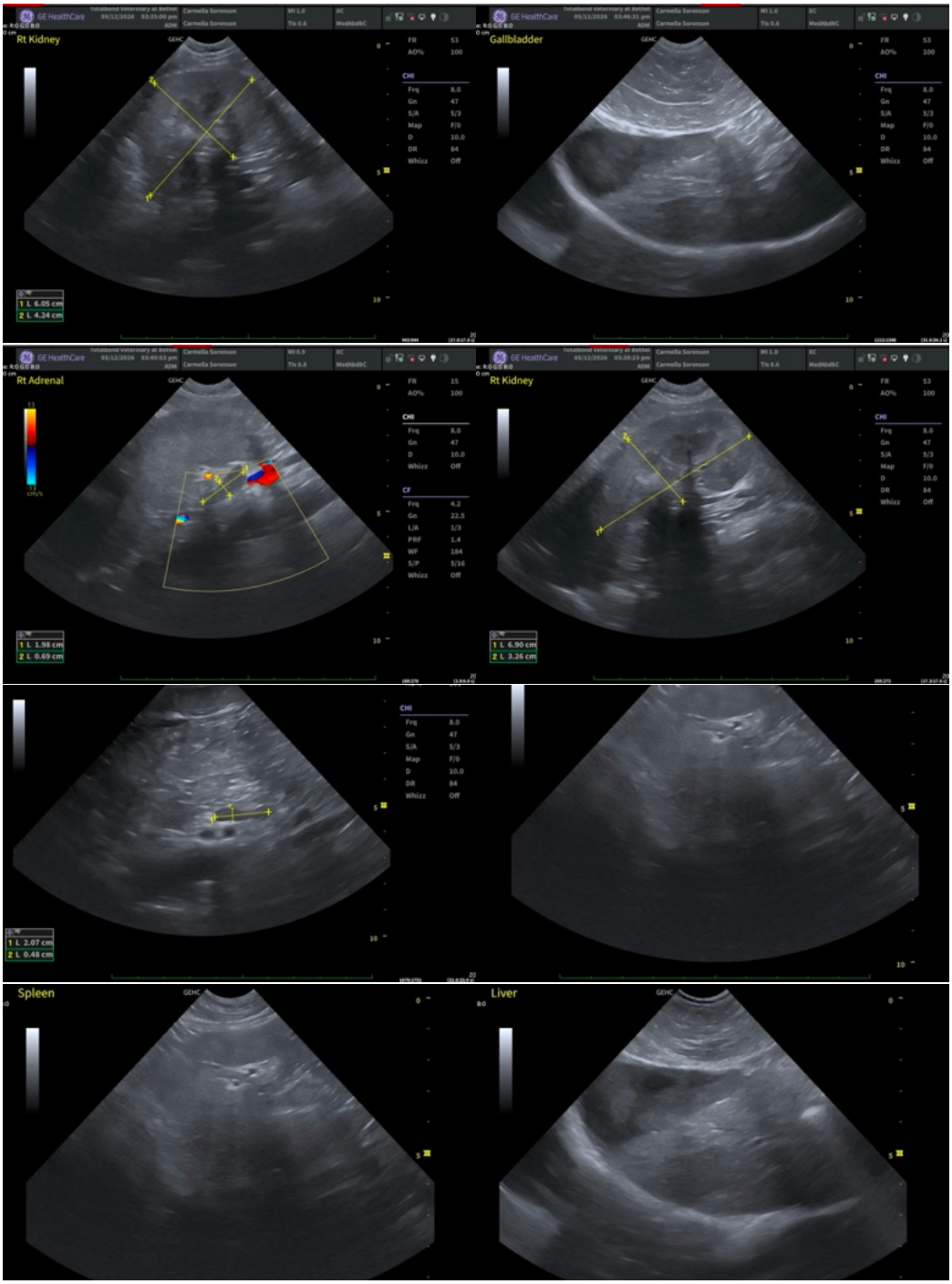

The information and recommendations provided are based on the images presented by the referring veterinarian/sonographer. No evaluation can be communicated regarding pathology that was not visible in the image/video clips provided.

Thank you for this referral. If the clinical or image interpretation does not parallel your findings or if I

PATIENT

Carmella Sorensen

SPECIES

Canine

BREED

Labrador Mix

SEX

Spayed female

AGE

15 years

WEIGHT

67 lbs

INTERPRETED BY

Eric Lindquist, DMV
DABVP, Cert. IVUSS

IMAGING PERFORMED BY

Katharine Nowland, DVM

HOSPITAL NAME

TotalBond VH

REFERRING VET

Dr. Nowland

INVOICE

75389

DATE

5/12/26

can be of any further assistance please contact me.

Eric Lindquist, DMV, DABVP (CFM), Cert. IVUSS, CEO of SonoPath.com

info@SonoPath.com