



**PATIENT**

Vincent Vega Morgan

**SPECIES**

Canine

**BREED**

Catahoula Leopard Dog

**SEX**

Neutered male

**AGE**

4 years

**WEIGHT**

30.6 kg

**INTERPRETED BY**

Eric Lindquist, DMV  
DABVP, Cert. IVUSS

**IMAGING PERFORMED BY**

Dr. Stegemoller

**HOSPITAL NAME**

North Idaho AH

**REFERRING VET**

Dr. Stegemoller

**INVOICE**

30341

**DATE**

5/12/22

**PRESENTING CLINICAL SIGNS**

One week duration of slight lethargy, less enthusiastic towards eating, and one episode of vomit. Vomit contained partially digested food approx 9 hours post meal. Stools normal. Prior to onset was fed 20% diet from Freeze dried raw diet for one week. Current medications: Fluoxetine 48mg SID; gabapentin 600mg BID CBC, chemistry, UA, spec CPL WNL.

Abnormal PE/Chem/CBC/UA Results: Possible slight splinting on cranial abdominal palpation. CBC/Chem/UA/specCPL - unremarkable Abdominal radiographs showed smaller liver profile (gastric axis tilted cranially).

**ULTRASONOGRAPHIC EXAMINATION OF THE ABDOMEN**

**Urinary System**

The **urinary bladder**, trigone, and pelvic urethra presented normal thicknesses and normal tone. The ureters were not visible which is normal. No uroliths or sediment were visualized and anechoic urine was present. No evidence of inflammatory or neoplastic changes was noted. Ureteral papillae were normal.

The **kidneys** revealed normal size and structure, corticomedullary definition and ratio for this age. The cortices presented largely uniform texture with normal echogenic relationship to liver and spleen. Medullary structure differed distinctly from the cortex and no evidence of pelvic dilation was present. The capsules were acceptably uniform without significant irregularities. The right kidney measured 6.8 cm. The left kidney measured 6.8 cm.

**Adrenal Glands**

Both **adrenal glands** were visualized and recognized as having normal shape, size, position and echogenicity for this breed. The phrenic vasculature, glandular echogenicity and detail were unremarkable. Capsule, cortex, and medullary definition were normal for this age patient. The left adrenal gland measured 2.7 x 0.56 cm at the cranial pole and 0.55 cm at the caudal pole. The right adrenal gland measured 0.5 cm in width and approximately 2.0 cm in length.

**Spleen**

The **spleen** presented a smooth homogeneous parenchyma hyperechoic to liver and renal cortical parenchyma. The capsule was smooth without noticeable expansion or deviation from within the spleen or adjacent pathology. The splenic vasculature demonstrated normal volume without signs of congestion or thrombosis. No sonographic evidence of acute or chronic inflammatory, neoplastic, or infarctual changes was noted.

**Liver**

The **liver** images submitted revealed subjectively normal liver size, contour, and structure. Parenchymal echogenicity was naturally coarse and hypoechoic to the spleen. Vascular and biliary tracts were of normal volume with no evidence of congestion. The gallbladder presented acceptably thin walls with primarily anechoic content. The cystic and common bile ducts were normal. No pathological hepatic



**PATIENT**  
Vincent Vega Morgan

lymphadenopathy was evident. No overt structural evidence of inflammatory, infiltrative or regenerative pathology was evident.

**SPECIES**

**Gastrointestinal**

Canine

Examination of the **gastrointestinal tract** revealed a stomach and intestine free of stasis, of normal wall thickness, acceptable curvilinear mural detail, and peristaltic activity. Small and large intestine demonstrated normal luminal chyme and stool consistency respectively. No obstructive or overt infiltrative disease was noted. No associated abnormal lymphatic activity was noted.

**BREED**

Catahoula Leopard Dog

**SEX**

Neutered male

**Pancreas**

The base and limbs of the **pancreas** were observed to be largely isoechoic to surrounding omental fat. Pancreatic duct and capsular contour were acceptably normal and parenchyma respected normal curvilinear patterns. No overt evidence of active inflammatory or neoplastic disease was noted.

**AGE**

4 years

**ULTRASONOGRAPHIC FINDINGS**

Normal abdomen.

**WEIGHT**

30.6 kg

**INTERPRETATION OF THE FINDINGS & FURTHER RECOMMENDATIONS**

**INTERPRETED BY**

Eric Lindquist, DMV DABVP, Cert. IVUSS

There is no evidence of visceral pathology that would be responsible for the clinical signs. Orthopedic/referred back pain should be considered in this patient as a potential. Screening for Addison's is indicated given the age even though the adrenal glands appear normal. Cardiac evaluation is recommended for arrhythmias or primary cardiac disease should also be considered given the vague clinical signs.

**IMAGING PERFORMED BY**

Dr. Stegemoller

**HOSPITAL NAME**

North Idaho AH

**REFERRING VET**

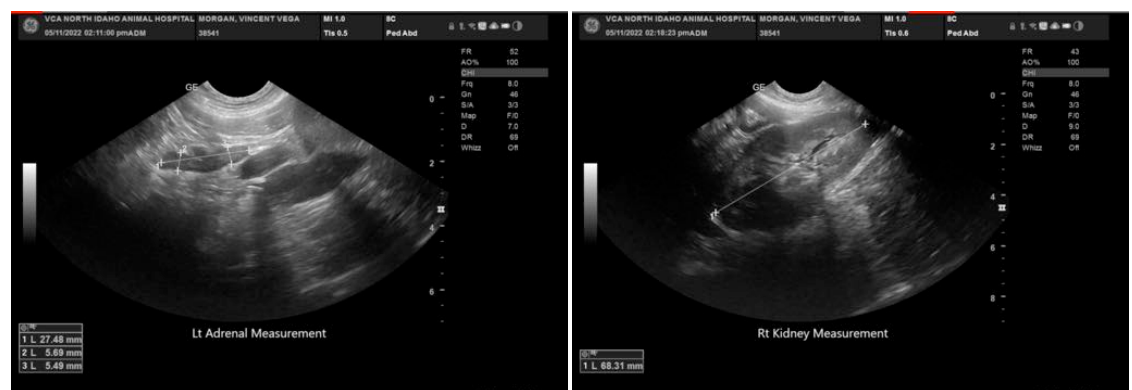
Dr. Stegemoller

**INVOICE**

30341

**DATE**

5/12/22





**PATIENT**

Vincent Vega Morgan

**SPECIES**

Canine

**BREED**

Catahoula Leopard Dog

**SEX**

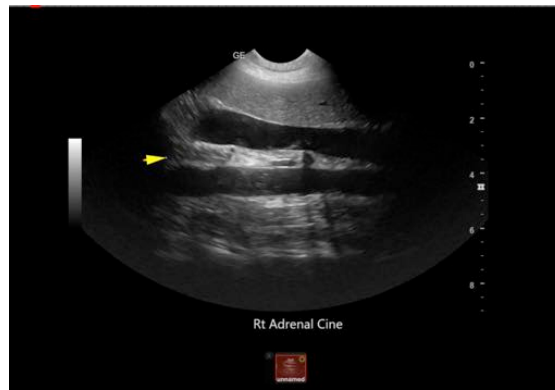
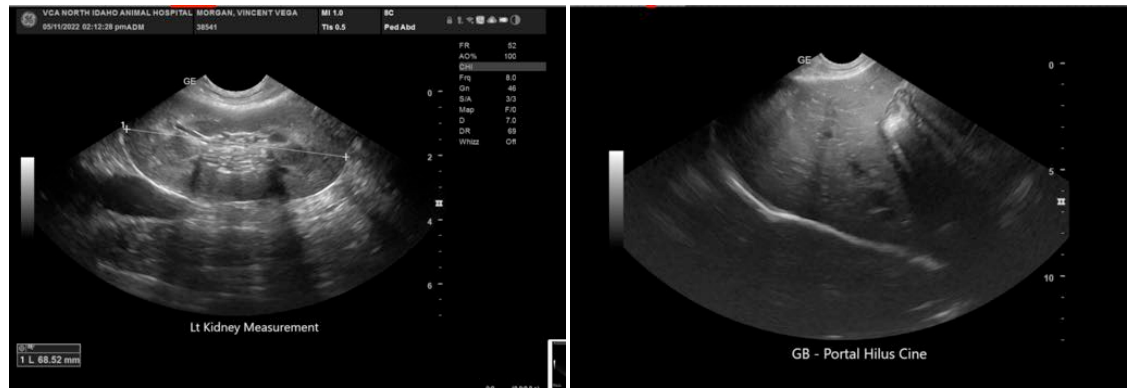
Neutered male

**AGE**

4 years

**WEIGHT**

30.6 kg



**INTERPRETED BY**

Eric Lindquist, DMV  
DABVP, Cert. IVUSS

**IMAGING PERFORMED BY**

Dr. Stegemoller

**HOSPITAL NAME**

North Idaho AH

**REFERRING VET**

Dr. Stegemoller

**INVOICE**

30341

**DATE**

5/12/22

The information and recommendations provided are based on the images presented by the referring veterinarian/sonographer. No evaluation can be communicated regarding pathology that was not visible in the image/video clips provided.

Thank you for this referral. If the clinical or image interpretation does not parallel your findings or if I can be of any further assistance please contact me.

Eric Lindquist, DMV, DABVP, Cert. IVUSS, CEO of SonoPath.com  
info@SonoPath.com