


PATIENT

Stitch Harrington

SPECIES

Feline

BREED

DSH

SEX

FS

AGE

12

WEIGHT

8.4 lb

PRESENTING CLINICAL SIGNS

History: No heart murmur heard 2019 had low SPO2 due to unknown causes during anesthesia and dental was cancelled. Patient needs a dental. Looking to rule out cardiac disease as cause of low SPO2 during anesthesia.

Abnormal PE/Chem/CBC/UA Results: CBC/CHEM/T4 normal BP normal

ULTRASONOGRAPHIC EXAMINATION OF THE HEART

FELINE CARDIAC PARAMETERS	BODY WEIGHT (kg)	HR (BPM)	IVSd (cm)	LVIDd (cm)	LVWd (cm)	FS (%)	EF (%)
NORMAL PARAMETER	-----	150-240	0.3-0.6	1.0-2.1	0.25-0.6	35-67	80-100
PATIENT		206	0.5	1.1	0.3	47	83
FELINE CARDIAC PARAMETERS	LA/AO (Boon)	LA/AO HEART BASE (Sisson)	LA 2D 4-chamber long axis AS to FW (Sisson) (cm)	LVOT VEL. (m/s)	RVOT VEL. (m/s)	IVRT (m/)	
NORMAL PARAMETER	<1.5	0.88-1.79	0.7-1.7	<1.6	<1.3	40-60	
PATIENT	1.0	1.2	1.36				NM
Adapted from June Boon, Veterinary Echocardiography, 1998							
Sisson D et al. JVIM 1991; 5: 232, Jacobs et al. Am J Vet Res 1985; 46:1705							

INTERPRETED BY

 Eric Lindquist, DMV
 DABVP, Cert. IVUSS

Cardiac Presentation
IMAGING PERFORMED BY
 Gudrun Gunther

HOSPITAL NAME

 New Frontier Animal
 Medical Center

REFERRING VET

Gudrun Gunther

INVOICE

10590ag

DATE

05/12/2022

ULTRASONOGRAPHIC FINDINGS

- Trivial mitral insufficiency-not clinically significant



PATIENT

Stitch Harrington

SPECIES

Feline

BREED

DSH

SEX

FS

AGE

12

WEIGHT

8.4 lb

INTERPRETED BY

Eric Lindquist, DMV
DABVP, Cert. IVUSS

IMAGING PERFORMED BY

Gudrun Gunther

HOSPITAL NAME

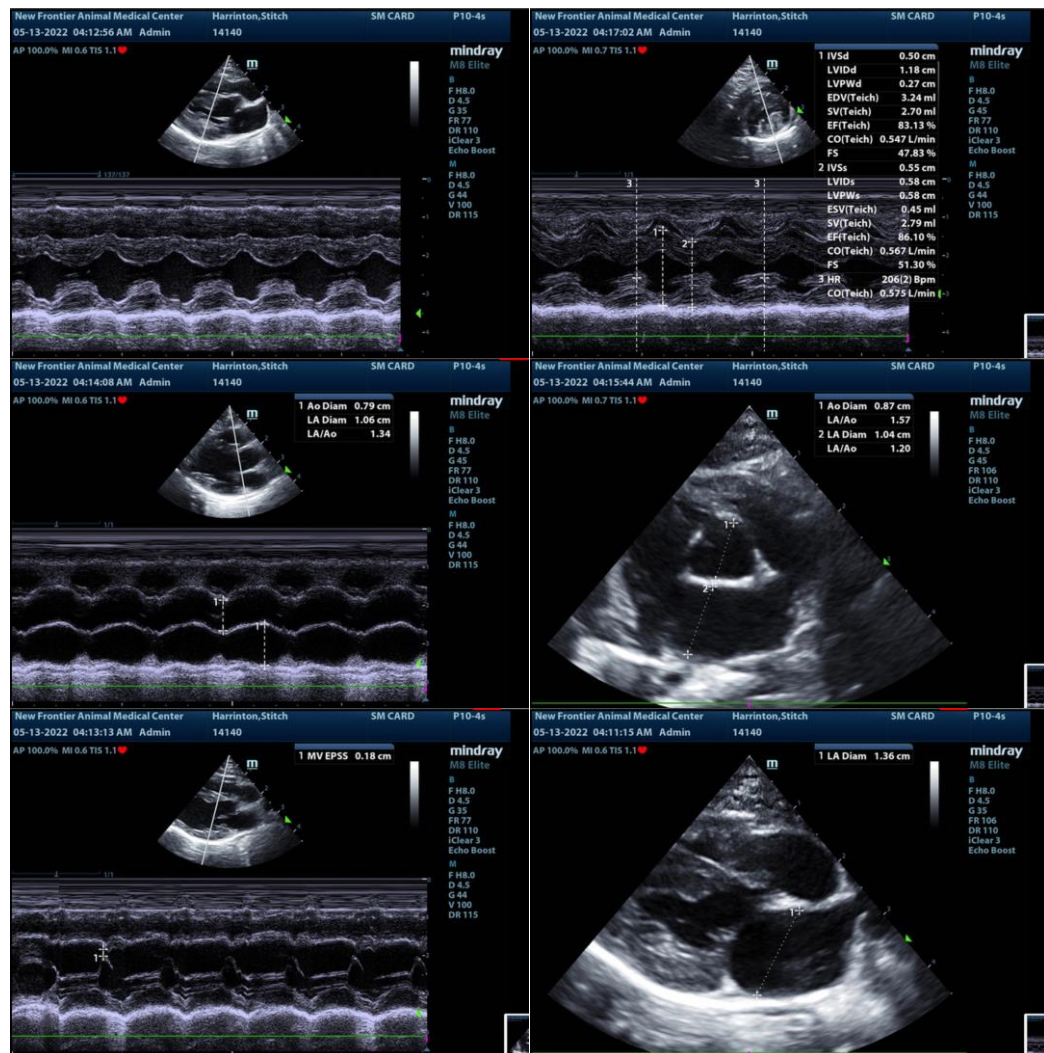
New Frontier Animal
Medical Center

REFERRING VET

Gudrun Gunther

INTERPRETATION OF THE FINDINGS & FURTHER RECOMMENDATIONS

Benign flow murmurs are common in cats. This may be owing to volume shifts, tachycardia, benign (DRVOTO) right ventricular outflow changes, trivial turbulence in any of the valvular apparatuses, or possibly excessive stethoscope pressure against the chest according to a recent study These are physiologically benign and unrelated to specific pathology.



INVOICE

10590ag

DATE

05/12/2022



PATIENT

Stitch Harrington

SPECIES

Feline

BREED

DSH

SEX

FS

AGE

12

WEIGHT

8.4 lb

INTERPRETED BY

Eric Lindquist, DMV
DABVP, Cert. IVUSS

**IMAGING
PERFORMED BY**

Gudrun Gunther

HOSPITAL NAME

New Frontier Animal
Medical Center

REFERRING VET

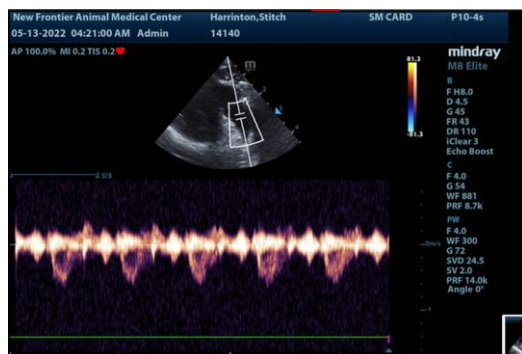
Gudrun Gunther

INVOICE

10590ag

DATE

05/12/2022



The information and recommendations provided are based on the images presented by the referring veterinarian. No evaluation can be communicated regarding pathology that was not visible in the image/video clips provided.

Thank you for this referral. If the clinical or image interpretation does not parallel your findings or if I can be of any further assistance please contact me.

Eric Lindquist, DMV, DABVP, Cert. IVUSS, CEO of SonoPath.com
Eric.Lindquist@SonoPath.com