

PATIENT PRESENTING CLINICAL SIGNS

Pele Gorrell
History: Severe diarrhea/hematochezia. Pu/Pd. Lethargy - severe. Anorexia. BW - NSF's/snap cPL - Neg. Cortisol. Evaluate for Gastroenteritis, pancreatitis, Neoplasia. Labs + Radiographs attached.
Abnormal PE/Chem/CBC/UA Results: LIPASE 424, RADS wnl

SPECIES ULTRASONOGRAPHIC EXAMINATION OF THE ABDOMEN

Canine

BREED Urinary System

Potuguese Water Dog

The urinary bladder, trigone, and pelvic urethra presented normal thicknesses and normal tone. The ureters were not visible which is normal. No uroliths or sediment were visualized and anechoic urine was present. No evidence of inflammatory or neoplastic changes were noted. Ureteral papillae were normal.

SEX

MN

The kidneys revealed normal size and structure, corticomedullary definition and ratio for this age. The cortices presented largely uniform texture with normal echogenic relationship to liver and spleen. Medullary structure differed distinctly from the cortex and no evidence of pelvic dilation was present. The capsules were acceptably uniform without significant irregularities. The left kidney measured 6.06 cm in length. The right kidney measured 6.6 cm in length.

AGE

9 yr

No overt pathology in the area of the residual prostate, measuring 1.27 cm.

WEIGHT

42.6 lb

Adrenal Glands

Both adrenal glands were visualized and recognized as having normal shape, size, position and echogenicity for this breed. The phrenic vasculature, glandular echogenicity and detail were unremarkable. Capsule, cortex, and medullary definition were normal for this age patient. The left adrenal gland measured 2.33 cm in length by 0.76 cm caudal pole width by 0.49 cm cranial pole width. The right adrenal gland measured 2.28 cm in length by 0.83 cm caudal pole width by 0.7 cm cranial pole width.

INTERPRETED BY

Eric Lindquist, DMV DABVP, Cert. IVUSS

Spleen

The spleen presented a smooth homogeneous parenchyma hyperechoic to liver and renal cortical parenchyma. The capsule was smooth without noticeable expansion or deviation from within the spleen or adjacent pathology. The splenic vasculature demonstrated normal volume without signs of congestion or thrombosis. No sonographic evidence of acute or chronic inflammatory, neoplastic, or infarctual changes were noted.

IMAGING PERFORMED BY

Denise Bruno, LVT, RDMS

HOSPITAL NAME

Brooklyn Heights Animal Hospital

Liver

The liver images submitted revealed subjectively normal liver size, contour, and structure. Parenchymal echogenicity was naturally coarse and hypoechoic to the spleen. Vascular and biliary tracts were of normal volume with no evidence of congestion. The gallbladder presented acceptably thin walls with primarily anechoic content. The cystic and common bile ducts were normal. No pathological hepatic lymphadenopathy was evident. No overt structural evidence of inflammatory, infiltrative or regenerative pathology was evident.

REFERRING VET

Dr. Thomson

INVOICE

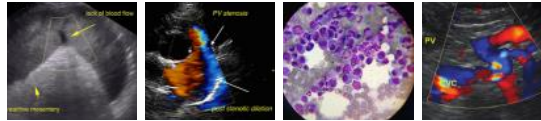
10587ag

Gastrointestinal

Examination of the gastrointestinal tract revealed a stomach and intestine free of stasis, of normal wall thickness, acceptable curvilinear mural detail, and peristaltic activity. Small and large intestine demonstrated normal luminal chyme and stool consistency respectively. No obstructive or overt infiltrative disease was noted. No associated abnormal lymphatic activity was noted.

DATE

05/12/2022



PATIENT

Pele Gorrell

SPECIES

Canine

BREED

Potuguese Water
Dog

SEX

MN

AGE

9 yr

WEIGHT

42.6 lb

INTERPRETED BY

Eric Lindquist, DMV
DABVP, Cert. IVUSS

IMAGING PERFORMED BY

Denise Bruno, LVT,
RDMS

HOSPITAL NAME

Brooklyn Heights
Animal Hospital

REFERRING VET

Dr. Thomson

INVOICE

10587ag

DATE

05/12/2022

Pancreas

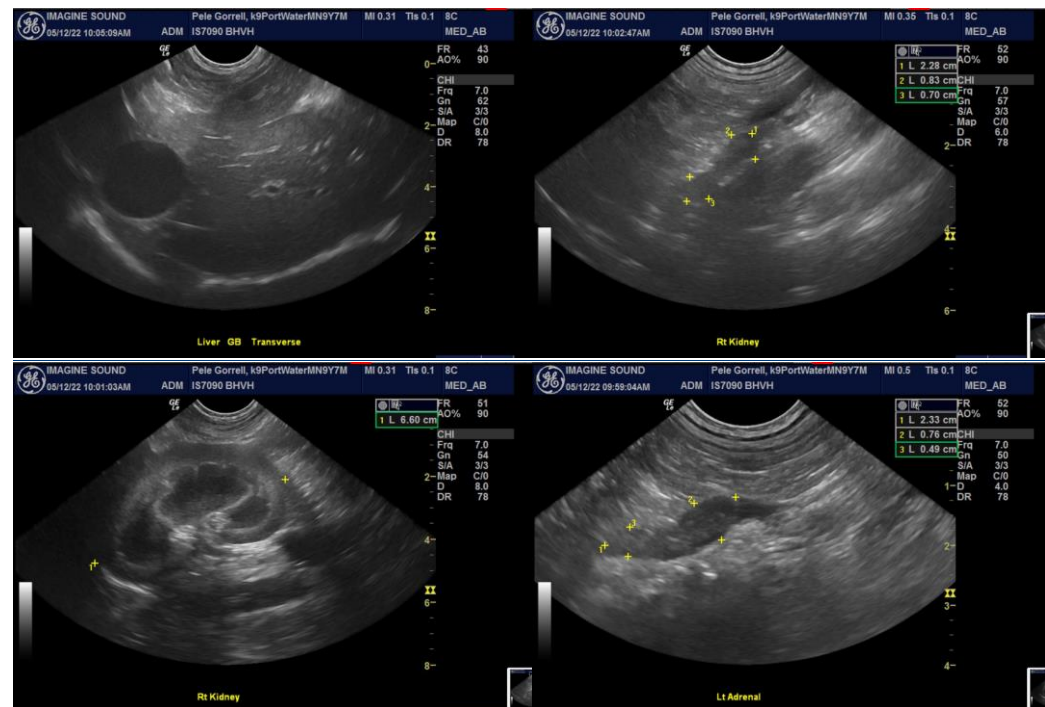
The base and limbs of the pancreas were observed to be largely isoechoic to surrounding omental fat. Pancreatic duct and capsular contour were acceptably normal and parenchyma respected normal curvilinear patterns. No overt evidence of active inflammatory or neoplastic disease was noted.

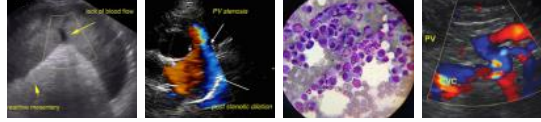
ULTRASONOGRAPHIC FINDINGS

- Structurally unremarkable abdomen with no evidence of pathology

INTERPRETATION OF THE FINDINGS & FURTHER RECOMMENDATIONS

Dietary indiscretion, food intolerance/indiscretion, structurally insignificant inflammatory bowel or occult parasitism and occult Addison's are all potentials.





PATIENT

Pele Gorrell

SPECIES

Canine

BREED

Potuguese Water
Dog

SEX

MN

AGE

9 yr

WEIGHT

42.6 lb

INTERPRETED BY

Eric Lindquist, DMV
DABVP, Cert. IVUSS

**IMAGING
PERFORMED BY**

Denise Bruno, LVT,
RDMS

HOSPITAL NAME

Brooklyn Heights
Animal Hospital

REFERRING VET

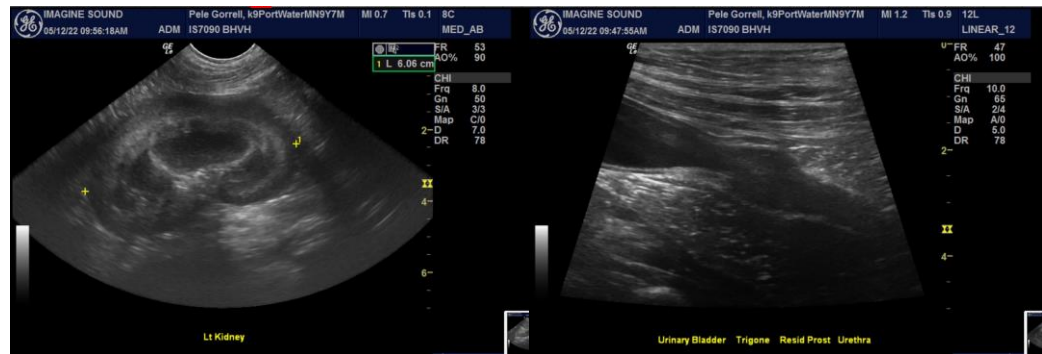
Dr. Thomson

INVOICE

10587ag

DATE

05/12/2022



The information and recommendations provided are based on the images presented by the referring veterinarian/sonographer. No evaluation can be communicated regarding pathology that was not visible in the image/video clips provided.

Thank you for this referral. If the clinical or image interpretation does not parallel your findings or if I can be of any further assistance please contact me.

Eric Lindquist, DMV, DABVP, Cert. IVUSS, CEO of SonoPath.com
Eric.Lindquist@SonoPath.com