IMAGING PERFORMED BY

IntraPet.com

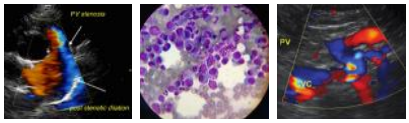

SonoPath
Clinical Sonography & Telecytology
EDUCATIONAL TELECONSULTATION SERVICES™
1-800-838-4268 info@sonopath.com SonoPath.com

DATE
5/12/22

PATIENT
Mitten Catron

SPECIES
Feline

BREED
DSH

SEX
Neutered Male

AGE
1/8/2015

WEIGHT
9.44 Pounds

INTERPRETED BY
Eric Lindquist, DMV
DABVP, Cert. IVUSS

HOSPITAL NAME
Banfield Towson

REFERRING VET
Dr. Mike

INVOICE
15134

PRESENTING CLINICAL SIGNS

History: Mitten presents today for vomiting on/off past wo year, worse past 1-2 m. Initially had been 1-2 times a month and increased slowly O states now P vomits almost every time he eats. P is E/D Sheba and dry food is always out (any protein except seafood) and a little portion of canned food at night. No C/S noted, past m stool increased odor and soft diarrhea. P was last normal several years ago. Mild hiatal hernia noted on rads 11/2021

Current Medications: None listed.
Lab Results: cbc/chem - increased chol (unfasted sample). u/a - sg > 1.040; sed blood present, suspect secondary to cystocentesis
Radiographs: mild hiatal hernia noted on rads 11/2021.
Date of Previous IntraPet Ultrasound: No previous.
Sedation: Not required to complete full diagnostic ultrasound.
Stat Report: Not requested.
Imaging Performed By: Rachel Brilhart, RDMS.

ULTRASONOGRAPHIC EXAMINATION OF THE ABDOMEN

Urinary System

The **urinary bladder**, trigone, and pelvic urethra presented normal thicknesses and normal tone. The ureters were not visible which is normal. No uroliths or sediment were visualized and anechoic urine was present. No evidence of inflammatory or neoplastic changes were noted. Ureteral papillae were normal.

The **kidneys** revealed normal size and structure, corticomedullary definition and ratio for this age. The cortices presented largely uniform texture with normal echogenic relationship to liver and spleen. Medullary structure differed distinctly from the cortex and no evidence of pelvic dilation was present. The capsules were acceptably uniform without significant irregularities. The left kidney measured 3.58 cm. The right kidney measured 3.73 cm.

Adrenal Glands

Both **adrenal glands** were visualized and recognized as having normal shape, size, position and echogenicity for this breed. The phrenic vasculature, glandular echogenicity and detail were unremarkable. Capsule, cortex, and medullary definition were normal for this age patient. The left adrenal gland measured 0.32 cm. The right adrenal gland measured 0.52 cm.

Spleen

The **spleen** presented a smooth homogeneous parenchyma hyperechoic to liver and renal cortical parenchyma. The capsule was smooth without noticeable expansion or deviation from within the spleen or adjacent pathology. The splenic vasculature demonstrated normal volume without signs of congestion or thrombosis. No sonographic evidence of acute or chronic inflammatory, neoplastic, or infarctual changes were noted.

Liver

The **liver** images submitted revealed subjectively normal liver size, contour, and structure. Parenchymal echogenicity was naturally coarse and hypoechoic to the spleen. Vascular and biliary tracts were of normal volume with no evidence of congestion. The gallbladder presented acceptably thin walls with primarily anechoic content. The cystic and common bile ducts were normal. No pathological hepatic

lymphadenopathy was evident. No overt structural evidence of inflammatory, infiltrative or regenerative pathology was evident.

Gastrointestinal

A minor amount of chyme was noted in the **stomach**. Transit of chyme in the small intestine was normal.

Pancreas

The base and limbs of the **pancreas** were observed to be largely isoechoic to surrounding omental fat. Pancreatic duct and capsular contour were acceptably normal and parenchyma respected normal curvilinear patterns. No overt evidence of active inflammatory or neoplastic disease was noted.

ULTRASONOGRAPHIC FINDINGS

- Structurally insignificant inflammatory bowel, occult parasitism all possible.

INTERPRETATION OF THE FINDINGS & FURTHER RECOMMENDATIONS

A change to hydrolyzed diet recommended. A clinical trial of Zithromax/Metronidazole over a 7-day period to cover for infectious agents could also be considered. The upper GI appears to be in proper position.

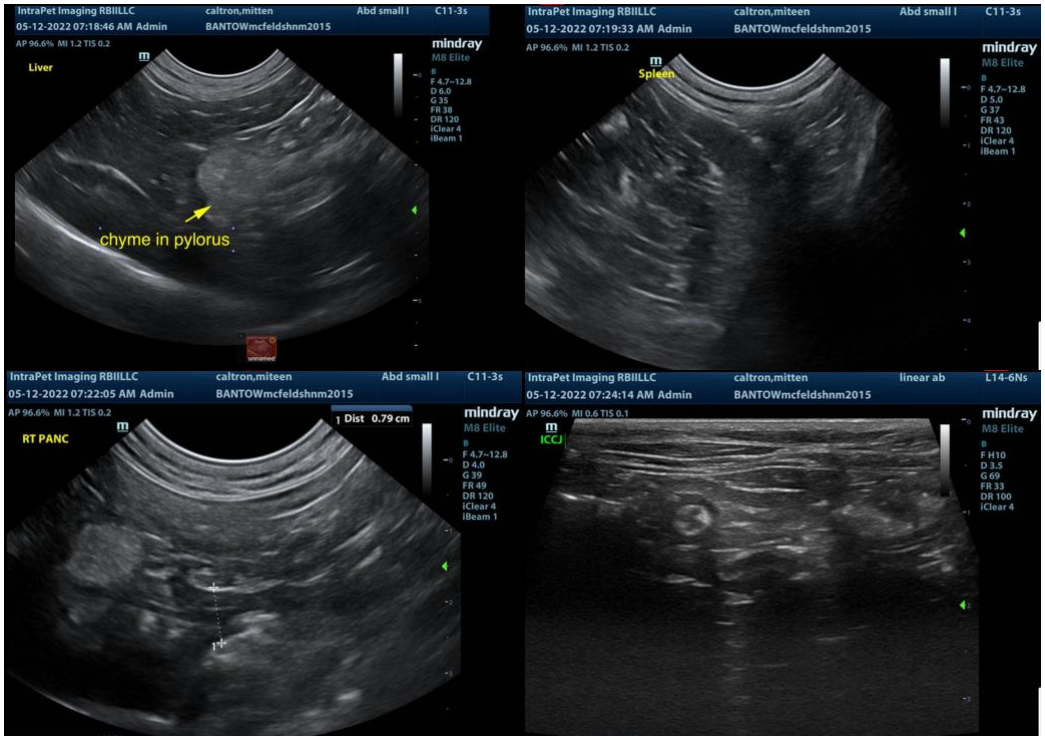

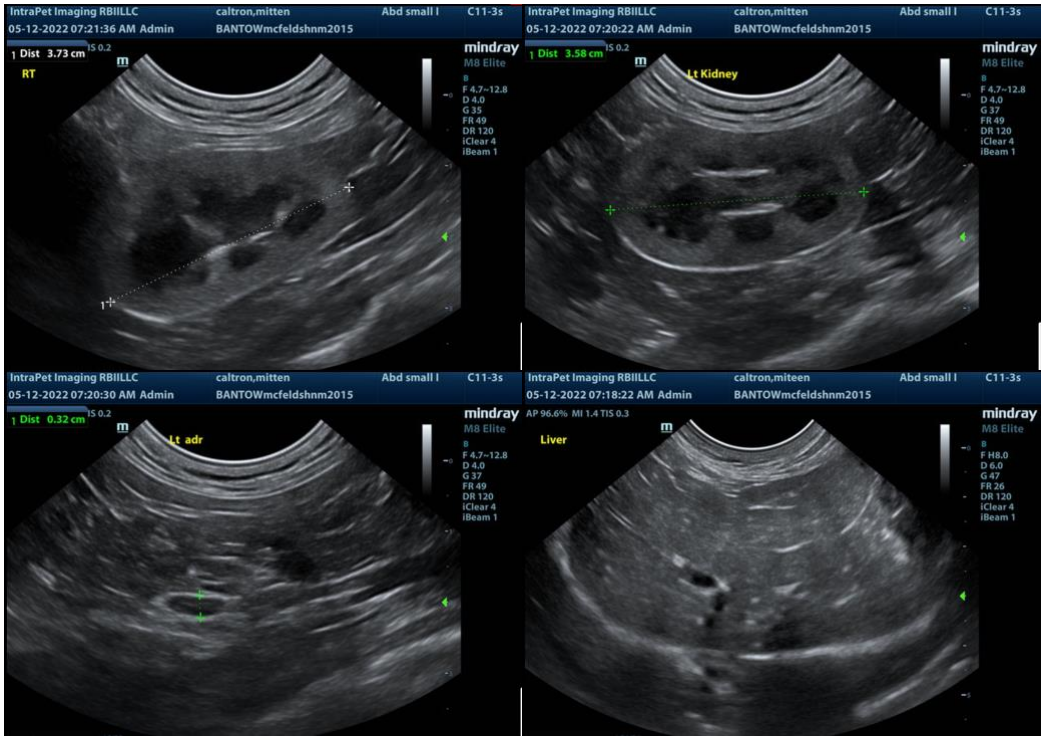

The information and recommendations provided are based on the images presented by the referring veterinarian. No evaluation can be communicated regarding pathology that was not visible in the image/video clips provided.

Thank you for this referral. If the clinical or image interpretation does not parallel your findings or if I can be of any further assistance please contact me.

Eric Lindquist, DMV, DABVP, Cert. IVUSS, CEO of SonoPath.com
Eric.Lindquist@SonoPath.com