

**DATE**

5/12/22

PRESENTING CLINICAL SIGNS

History: Weight loss, pale MM, organomegaly, lethargy, diarrhea and anorexia.

PATIENT

Maggie Fratantuono

Current Medications: Metronidazole.

Lab Results: See attached.

Radiographs: Enlarged spleen or liver, loss of detail.

Date of Previous IntraPet Ultrasound: No previous.

SPECIES

Canine

Sedation: Not required to complete full diagnostic ultrasound.

Stat Report: Not requested.

Imaging Performed By: Rachel Brillhart, RDMS.

BREED

Labrador Retriever

ULTRASONOGRAPHIC EXAMINATION OF THE ABDOMEN**Urinary System****SEX**

Spayed Female

The **urinary bladder**, trigone, and pelvic urethra presented normal thicknesses and normal tone. The ureters were not visible which is normal. No uroliths or sediment were visualized and anechoic urine was present. No evidence of inflammatory or neoplastic changes were noted. Ureteral papillae were normal.

AGE

11/24/12

The **kidneys** revealed largely normal size and structure, corticomedullary definition and ratio (cortex 1/3 of medulla) were essentially maintained with some mild age-related loss of curvilinear patterns regarding the capsule and C/M junction. The cortices presented largely uniform texture with some increased echogenicity expected for his age patient. Medullary structure differed distinctly from that of the cortex and no evidence of pelvic dilation was present. The left kidney measured 7.54 cm. The right kidney measured 7.37 cm.

WEIGHT

65 Pounds

Adrenal Glands**INTERPRETED BY**Eric Lindquist, DMV
DABVP, Cert. IVUSS

Both **adrenal glands** were visualized and recognized as having normal shape, size, position and echogenicity for this breed. The phrenic vasculature, glandular echogenicity and detail were unremarkable. Capsule, cortex, and medullary definition were normal for this age patient. The left adrenal gland measured 2.36 cm x 0.7 cm at the caudal pole and 0.62 cm at the cranial pole. The right adrenal gland measured 2.55 cm x 0.79 cm at the caudal pole and 0.83 cm at the cranial pole.

HOSPITAL NAME

Bayside AMC

Spleen

The **spleen** revealed a 7.0 cm mixed hypoechoic undifferentiated mass. The spleen itself presented generalized enlargement and infiltrative pattern. Regional free fluid was noted, consistent with hemorrhage or paraneoplastic effusion. However, the effusion was minor and not justifiable to the degree of anemia. Multifocal coalescing target nodules were noted throughout the spleen as well. Enhanced mesentery noted.

REFERRING VET

Dr. Bray

Liver

The **liver** was coarse in architecture with heterogeneous coalescing parenchymal changes. The gallbladder and common bile duct were unremarkable. Slight free fluid was noted between the liver lobes.

INVOICE

15137

Gastrointestinal

Examination of the **gastrointestinal tract** revealed a stomach and intestine free of stasis, of normal wall thickness, acceptable curvilinear mural detail, and peristaltic activity. Small and large intestine demonstrated normal luminal chyme and stool consistency respectively. No obstructive or overt infiltrative disease was noted. No associated abnormal lymphatic activity was noted.

Pancreas

The base and limbs of the **pancreas** were observed to be largely isoechoic to surrounding omental fat. Pancreatic duct and capsular contour were acceptably normal and parenchyma respected normal curvilinear patterns. No overt evidence of active inflammatory or neoplastic disease was noted.

Other

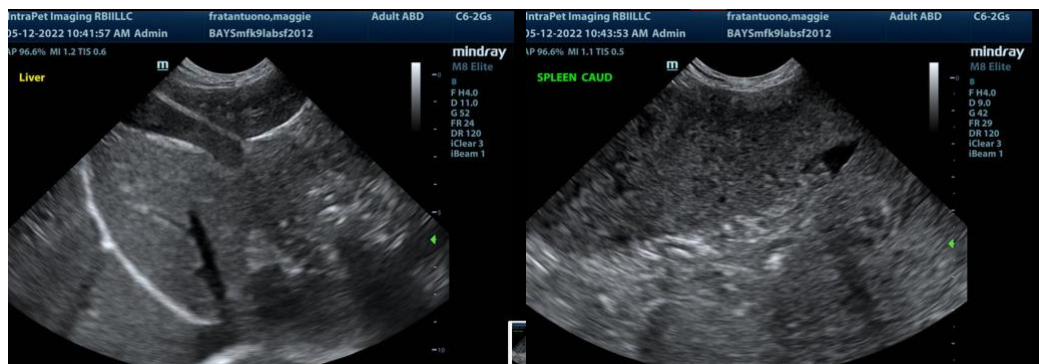
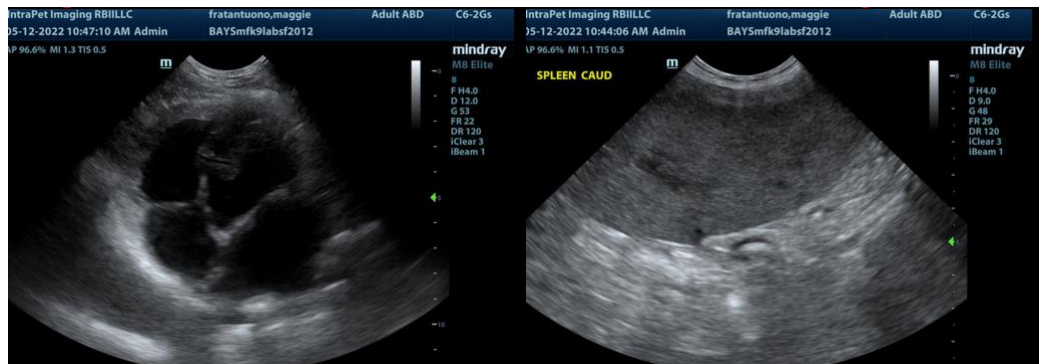
A rapid view of the heart revealed no evident pathology in the right auricle or pericardium.

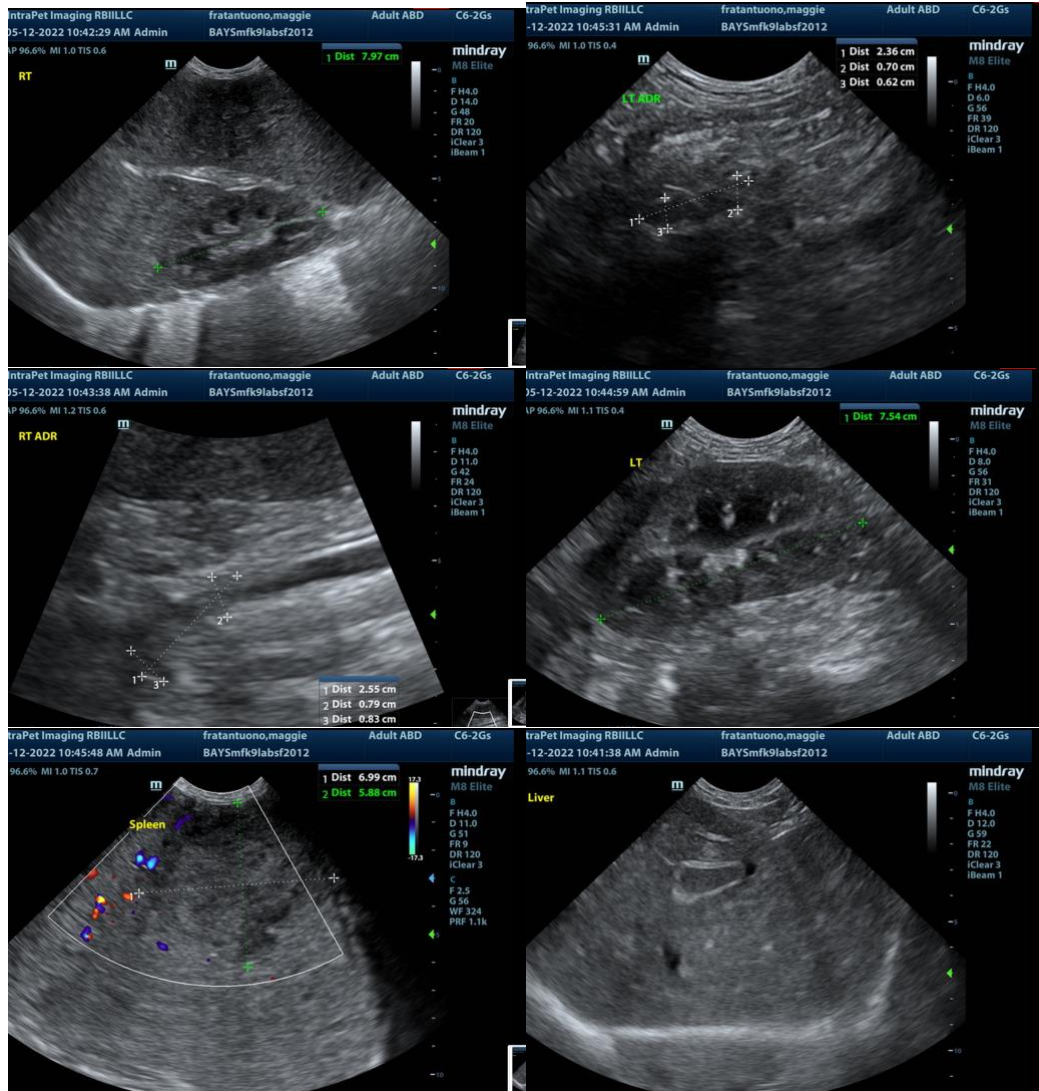
ULTRASONOGRAPHIC FINDINGS

- Splenic infiltrative pattern with masses. Possible hepatic involvement.
- Age-related renal and adrenal changes
- Heterogeneous liver

INTERPRETATION OF THE FINDINGS & FURTHER RECOMMENDATIONS

I recommend FNA of the spleen and liver, CBC path review and bone marrow aspirate in this patient for staging purposes. Splenectomy could be considered; however, I do not believe that the degree of anemia is owing to simple blood loss in the abdomen. Guarded to poor prognosis. Round cell neoplasia versus hemangiosarcoma (less likely).





The information and recommendations provided are based on the images presented by the referring veterinarian. No evaluation can be communicated regarding pathology that was not visible in the image/video clips provided.

Thank you for this referral. If the clinical or image interpretation does not parallel your findings or if I can be of any further assistance please contact me.

Eric Lindquist, DMV, DABVP, Cert. IVUSS, CEO of SonoPath.com
 Eric.Lindquist@SonoPath.com