



PATIENT

Finch Haley

SPECIES

Canine

BREED

Border Collie

SEX

Male

AGE

12 years

WEIGHT

70 lbs

PRESENTING CLINICAL SIGNS

History: Recent episodes of lethargy and decreased mentation.
Abnormal PE/Chem/CBC/UA Results: Non regenerative anemia, well controlled diabetic

ULTRASONOGRAPHIC EXAMINATION OF THE ABDOMEN

Urinary System

The **bladder** in this patient was mildly thickened with slight echogenic mural changes. No calculi or masses were noted. Slight micropolypoid changes were noted. This is a frequent finding in older animals and may be linked to a history of chronic urinary tract infection or active urinary tract infection. Urinalysis would be recommended with culture if any evidence of inflammatory sediment is present. The region of the trigone and visible pelvic urethra were normal.

The **kidneys** revealed normal size and structure, corticomedullary definition and ratio for this age. The cortices presented largely uniform texture with normal echogenic relationship to liver and spleen. Medullary structure differed distinctly from the cortex and no evidence of pelvic dilation was present. The capsules were acceptably uniform without significant irregularities. The left kidney measured 6.3 cm. The right kidney measured

INTERPRETED BY

Eric Lindquist, DMV
DABVP, Cert. IVUSS

Adrenal Glands

Both **adrenal glands** were visualized and recognized as having normal shape, size, position and echogenicity for this breed. The phrenic vasculature, glandular echogenicity and detail were unremarkable. Capsule, cortex, and medullary definition were normal for this age patient. The left adrenal gland measured 0.5 cm. The right adrenal gland measured 0.6 cm and was visualized obliquely.

IMAGING PERFORMED BY

Dr. Keller

Spleen

The **spleen** presented a smooth homogeneous parenchyma hyperechoic to liver and renal cortical parenchyma. The capsule was smooth without noticeable expansion or deviation from within the spleen or adjacent pathology. The splenic vasculature demonstrated normal volume without signs of congestion or thrombosis. No sonographic evidence of acute or chronic inflammatory, neoplastic, or infarctual changes was noted.

HOSPITAL NAME

Birch Bark VC

REFERRING VET

Dr. Keller

INVOICE

75321

DATE

5/11/26

Liver

The **liver** was uniformly swollen with minor, excessive gallbladder debris and over distension with dependent and suspended bile without evidence of overt mucocele formation. However, excessive sludge was present. Hyperechoic lipid plaques were noted measuring up to 1.7 cm. The liver presented coarse architecture with mildly increased portal markings and subtle, mixed echogenic changes. This is consistent with vacuolar hepatopathy and some level of remodeling and history of inflammatory component. There was no overt suspicion of neoplasia.



PATIENT

Gastrointestinal

Finch Haley

Examination of the **gastrointestinal tract** revealed a stomach and intestine free of stasis, of normal wall thickness, acceptable curvilinear mural detail, and peristaltic activity. Small and large intestine demonstrated normal luminal chyme and stool consistency respectively. No obstructive or overt infiltrative disease was noted. No associated abnormal lymphatic activity was noted.

SPECIES

Canine

BREED

Pancreas

Border Collie

The base and limbs of the **pancreas** were observed to be largely isoechoic to surrounding omental fat. Pancreatic duct and capsular contour were acceptably normal and parenchyma respected normal curvilinear patterns. No overt evidence of active inflammatory or neoplastic disease was noted.

SEX

Male

AGE

Free Abdomen

12 years

A large amount of abdominal fat was noted in this patient.

WEIGHT

70 lbs

ULTRASONOGRAPHIC FINDINGS

INTERPRETED BY

Benign abdomen, no evidence of disease related to the anemia.

Eric Lindquist, DMV
DABVP, Cert. IVUSS

INTERPRETATION OF THE FINDINGS & FURTHER RECOMMENDATIONS

IMAGING PERFORMED BY

Screening for underlying Addison's is indicated. The adrenal glands measure normally, yet subjectively appear slightly small. Other causes of the lethargy such as orthopedic pain, CNS or thoracic disease should be considered. GI protectant protocol can be considered in case of GI blood loss, yet there was no gross evidence of GI disease noted. CBC path review +/- bone aspirate may be appropriate.

Dr. Keller

HOSPITAL NAME

Birch Bark VC

REFERRING VET

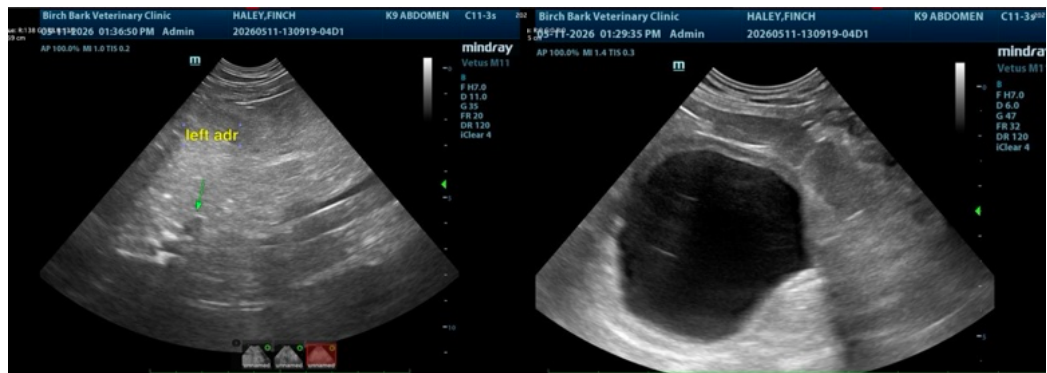
Dr. Keller

INVOICE

75321

DATE

5/11/26





PATIENT

Finch Haley

SPECIES

Canine

BREED

Border Collie

SEX

Male

AGE

12 years

WEIGHT

70 lbs

INTERPRETED BY

Eric Lindquist, DMV
DABVP, Cert. IVUSS

IMAGING PERFORMED BY

Dr. Keller

HOSPITAL NAME

Birch Bark VC

REFERRING VET

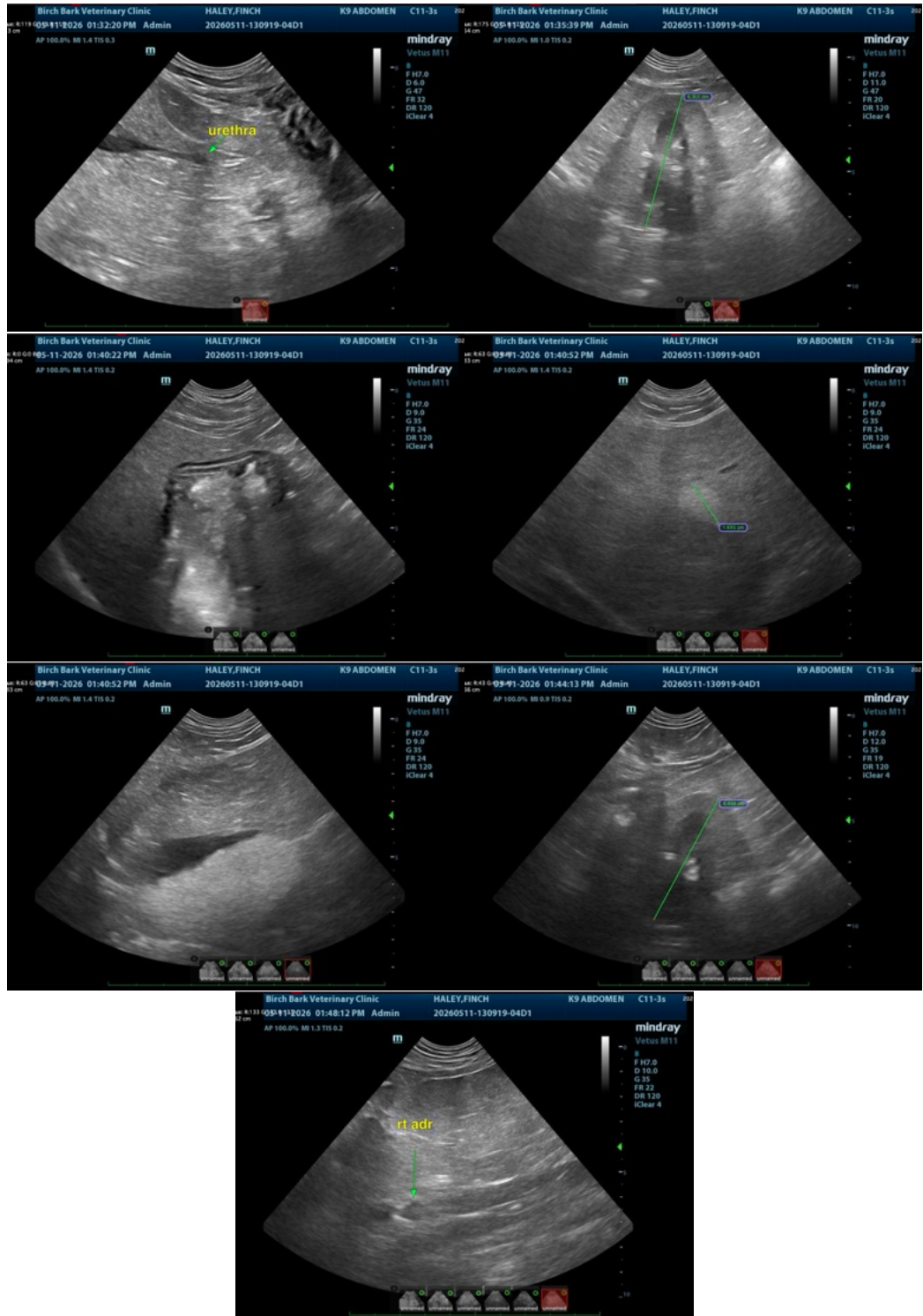
Dr. Keller

INVOICE

75321

DATE

5/11/26



The information and recommendations provided are based on the images presented by the referring veterinarian/sonographer. No evaluation can be communicated regarding pathology



PATIENT

Finch Haley

SPECIES

Canine

BREED

Border Collie

SEX

Male

AGE

12 years

WEIGHT

70 lbs

INTERPRETED BY

Eric Lindquist, DMV
DABVP, Cert. IVUSS

IMAGING PERFORMED BY

Dr. Keller

HOSPITAL NAME

Birch Bark VC

REFERRING VET

Dr. Keller

INVOICE

75321

DATE

5/11/26

that was not visible in the image/video clips provided.

Thank you for this referral. If the clinical or image interpretation does not parallel your findings or if I can be of any further assistance please contact me.

Eric Lindquist, DMV, DABVP (CFM), Cert. IVUSS, CEO of SonoPath.com

info@SonoPath.com