



**PATIENT**

Eddie Russu

**SPECIES**

Canine

**BREED**

Mixed

**SEX**

Neutered Male

**AGE**

10 Years 6 Months

**WEIGHT**

83 lbs

**INTERPRETED BY**

Eric Lindquist, DMV,  
DABVP(CFM), Cert.  
IVUSS

**IMAGING PERFORMED BY**

Vincent Ravancho CVT

**HOSPITAL NAME**

Marsh Hospital for  
Animals

**REFERRING VET**

Dr. Wilson

**INVOICE**

16069

**DATE**

05/11/26

**PRESENTING CLINICAL SIGNS**

Right Anal Sac Adenocarcinoma

Abnormal PE/Chem/CBC/UA Results: Pending

**ULTRASONOGRAPHIC EXAMINATION OF THE HEART & ABDOMEN**

CANINE CARDIAC PARAMETERS	MR VMAX (m/s)	TR VMAX (m/s)	LA/AO (M-Mode)	LA/AO (Heart Base; Swe)	FS (%)	EF (%)	EPSS (cm)
NORMAL PARAMETER	4.5-5.5	<2.7	1.3	Up to 1.6	28-40	40-100	<0.6
PATIENT	--	--	1.1	--	42	74	NM
CANINE CARDIAC PARAMETERS	HR (BPM)	AV VMAX (m/s)	PV MAX (m/s)	BODY WEIGHT (lbs)	LAD LA MAX 4 Chamber	LVIDd Avg; 2D and m-mode short axis (cm)	LVIDs Avg; 2D and m-mode short axis (cm)
NORMAL PARAMETER	50-100	0.7-1.7	0.7-1.6				
PATIENT	148	2.0	0.95	83	--	3.46	--

**Cardiac Presentation**

The echocardiogram in this patient demonstrated normal **left atrial** size based on 3 separate methods of LA evaluation. Trivial mitral valve insufficiency was present. The **left ventricle** presented normal thicknesses with linear contour and was not dilated nor restricted. The **myocardium** presented normal echogenicity without subjective evidence of significant fibrotic or ischemic disease. **Contractility** of the ventricular walls was adequate and in normal range for this patient evidenced by the fractional shortening measurement and subjective evaluation of the different regions of the myocardium. The **left ventricular outflow** tract demonstrated normal laminar flow and subjective structural integrity. The **right atrium** and auricle revealed normal size, structure and content. No evidence of masses was noted. **Tricuspid** valvular assessment demonstrated adequate linear morphology and kinesis. The **right ventricle** was of normal size (1/3 diameter of LV), chordae structure, myocardial echogenicity and thickness. **Pulmonary outflow** tract assessment revealed normal valve structure, laminar flow, and diameter (approx.1:1 pa/ao ratio). No visible **pericardial** or free pleura fluid was noted. The cranial **mediastinum and pericardial and extra-cardiac regions** were free of masses in the visible window.

**Urinary System**

The **urinary bladder**, trigone, and pelvic urethra to a depth of 1.0 cm presented normal thicknesses and normal tone. The ureters were not visible which is normal. No uroliths or sediment were visualized, and anechoic urine was present. No evidence of inflammatory or neoplastic changes were noted. Ureteral papillae were normal.



**PATIENT**

The **iliac trifurcation** was unremarkable.

Eddie Russu

The **kidneys** revealed largely normal size and structure, corticomedullary definition and ratio (cortex 1/3 of medulla) were essentially maintained with some minor age-related loss of curvilinear patterns regarding the capsule and C/M junction. The cortices presented largely uniform texture with some increased echogenicity expected for his age patient. Medullary structure differed distinctly from that of the cortex and no evidence of pelvic dilation was present. The left kidney measured 6.9 cm in length. The right kidney measured 6.9 cm in length.

**SPECIES**

Canine

**BREED**

Mixed

**SEX**

Neutered Male

**AGE**

10 Years 6 Months

**WEIGHT**

83 lbs

**INTERPRETED BY**

Eric Lindquist, DMV,  
DABVP(CFM), Cert.  
IVUSS

**IMAGING PERFORMED BY**

Vincent Ravancho CVT

**HOSPITAL NAME**

Marsh Hospital for  
Animals

**REFERRING VET**

Dr. Wilson

**INVOICE**

16069

**DATE**

05/11/26

**Adrenal Glands**

Both **adrenal glands** were visualized and recognized as having normal shape, size, position and echogenicity for this breed. The phrenic vasculature, glandular echogenicity and detail were unremarkable. Capsule, cortex, and medullary definition were normal for this age patient. The left adrenal gland measured 2.0 cm x 0.79 cm width at the caudal pole and 0.68 cm width at the cranial pole. The right adrenal gland measured 2.07 cm 1.1 cm width at the cranial pole and 0.78 cm width at the caudal pole.

**Spleen**

The **spleen** presented a smooth homogeneous parenchyma hyperechoic to liver and renal cortical parenchyma. The capsule was smooth without noticeable expansion or deviation from within the spleen or adjacent pathology. The splenic vasculature demonstrated normal volume without signs of congestion or thrombosis. No sonographic evidence of acute or chronic inflammatory, neoplastic, or infarctual changes were noted.

**Liver**

The **liver** images from right and left intercostal as well as subcostal views revealed subjectively normal liver size, contour, and structure. Some mild age-related parenchymal remodeling was noted but likely not clinically significant at this time. Vascular and biliary tracts were of normal volume and no evidence of congestion was noted. The gallbladder presented some dependent debris with essentially normal contour. The cystic and common bile ducts were normal. No overt evidence of active inflammatory, infiltrative or regenerative pathology was noted but should be paired with current or past LE elevations regarding any clinical significance to this presentation. The hepatic lymph nodes were unremarkable.

**Gastrointestinal**

Examination of the **gastrointestinal tract** revealed a stomach and intestine free of stasis, of normal wall thickness, acceptable curvilinear mural detail, and peristaltic activity. Small and large intestine demonstrated normal luminal chyme and stool consistency respectively. No obstructive or overt infiltrative disease was noted. No associated abnormal lymphatic activity was noted.

**Pancreas**

The base and limbs of the **pancreas** were observed to be largely isoechoic to surrounding omental fat. Pancreatic duct and capsular contour were acceptably normal and parenchyma respected normal curvilinear patterns. No overt evidence of active inflammatory or neoplastic disease was noted.

**ULTRASONOGRAPHIC FINDINGS**



**PATIENT**

Eddie Russu

- Normal echocardiogram with trivial valvular insufficiency stage B1 valvular disease.
- Age-related renal/hepatic changes.

**SPECIES**

Canine

**INTERPRETATION OF THE FINDINGS & FURTHER RECOMMENDATIONS**

Structurally unremarkable abdomen with no evidence of pathology (primary nor metastatic).

**BREED**

Mixed

**SEX**

Neutered Male

**AGE**

10 Years 6 Months

**WEIGHT**

83 lbs

**INTERPRETED BY**

Eric Lindquist, DMV,  
 DABVP(CFM), Cert.  
 IVUSS

**IMAGING PERFORMED BY**

Vincent Ravancho CVT

**HOSPITAL NAME**

Marsh Hospital for  
 Animals

**REFERRING VET**

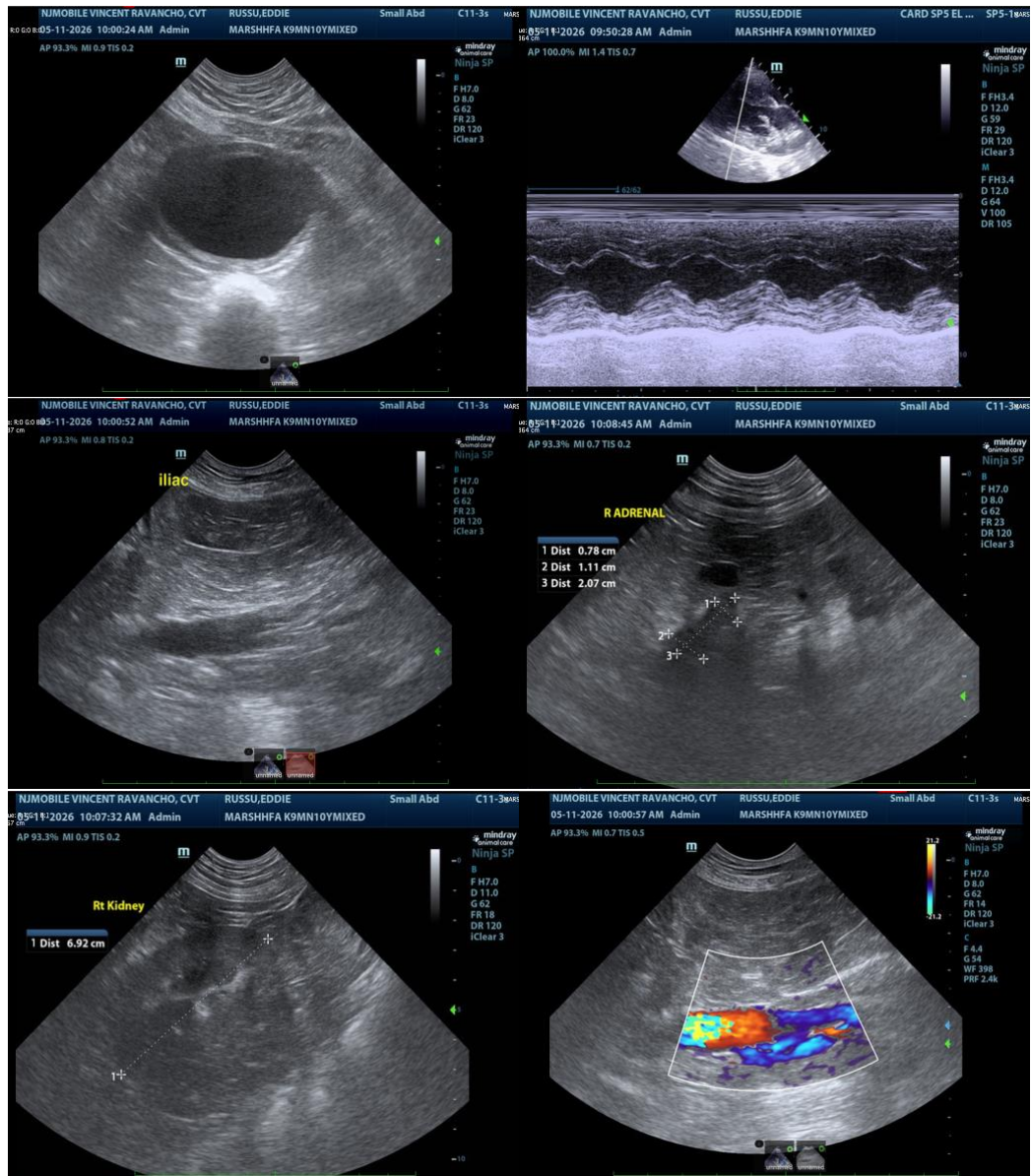
Dr. Wilson

**INVOICE**

16069

**DATE**

05/11/26





**PATIENT**

Eddie Russo

**SPECIES**

Canine

**BREED**

Mixed

**SEX**

Neutered Male

**AGE**

10 Years 6 Months

**WEIGHT**

83 lbs

**INTERPRETED BY**

Eric Lindquist, DMV,  
 DABVP(CFM), Cert.  
 IVUSS

**IMAGING PERFORMED BY**

Vincent Ravancho CVT

**HOSPITAL NAME**

Marsh Hospital for  
 Animals

**REFERRING VET**

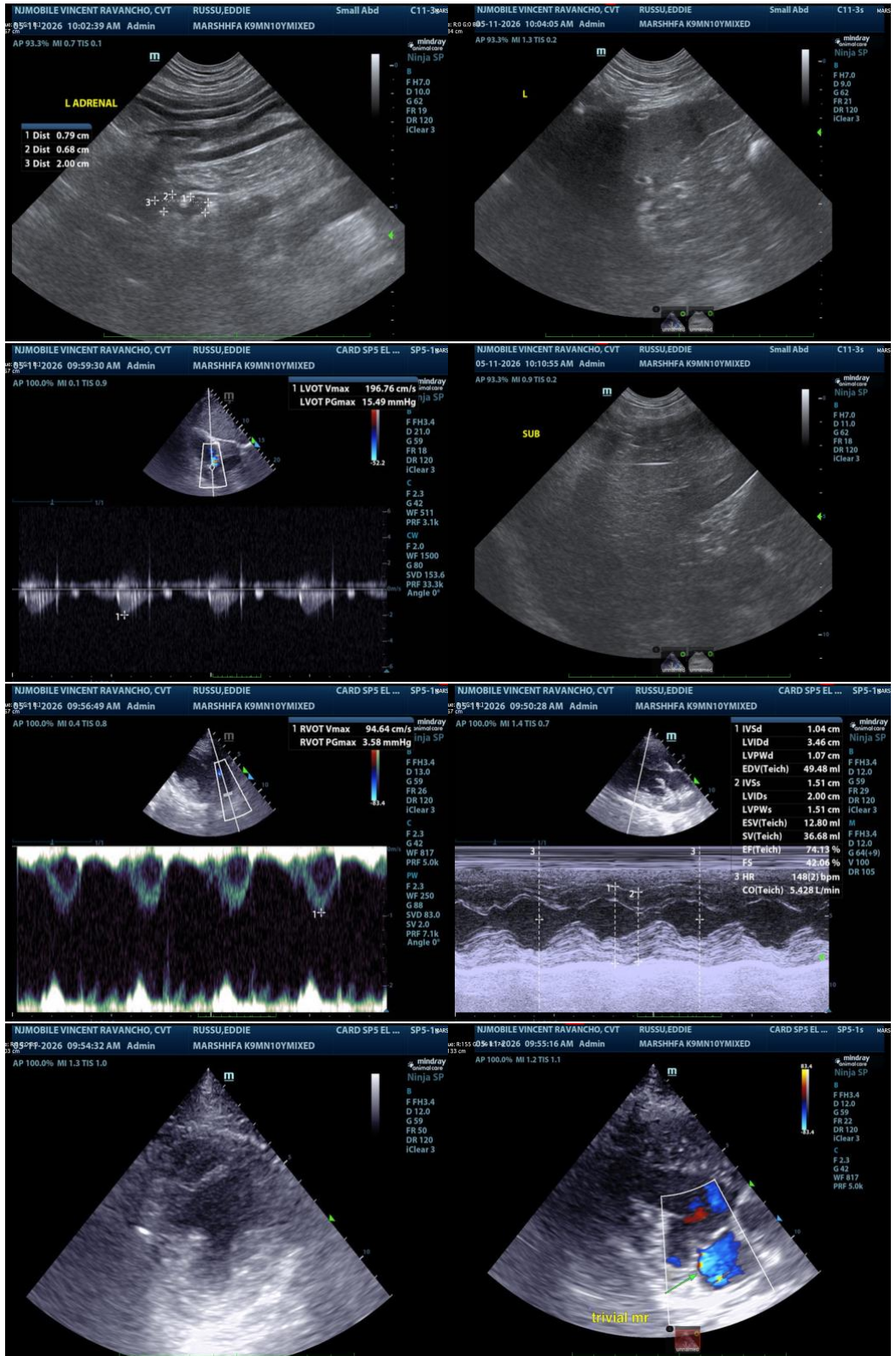
Dr. Wilson

**INVOICE**

16069

**DATE**

05/11/26





**PATIENT**

Eddie Russu

The information and recommendations provided are based on the images presented by the referring veterinarian/sonographer. No evaluation can be communicated regarding pathology that was not visible in the image/video clips provided.

**SPECIES**

Canine

Thank you for this referral. If the clinical or image interpretation does not parallel your findings or if I can be of any further assistance, please contact me.

**BREED**

Mixed

**Eric Lindquist, DMV, DABVP(CFM), Cert. IVUSS,**

CEO, Owner, Founder -- SonoPath.com

[info@SonoPath.com](mailto:info@SonoPath.com)

**SEX**

Neutered Male

**AGE**

10 Years 6 Months

**WEIGHT**

83 lbs

**INTERPRETED BY**

Eric Lindquist, DMV,  
DABVP(CFM), Cert.  
IVUSS

**IMAGING  
PERFORMED BY**

Vincent Ravancho CVT

**HOSPITAL NAME**

Marsh Hospital for  
Animals

**REFERRING VET**

Dr. Wilson

**INVOICE**

16069

**DATE**

05/11/26