



PATIENT

Bao Bao Hong

SPECIES

Feline

BREED

British Short Hair

SEX

Neutered Male

AGE

5 Years

WEIGHT

11

INTERPRETED BY

Eric Lindquist, DMV,
DABVP(CFM), Cert.
IVUSS

IMAGING PERFORMED BY

Dr. Shen Li

HOSPITAL NAME

Dr. Shen Li Veterinary
Service

REFERRING VET

Dr. Shen Li

INVOICE

16035

DATE

05/11/26

PRESENTING CLINICAL SIGNS

Two episodes of diarrhea past 3 months. Improving with proviable.

Abnormal PE/Chem/CBC/UA Results: Normal PE, recent BW normal. GI panel and dysbiosis index pending to tamu

ULTRASONOGRAPHIC EXAMINATION OF THE ABDOMEN

Urinary System

The **urinary bladder**, trigone, and pelvic urethra presented normal thicknesses and normal tone. The ureters were not visible which is normal. No uroliths or sediment were visualized, and a minimal amount of urine was present at the time of the sonogram. No evidence of inflammatory or neoplastic changes were noted. Ureteral papillae were normal.

The **kidneys** revealed normal size and structure, corticomedullary definition and ratio for this age. The cortices presented largely uniform texture with normal echogenic relationship to liver and spleen. Medullary structure differed distinctly from the cortex and no evidence of pelvic dilation was present. The capsules were acceptably uniform without significant irregularities. The left kidney measured 3.74 cm in length. The right kidney measured 4.13 cm in length.

Adrenal Glands

Both **adrenal glands** were not visualized.

Spleen

The **spleen** presented a smooth homogeneous parenchyma hyperechoic to liver and renal cortical parenchyma. The capsule was smooth without noticeable expansion or deviation from within the spleen or adjacent pathology. The splenic vasculature demonstrated normal volume without signs of congestion or thrombosis. No sonographic evidence of acute or chronic inflammatory, neoplastic, or infarctual changes were noted.

Liver

The **liver** images submitted revealed subjectively normal liver size, contour, and structure. Parenchymal echogenicity was naturally coarse and hypoechoic to the spleen. Vascular and biliary tracts were of normal volume with no evidence of congestion. The gallbladder presented acceptably thin walls with primarily anechoic content. The cystic and common bile ducts were normal. No pathological hepatic lymphadenopathy was evident. No overt structural evidence of inflammatory, infiltrative or regenerative pathology was evident.

Gastrointestinal

Examination of the **gastrointestinal tract** revealed a stomach and intestine free of stasis, of normal wall thickness, acceptable curvilinear mural detail, and peristaltic activity. Small and large intestine demonstrated normal luminal chyme and stool consistency respectively. No obstructive or overt infiltrative disease was noted. No associated abnormal lymphatic activity was noted. Transit of chyme into the small intestine appeared to be normal.

Pancreas



PATIENT

Bao Bao Hong

SPECIES

Feline

BREED

British Short Hair

SEX

Neutered Male

AGE

5 Years

WEIGHT

11

INTERPRETED BY

Eric Lindquist, DMV,
DABVP(CFM), Cert.
IVUSS

IMAGING PERFORMED BY

Dr. Shen Li

HOSPITAL NAME

Dr. Shen Li Veterinary
Service

REFERRING VET

Dr. Shen Li

INVOICE

16035

DATE

05/11/26

The base and limbs of the **pancreas** were observed to be largely isoechoic to surrounding omental fat. Pancreatic duct and capsular contour were acceptably normal and parenchyma respected normal curvilinear patterns. No overt evidence of active inflammatory or neoplastic disease was noted.

Free Abdomen

The mesenteric **lymph node** presented normal length to width ratio with slight, swollen contour. There was no loss of parenchymal detail. This is most consistent with reactive lymphadenitis or lymphatic hyperplasia. The lymph node measured 0.46 cm.

ULTRASONOGRAPHIC FINDINGS

- Structurally unremarkable abdomen- no evidence of pathology.
- Mesenteric lymph node.

INTERPRETATION OF THE FINDINGS & FURTHER RECOMMENDATIONS

Differentials for diarrhea include occult parasitism, dietary indiscretion, dietary intolerance, antibiotic responsive colitis, intestinal dysbiosis should all be considered as causes of diarrhea in this patient. A hydrolyzed diet trial may be in this patient's best interest +/- probiotics. 8-12-hour NPO and reintroduction of bland diet indicated. I recommend a fresh fecal smear and fecal floatation analysis if not already performed. Note that recent research has shown that indiscriminate use of antibiotics may actually cause harm. Most acute cases of diarrhea will respond to probiotic therapy, fiber, and gastrointestinal diets over the next 3-5 days. Low dose Prednisolone trial may be necessary in some cases. However, this may be problematic if an occult, non-evident round cell neoplasia or similar is developing.



PATIENT

Bao Bao Hong

SPECIES

Feline

BREED

British Short Hair

SEX

Neutered Male

AGE

5 Years

WEIGHT

11

INTERPRETED BY

Eric Lindquist, DMV,
DABVP(CFM), Cert.
IVUSS

**IMAGING
PERFORMED BY**

Dr. Shen Li

HOSPITAL NAME

Dr. Shen Li Veterinary
Service

REFERRING VET

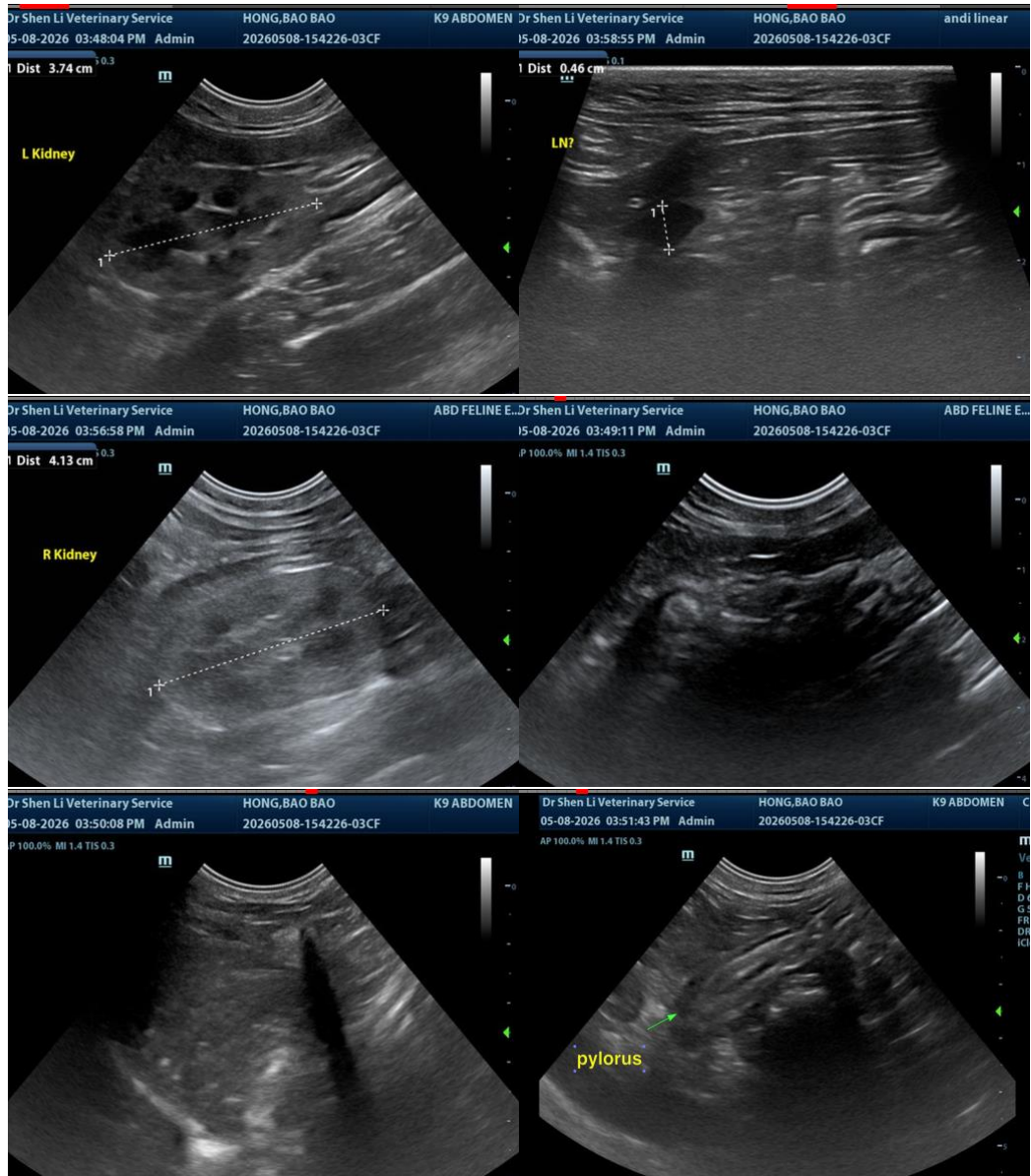
Dr. Shen Li

INVOICE

16035

DATE

05/11/26



The information and recommendations provided are based on the images presented by the referring veterinarian/sonographer. No evaluation can be communicated regarding pathology that was not visible in the image/video clips provided.

Thank you for this referral. If the clinical or image interpretation does not parallel your findings or if I can be of any further assistance, please contact me.

Eric Lindquist, DMV, DABVP(CFM), Cert. IVUSS,

CEO, Owner, Founder -- SonoPath.com

info@SonoPath.com



PATIENT

Bao Bao Hong

SPECIES

Feline

BREED

British Short Hair

SEX

Neutered Male

AGE

5 Years

WEIGHT

11

INTERPRETED BY

Eric Lindquist, DMV,
DABVP(CFM), Cert.
IVUSS

IMAGING PERFORMED BY

Dr. Shen Li

HOSPITAL NAME

Dr. Shen Li Veterinary
Service

REFERRING VET

Dr. Shen Li

INVOICE

16035

DATE

05/11/26